Carcinogenesis of gastric cancer through the eyes of a pathologist

Fátima Carneiro
Ipatimup
Medical Faculty/Centro Hospitalar São João
Porto, Portugal

Early diagnosis

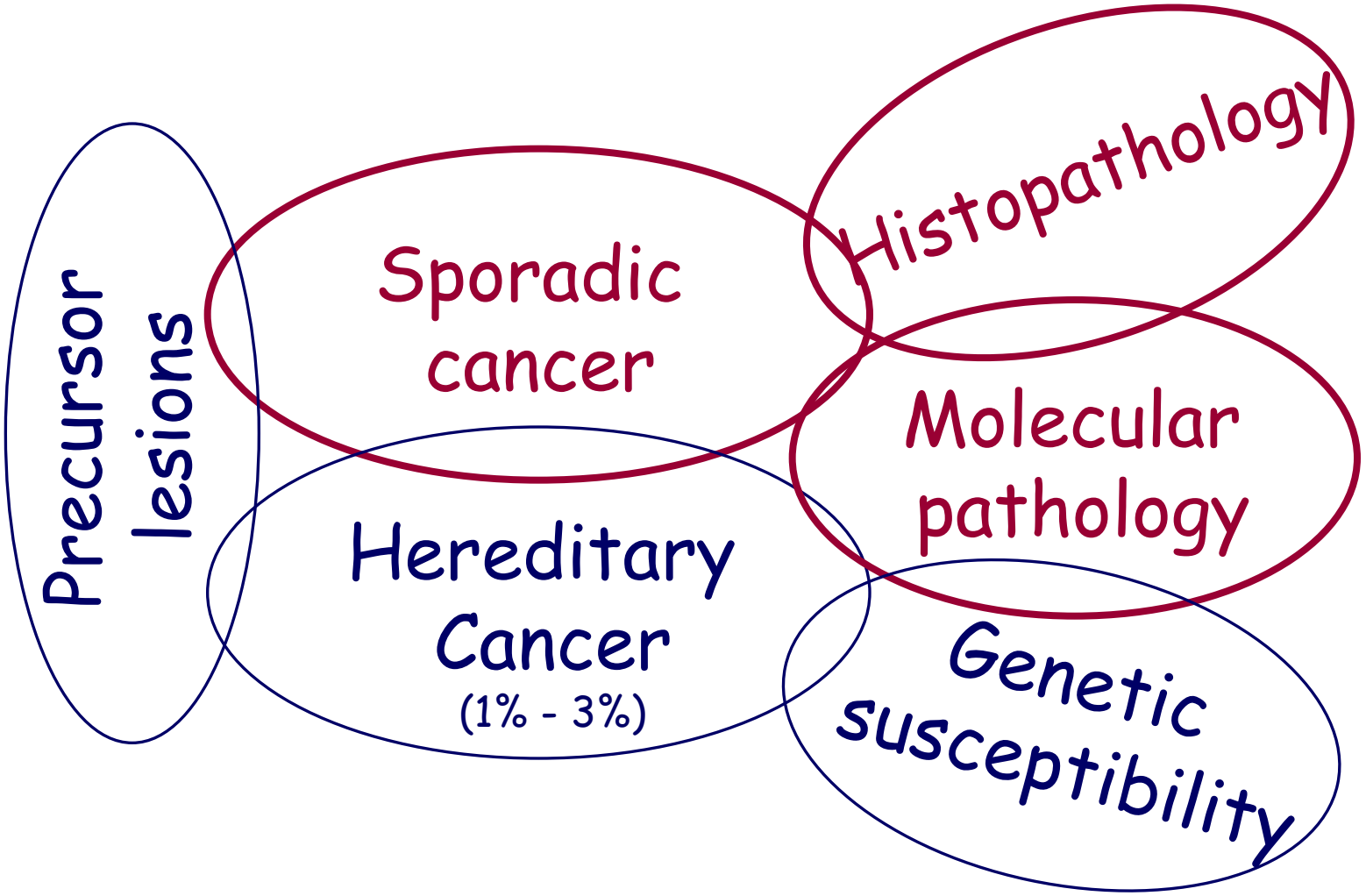

1. Gastric carcinogenesis (*H. pylori* & the other gastric microbiota)
2. Morphological and molecular features
3. Hereditary gastric carcer
4. A tentative, global picture

1. Gastric carcinogenesis (*H. pylori* & the other gastric microbiota)
2. Morphological and molecular features
3. Hereditary gastric carcinoma
4. A tentative global picture

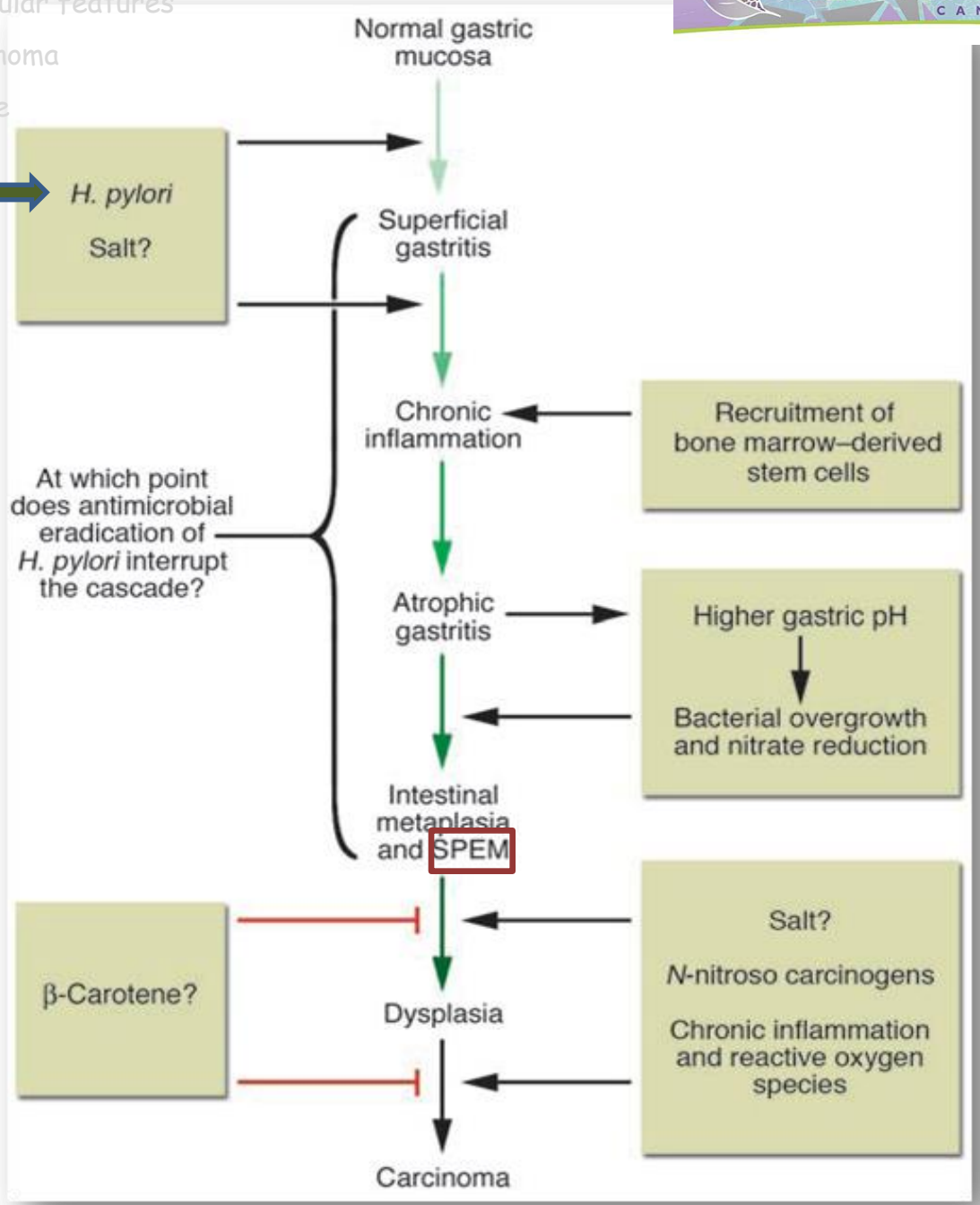

H. pylori negative

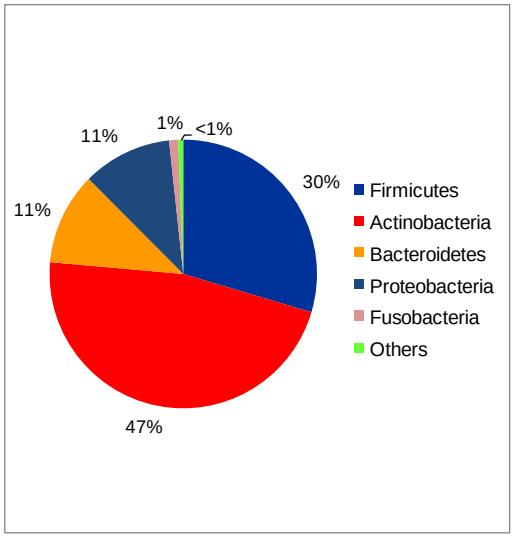

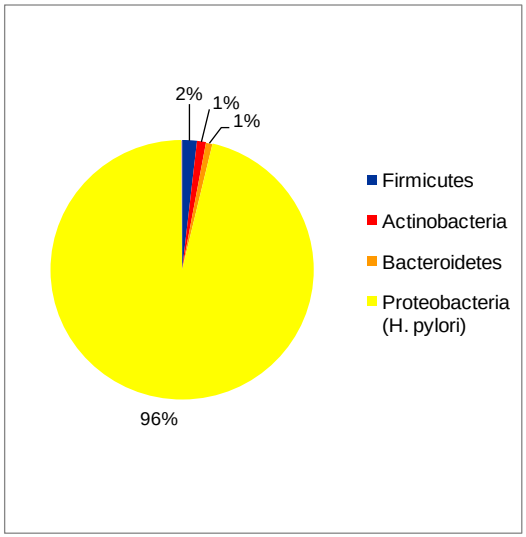

H. pylori positive

European *Helicobacter* Study Group

⇩

European *Helicobacter* and Microbiota Study group (2015)

Helicobacter ISSN 1523-5378
doi: 10.1111/hel.12145

Differences in Gastric Mucosal Microbiota Profiling in Patients with Chronic Gastritis, Intestinal Metaplasia, and Gastric Cancer Using Pyrosequencing Methods

Chang Soo Eun,*,[1] Byung Kwon Kim,†,[1] Dong Soo Han,* Seon Young Kim,‡ Kyung Mo Kim,§ Bo Youl Choi,¶ Kyu Sang Song,** Yong Sung Kim‡ and Jihyun F. Kim‡‡

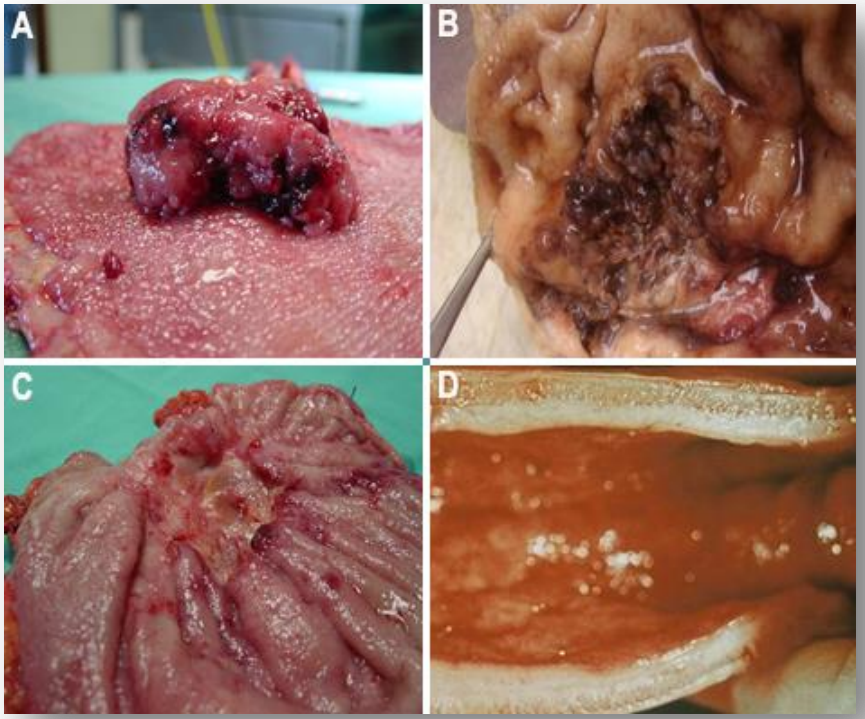
A
B
C
D

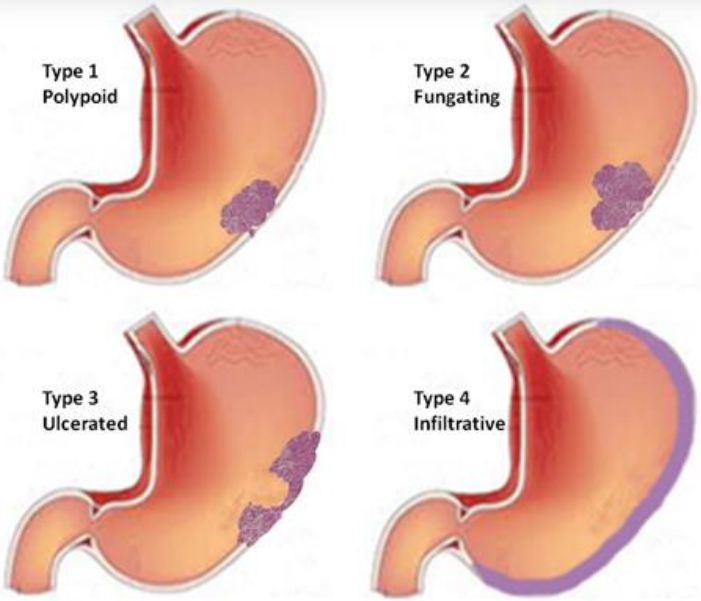
Type 1
Polypoid
Type 2
Fungating
Type 3
Ulcerated
Type 4
Infiltrative

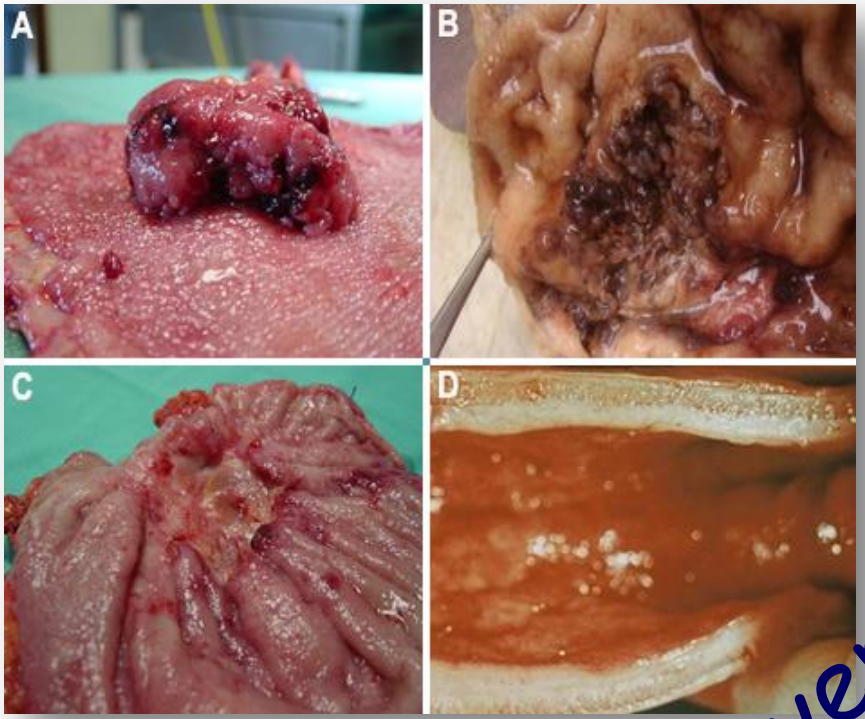

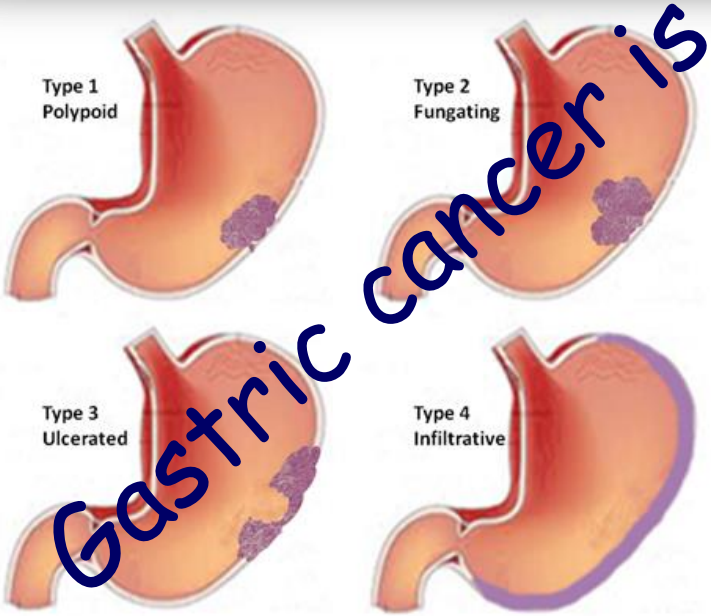

Gastric cancer is very heterogeneous

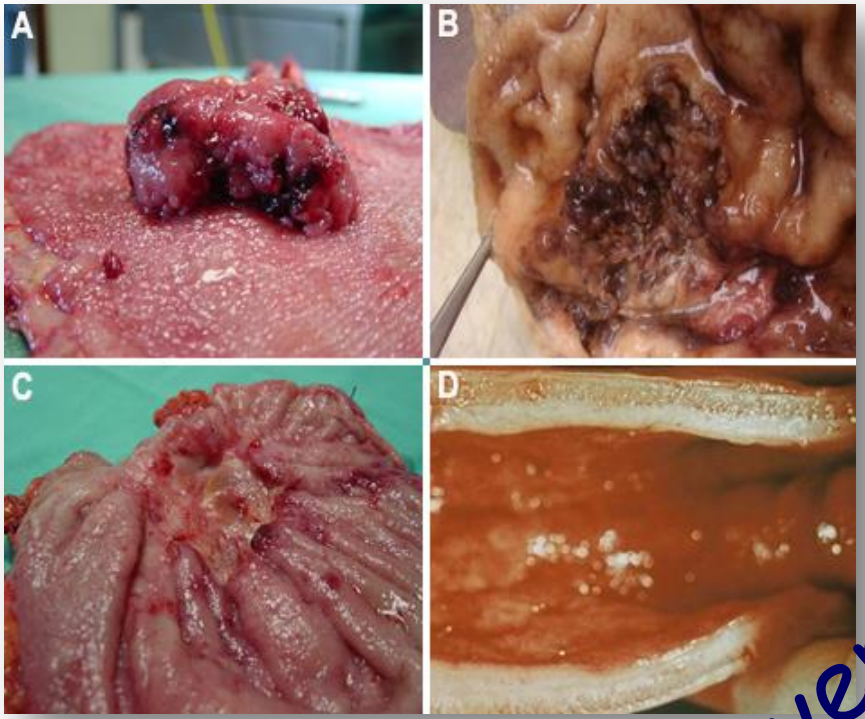

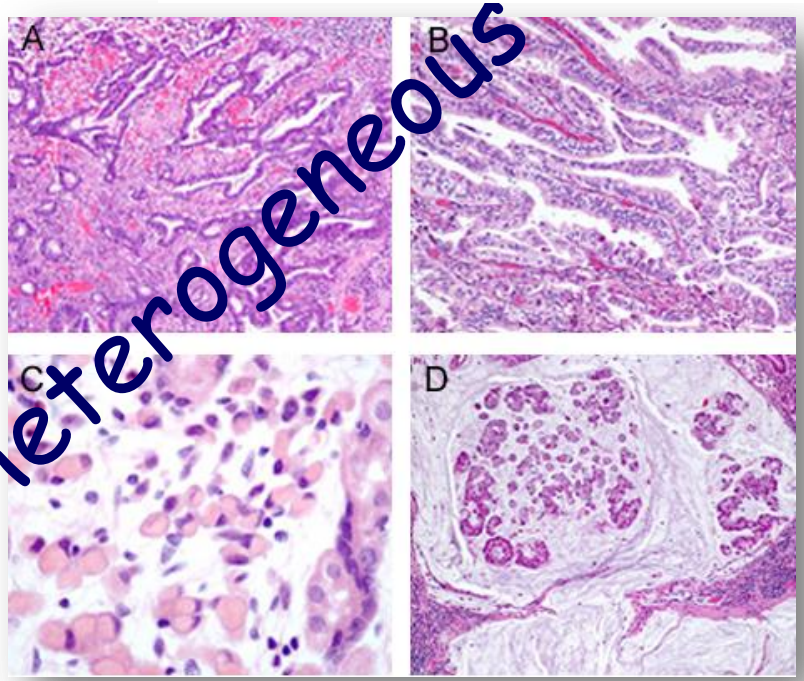

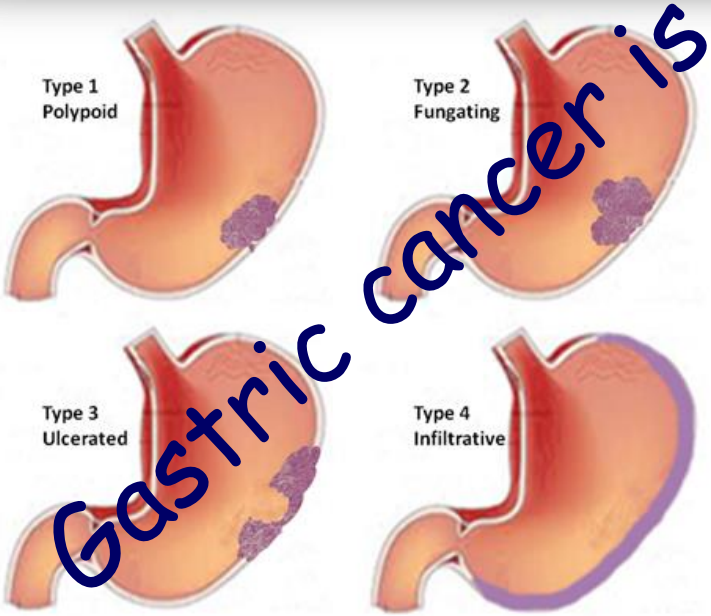

Gastric cancer is very heterogeneous

Gastric cancer is very heterogeneous

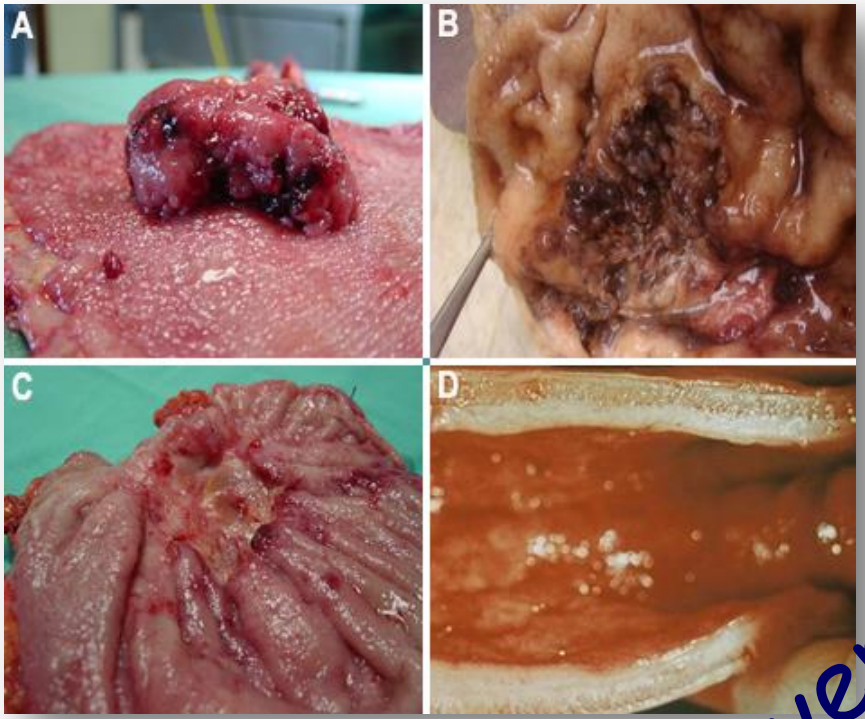

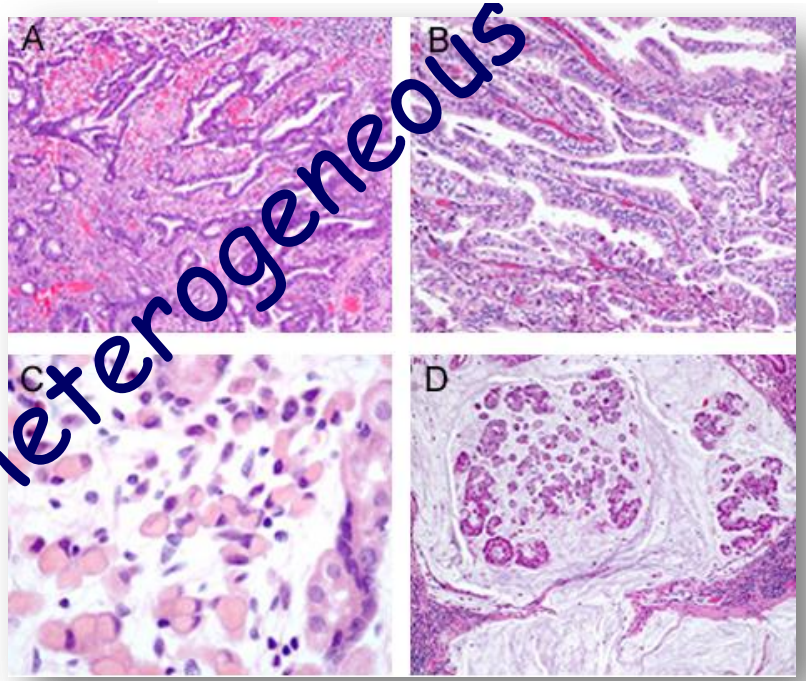

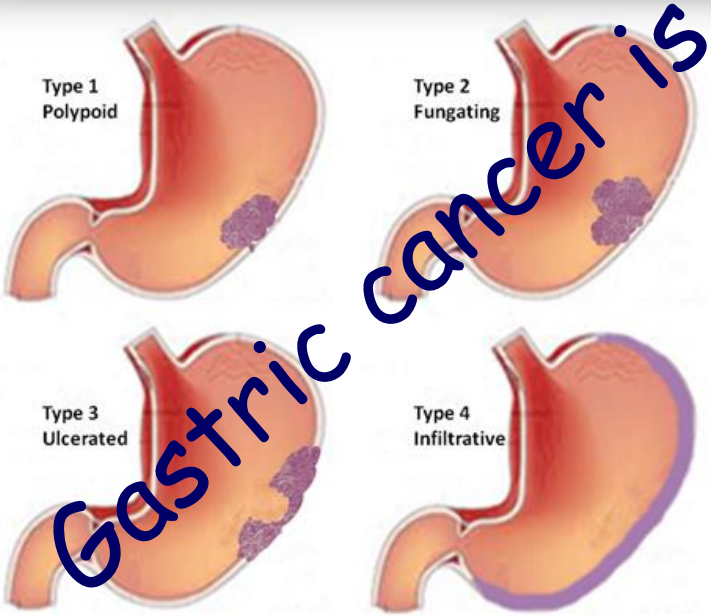

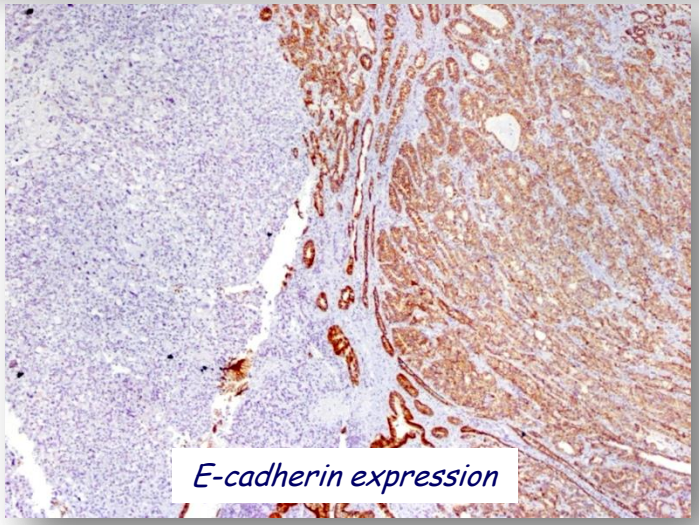

ESMO 18TH WORLD CONGRESS ON Gastrointestinal CANCER
29 JUNE – 2 JULY 2016
BARCELONA, SPAIN

4-1 Gastric carcinoma

Gregory Y. Lauwers
Fátima Carneiro
David Y. Graham
Maria-Paula Curado
Silvia Franceschi
Elizabeth Montgomery
Masae Tatematsu
Takenori Hattori

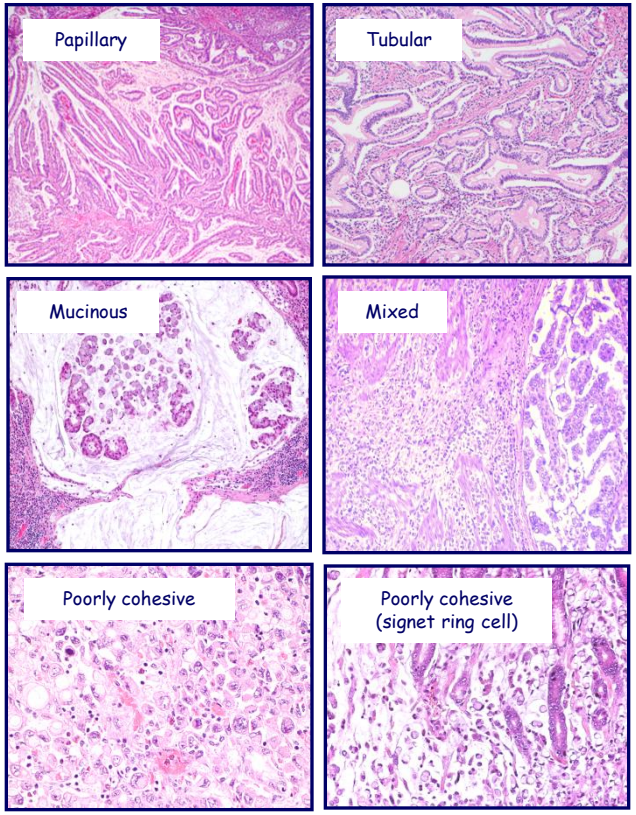

WHO - 4th Edition, 2010

4-1-02 - ICD-O Code	
Adenocarcinoma	8140/3
Papillary adenocarcinoma	8260/3
Tubular adenocarcinoma	8211/3
Mucinous adenocarcinoma	8480/3
Poorly cohesive carcinoma	8490/3
(Signet-ring cell carcinoma and other variants)	
Mixed carcinoma	8255/3

Tubulo-papillary ca. (WHO)
"Intestinal" carcinoma (Lauren)

- Elderly patients, mainly males
- Decreasing incidence everywhere
- Blood-born metastases

Poorly cohesive/signet ring ca. (WHO)
"Diffuse" carcinoma (Lauren)

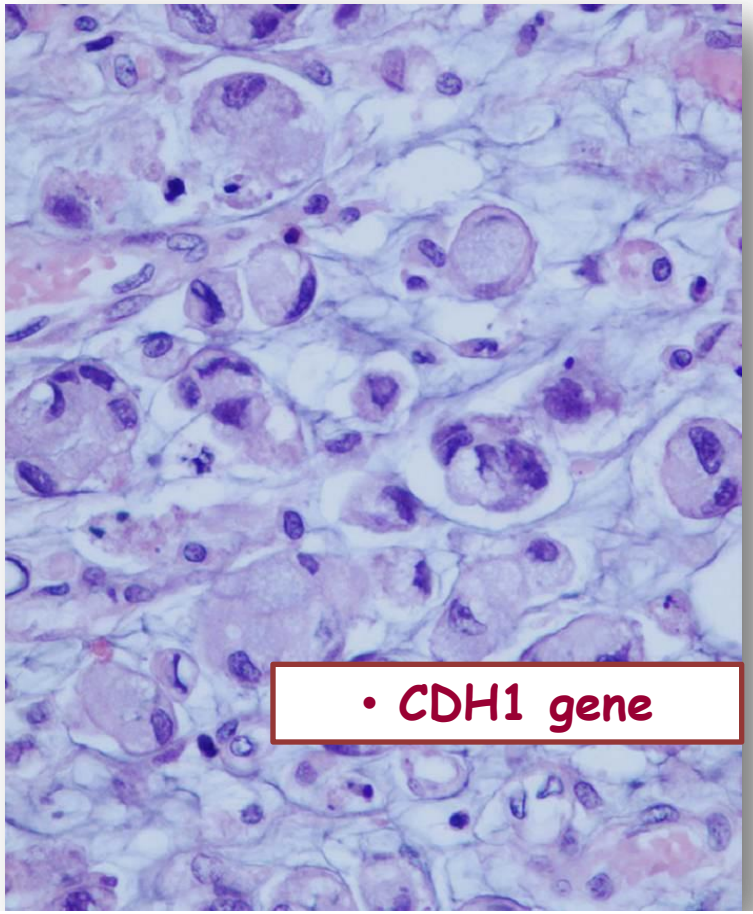

- Young patients, mainly females
- Familial/hereditary conditioning
- Dissemination to the peritoneum

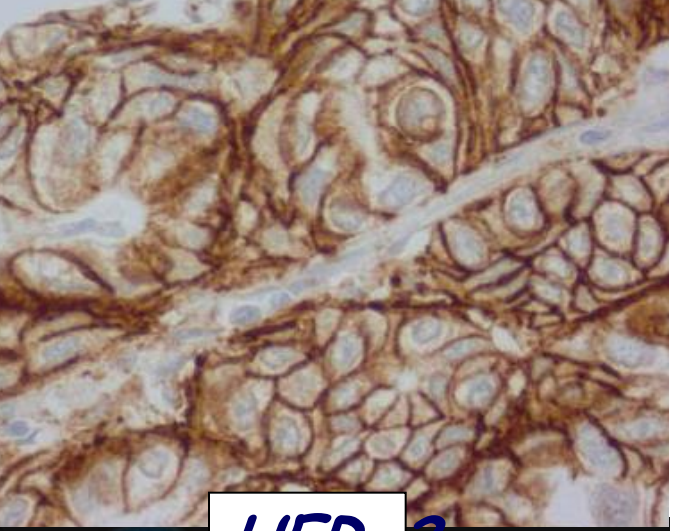

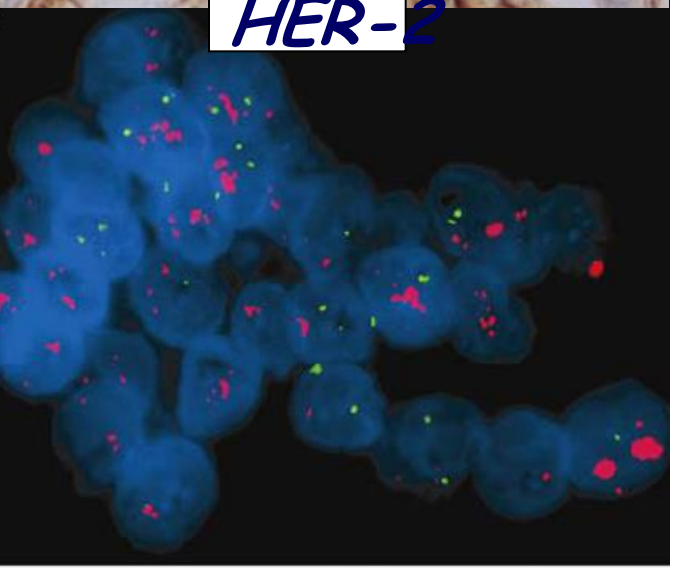

HER-2 in gastric carcinoma

Prognostic factor <

YES (56%)

NO (44%)

HER-2 amplification in intestinal-type gastric carcinoma

⇩

Blood born metastases
Poor prognosis

David L *et al*; Mod Pathol 5:384, 1992
Barros-Silva J *et al*; Br J Cancer 100: 487,2009

ToGA Trial

HER-2 overexpression in 22% of advanced gastric cancers; improved survival in patients treated with with trastuzumab

ASCO 2009 (LBA 4509)

ESMO 18TH WORLD CONGRESS ON Gastrointestinal CANCER
29 JUNE – 2 JULY 2016
BARCELONA, SPAIN

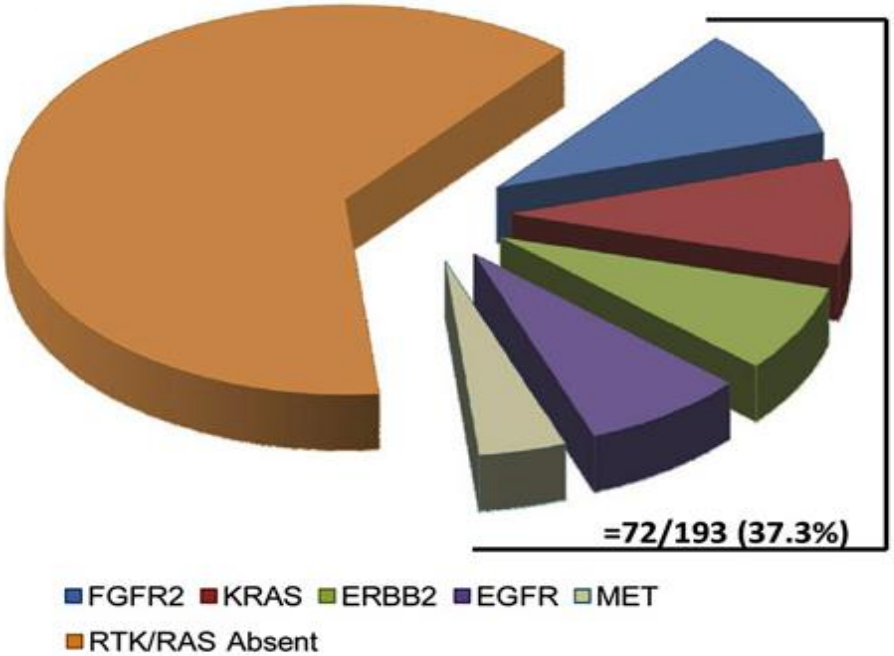

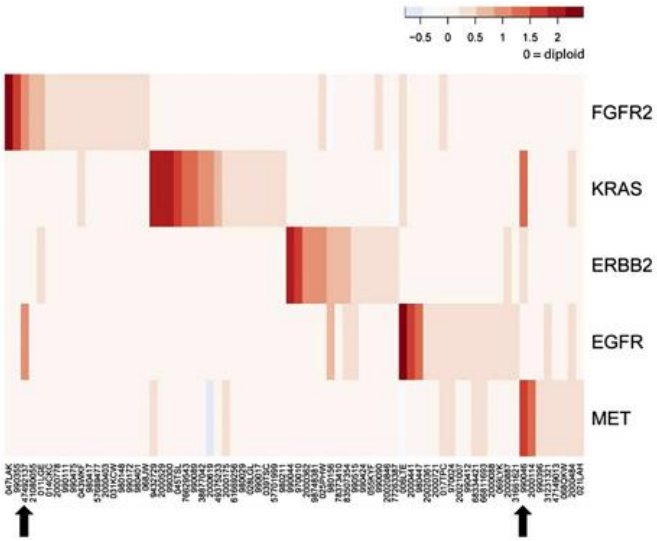

New findings?

- Genes related to RTK/RAS signaling (FGFR2, KRAS, HER2, EGFR and MET) are frequently amplified in gastric carcinoma in a mutually exclusive manner.

Deng N et al, Gut 61:673, 2012

MSI in gastric carcinoma

Survival of patients
Univariate analysis

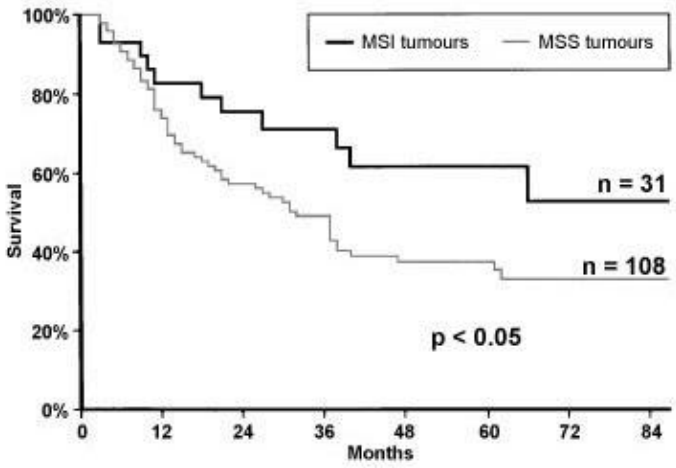

MSI is a molecular marker of good prognosis in sporadic gastric cancer
(caused by *hMLH1* promoter hypermethylation)

Multivariate analysis
- Staging (pTNM) (p< 0.0008)
- Venous invasion (p= 0.004)
- Histological classification (p=0.08)
- Microsatellite instability (p=0.04)



Seruca R *et al.* Int J Cancer 64: 32, 1995
Santos N *et al.* Gastroenterology 110: 38, 1996
Oliveira C *et al.* Am J Pathol 153: 1211, 1998

The dawn of phenotypic classification

Gastric adenocarcinoma

Gastric dysplasia

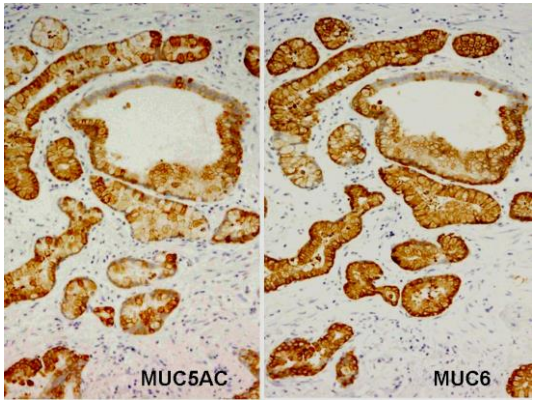

Gastric type

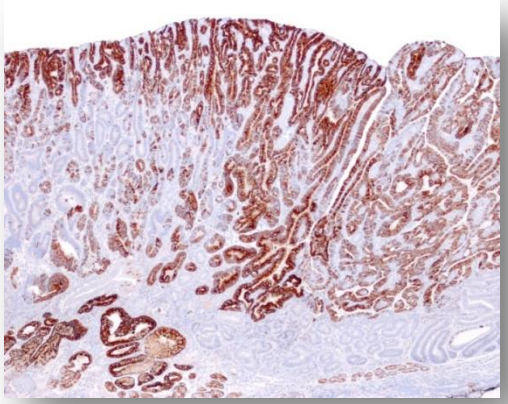

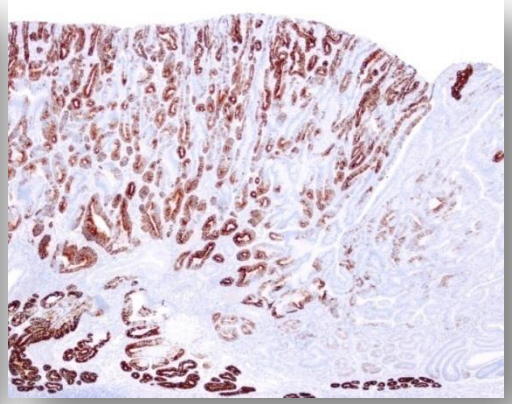

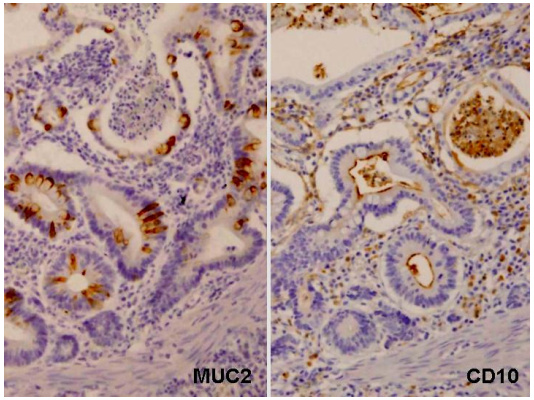

Intestinal type

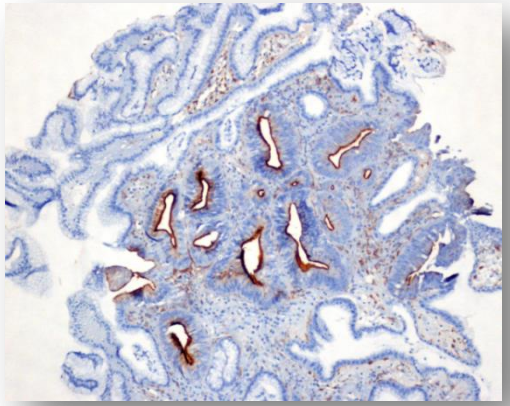

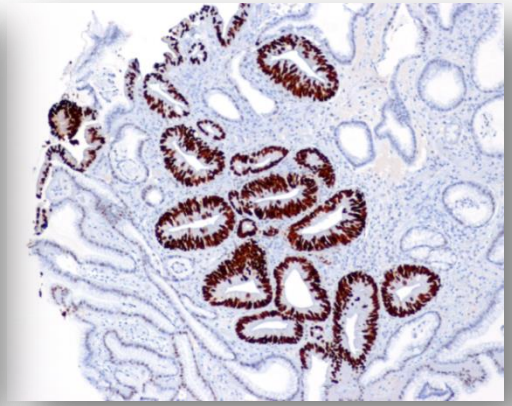

Nogueira AM *et al*. J Pathol 187: 541, 1999
Nogueira AM *et al*. Cancer 86: 1649-1656, 1999
Endoh *et al.* J Pathol 191: 257, 2000
Kushima R et al: Gastric Cancer 9:177, 2006.

Valente P et al; Gastric Cancer 18:720, 2015

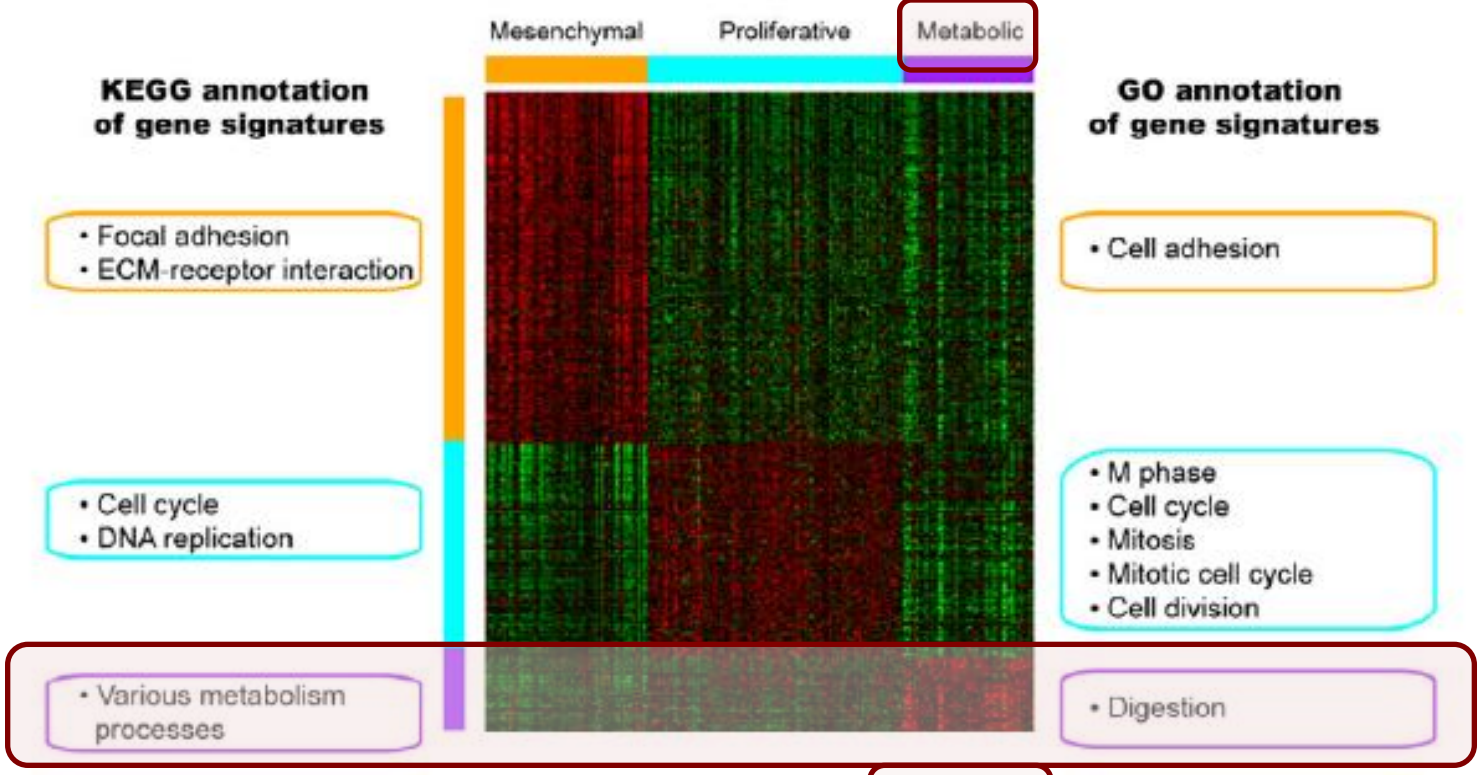

CHC (Consensus hierarchical Clustering) & IFS (Iterative feature Selection)

	Mesenchymal	Proliferative	Metabolic
Lauren's classification	Diffuse (58.2%)	Intestinal (73.6 %)	Intestinal (53.6 %) Diffuse (40.6%)
Copy number alt. (CNA)	Low CNA	High CNA	
Methylation	Hyper methylation	Hypo methylation	
TP53 mutations	Low	High	Low
Pathway activation	EMT, TGF-β, VEGF, NFκB, mTOR, CSC	E2F, MYC, RAS	SPEM - (TFF2 expressing metaplasia)

Sensitive to mTOR inhibitors

Sensitive to 5-FU

Gastric differentiation

Lei Z *et al.* Gastroenterology 2013

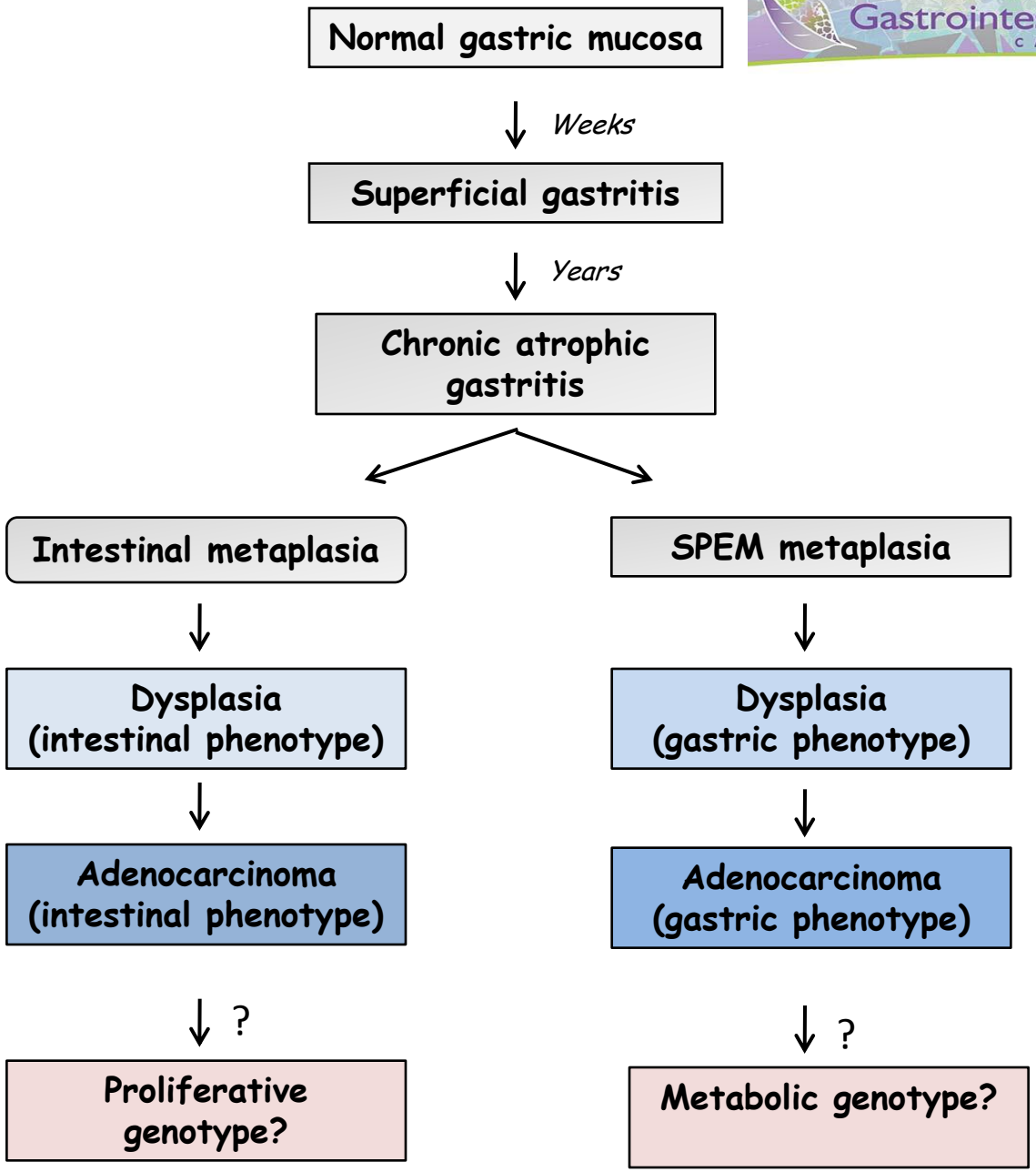
Normal gastric mucosa
Weeks
Superficial gastritis
Years
Chronic atrophic gastritis
Intestinal metaplasia
SPEM metaplasia
Dysplasia (intestinal phenotype)
Dysplasia (gastric phenotype)
Adenocarcinoma (intestinal phenotype)
Adenocarcinoma (gastric phenotype)
?
?
Proliferative genotype?
Metabolic genotype?

ARTICLE

OPEN
doi:10.1038/nature13480

Comprehensive molecular characterization of gastric adenocarcinoma

The Cancer Genome Atlas Research Network*

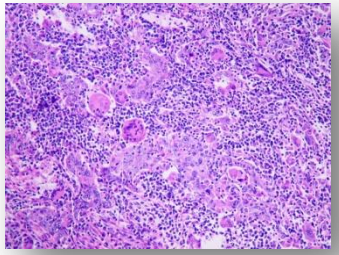

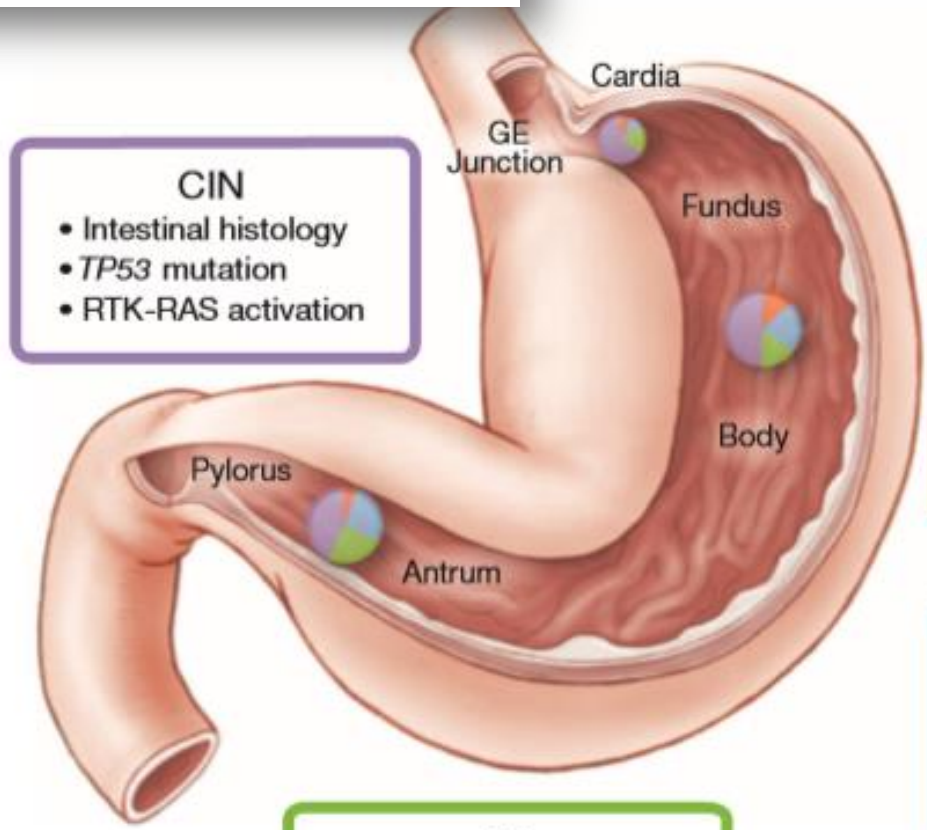

CIN
- Intestinal histology
- *TP53* mutation
- RTK-RAS activation

EBV
- *PIK3CA* mutation
- *PD-L1/2* overexpression
- EBV-CIMP
- *CDKN2A* silencing
- Immune cell signalling

MSI
- Hypermutation
- Gastric-CIMP
- *MLH1* silencing
- Mitotic pathways

GS
- Diffuse histology
- *CDH1, RHOA* mutations
- *CLDN18–ARHGAP* fusion
- Cell adhesion

The Cancer Genome Atlas (TCGA) project; Nature 2014

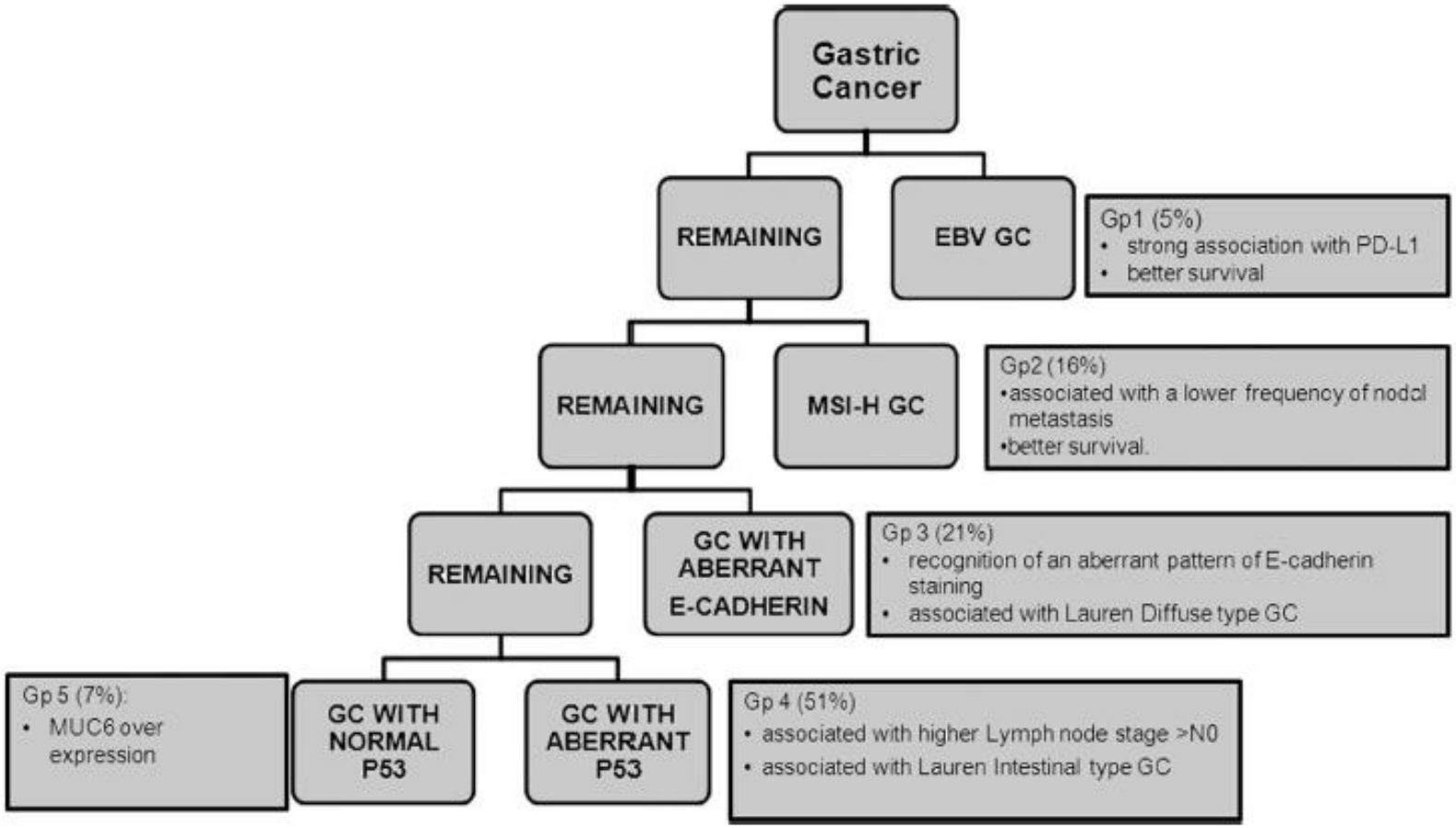

Setia M et al: Modern Pathology 2016

Genetics and Molecular Pathogenesis of Gastric Adenocarcinoma



Patrick Tan[1,2,3,4,7] Khay-Guan Yeoh[5,6,7]

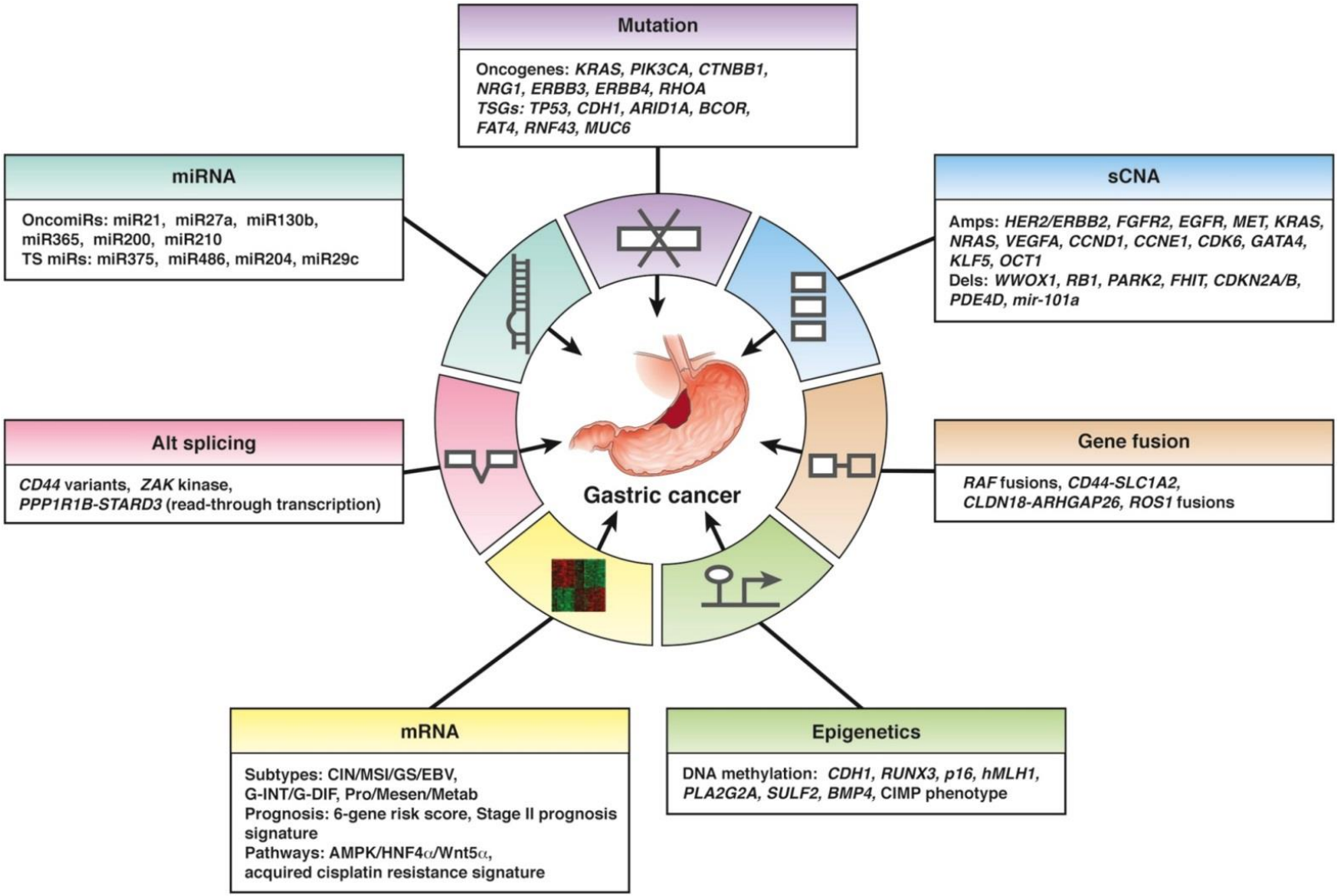

Curr Oncol Rep (2016) 18:41
DOI 10.1007/s11912-016-0525-x

TRANSLATIONAL ONCOLOGY (L VECCHIONE, SECTION EDITOR)

Personalised Treatment in Gastric Cancer: Myth or Reality?

Noelia Tarazona[1,2] • Valentina Gambardella[1,3] • Marisol Huerta[1] •
Susana Roselló[1] • Andrés Cervantes[1]

The absence of predictive biomarkers is making difficult the application of personalised or precision medicine to GC patients.

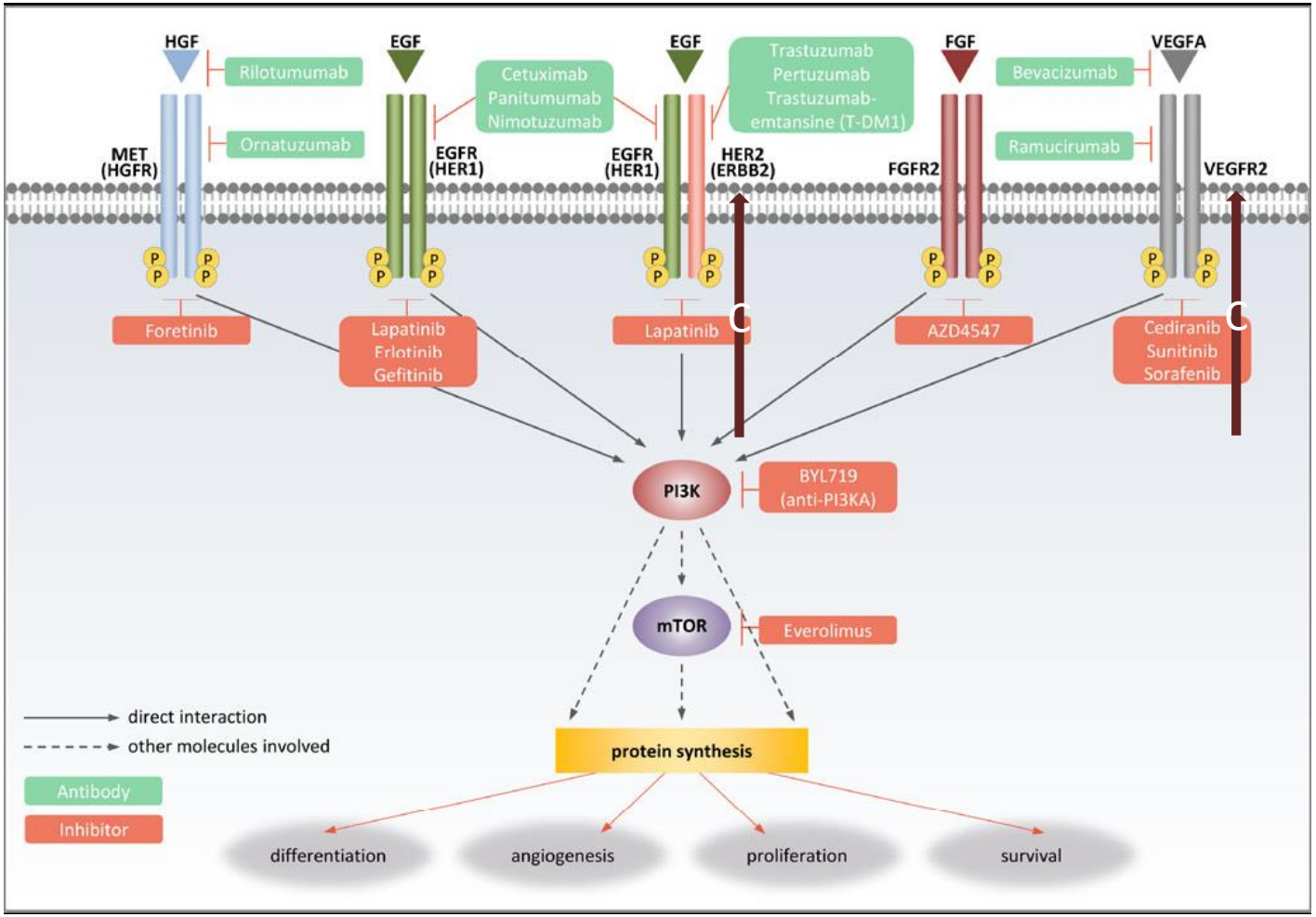
HGF
Rilotumumab
Ornatuzumab
MET (HGFR)
EGF
Cetuximab
Panitumumab
Nimotuzumab
EGFR (HER1)
EGF
Trastuzumab
Pertuzumab
Trastuzumab-emtansine (T-DM1)
EGFR (HER1)
HER2 (ERBB2)
FGF
Bevacizumab
Ramucirumab
FGFR2
VEGFA
VEGFR2
P
Foretinib
Lapatinib
Erlotinib
Gefitinib
Lapatinib
C
AZD4547
Cediranib
Sunitinib
Sorafenib
C
PI3K
BYL719 (anti-PI3KA)
mTOR
Everolimus
direct interaction
other molecules involved
Antibody
Inhibitor
protein synthesis
differentiation
angiogenesis
proliferation
survival

PD-L1 in gastric cancer

- EBV
- MSI

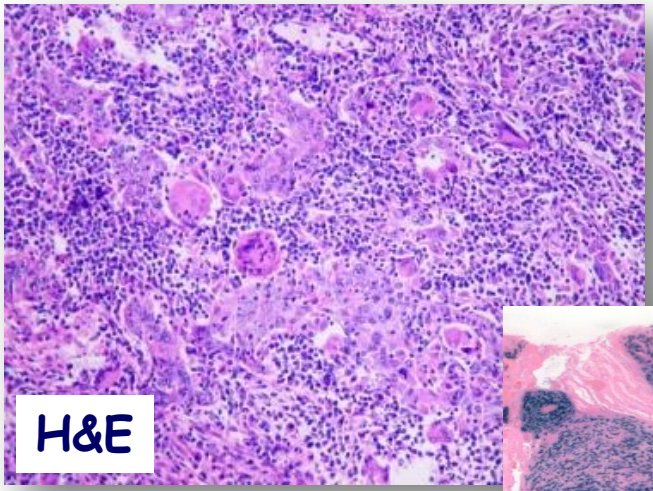

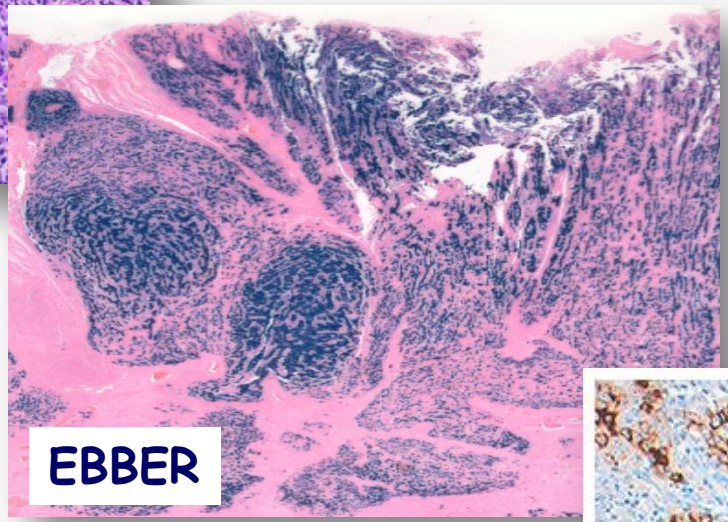

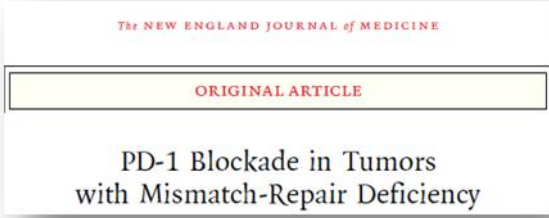
The NEW ENGLAND JOURNAL of MEDICINE

ORIGINAL ARTICLE

PD-1 Blockade in Tumors with Mismatch-Repair Deficiency

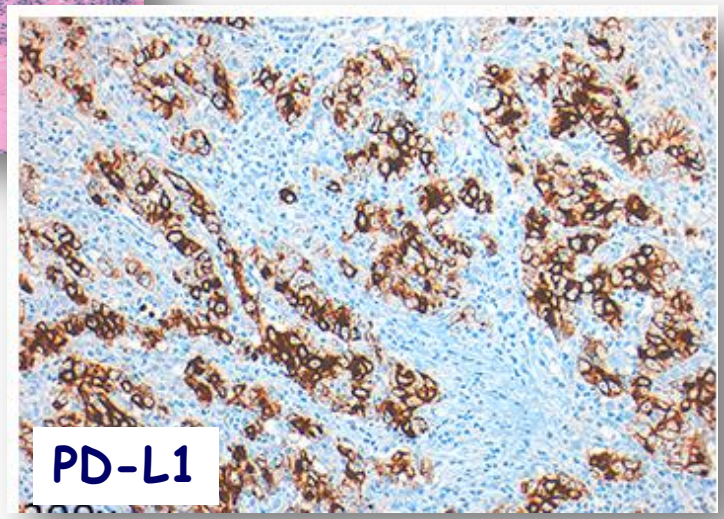

Gullo I, Carneiro F, 2016

New perspectives in immuno-oncology

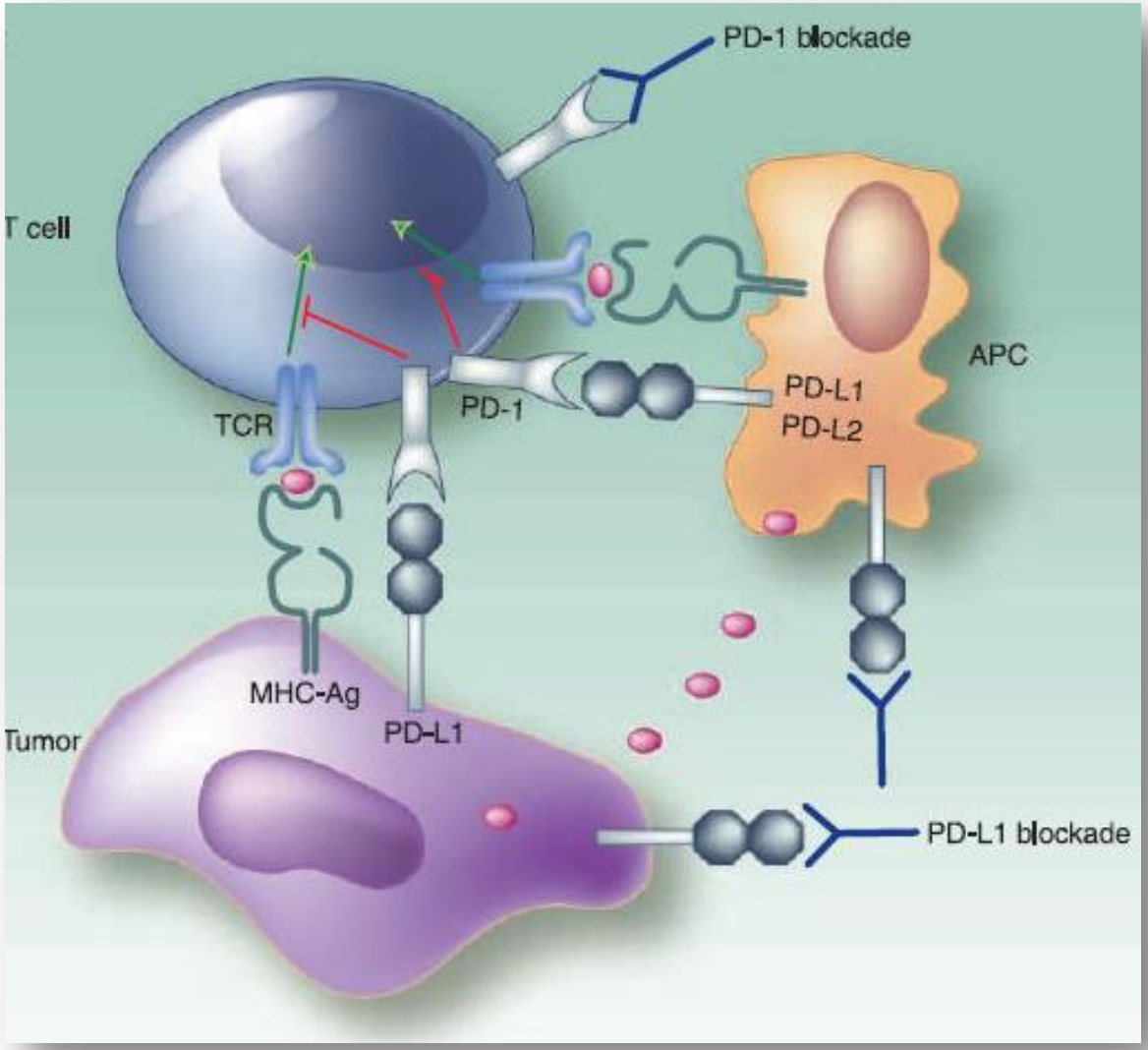

EBV+ and MSI GC may have greater likelihood of response to PD-1 blockade

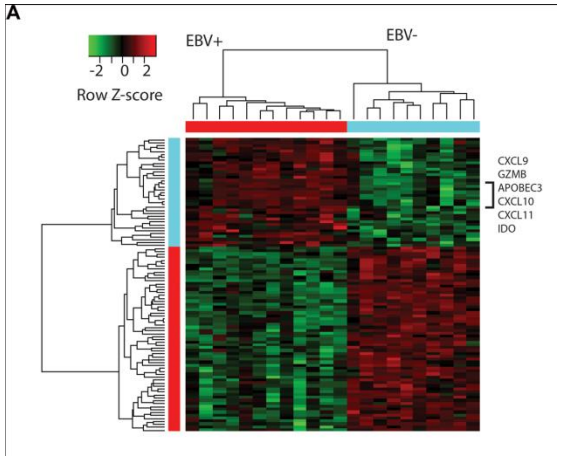

Derks et al; Oncotarget 2016
10.18632/oncotarget.9076

ESMO 18TH WORLD CONGRESS ON Gastrointestinal CANCER
29 JUNE – 2 JULY 2016
BARCELONA, SPAIN

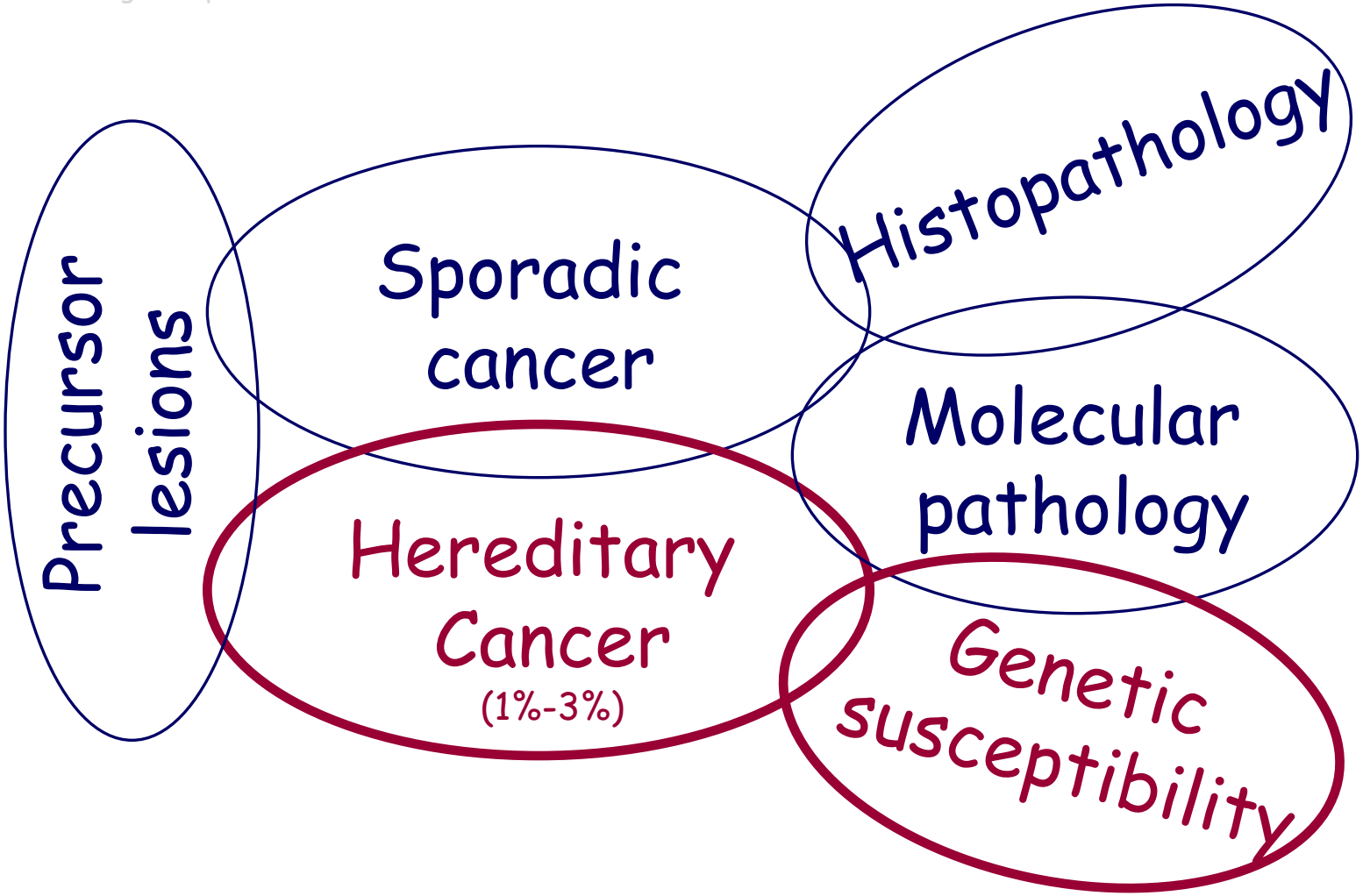

New Chapter on:

4-3 Hereditary Diffuse Gastric Cancer

Fátima Carneiro
Amanda Charlton
David Huntsman

ESMO 18th World Congress on Gastrointestinal Cancer
29 JUNE – 2 JULY 2016
BARCELONA, SPAIN

Definition

Hereditary diffuse gastric cancer (HDGC) is an autosomal-dominant cancer-susceptibility syndrome that is characterized by signet-ring cell (diffuse) gastric cancer and lobular breast cancer. The genetic basis for this syndrome was discovered in 1999 by Guilford *et al.* {1081}, who identified germline mutations of the E-cadherin (*CDH1*) gene (MIM No. 192090) by linkage analysis and mutation screening in three Maori kindreds with multigenerational, diffuse gastric cancer in New Zealand.

MIM No.: 137215

Diagnostic criteria

In families with an aggregation of gastric cancer, the histopathology of the tumours is often unknown; these cases are designated as familial gastric cancer (FGC). When the histopathological type of one or more gastric cancers is known, discrete syndromes/diseases can be diagnosed; these include HDGC, familial diffuse gastric cancer (FDGC) and familial intestinal gastric cancer (FIGC) {397}.

On the basis of clinical criteria, the International Gastric Cancer Linkage Consortium (IGCLC) in 1999 defined families with the HDGC syndrome as those fulfilling one of the following features:

(1) two or more documented cases of diffuse gastric cancer in first- or second-degree relatives, with at least one being diagnosed before the age of 50 years; or (2) three or more cases of documented diffuse gastric cancer in first- or second-degree relatives, independent of age of diagnosis {397}. Women in these families also have an elevated risk of lobular breast cancer {341, 1501, 1513, 2855, 3136}. IGCLC criteria for genetic testing, updated in 2009 {871} are shown in Table 4.2.01. An alternative genetically-based nomenclature, proposed by the New Zealand group, in which the term "HDGC" is restricted to families with germline mutations in the *CDH1* gene {1091, 1092}. The IGCLC definition for HDGC will be used for the remainder of this section {871}.

Epidemiology

The vast majority of gastric cancers are sporadic, but approximately 1–3% result from an inherited predisposition {870, 2396, 2439}.

The prevalence of HDGC is uncertain, partly due to the recent identification of this syndrome. In a review of 439 families with aggregation of gastric cancer {2395}, *CDH1* mutations were preferentially observed in families fulfilling the clinical criteria for HDGC (36.4%). In FDGC, the frequency of germline mutations in *CDH1* was much lower (12.5%) {2395}. *CDH1* mutations have not been found in families with weaker histories of gastric cancer; however, mutation rates of up to 10% have been described in individuals with no family history but DGC diagnosed at less than age 35 years, from populations with a low incidence of gastric cancer {1501, 3136}. There are striking population-specific differences regarding the fraction of families with aggregation of gastric cancer and frequency of *CDH1* germline mutations. In countries with a low incidence of gastric cancer, the frequency of germline alterations in the *CDH1* gene is > 40%, while in countries with a moderate or high incidence of gastric cancer, the frequency of alterations in *CDH1* is about 20% {2396}. These observations in moderate- or high-incidence countries are probably related to clustering of gastric cancer attributable to environmental risk factors (lifestyle, diet) and/or variation in genes conferring a weak susceptibility {2396}.

Localization

Most index cases with HDGC present with cancers that are indistinguishable from sporadic diffuse gastric cancer, often with linitis plastica, which can involve all topographic regions within the stomach. Systematic complete mapping of total gastrectomies from asymptomatic carriers

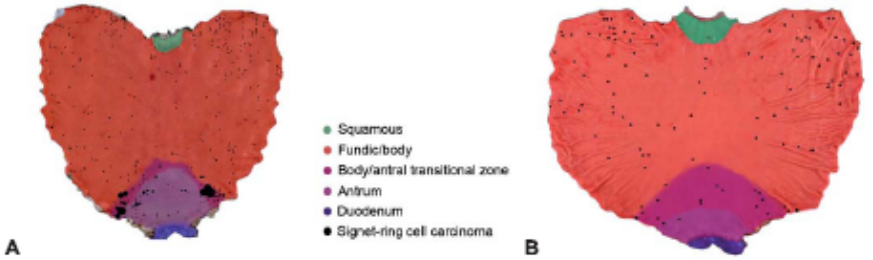

Fig. 4.2.01 Mapping of gastric mucosal zones (semi-opaque colours) and location of foci of stage T1a signet-ring cell (diffuse) carcinoma (black circles) on photos of two stomachs. Adapted from Charlton *et al.* (493). A Asymptomatic *CDH1*-mutation carrier, aged 15 years; the map indicates the location of 318 foci and mucosal zones. B Asymptomatic *CDH1*-mutation carrier, aged 19 years, from the same family; the map indicates the location of 115 foci and mucosal zones.



WHO – 4th Edition, 2010

Familial gastric cancer: genetic susceptibility, pathology, and implications for management

Carla Oliveira*, Hugo Pinheiro*, Joana Figueiredo, Raquel Seruca, Fátima Carneiro

Intramucosal signet ring cell carcinoma

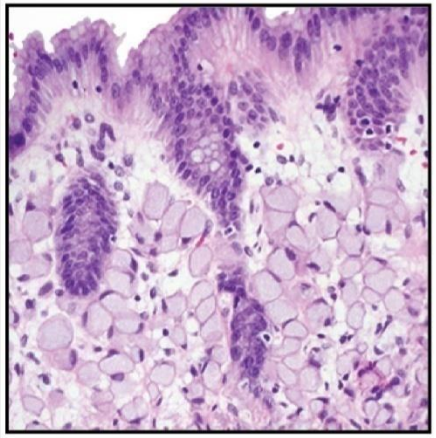

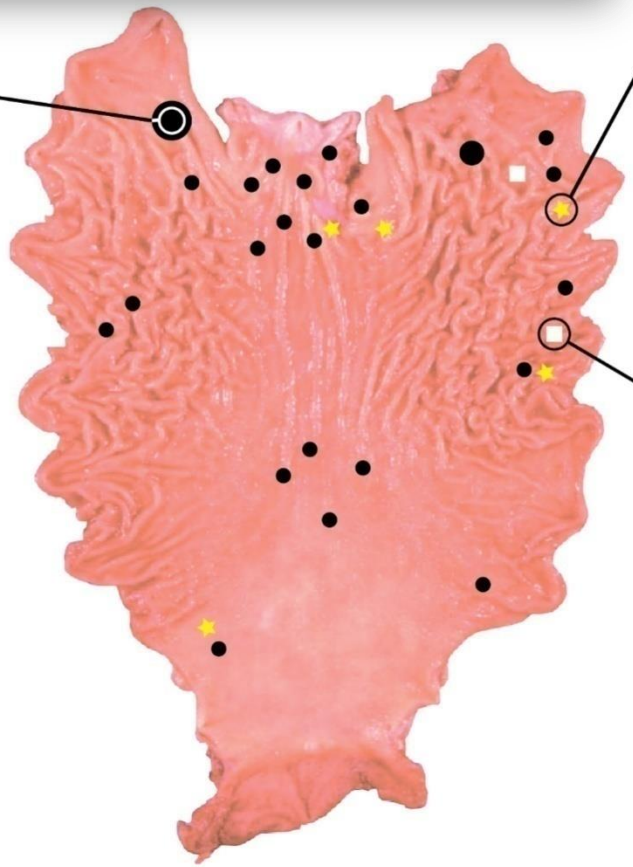

Pagetoid spread of signet ring cells

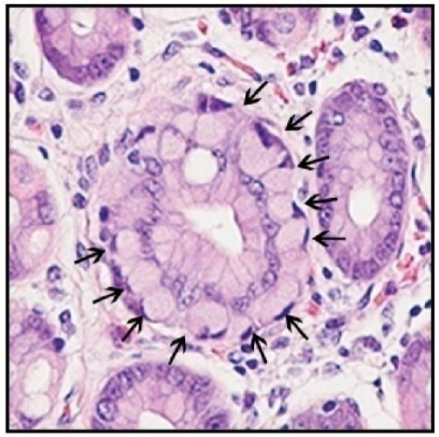

In situ carcinoma

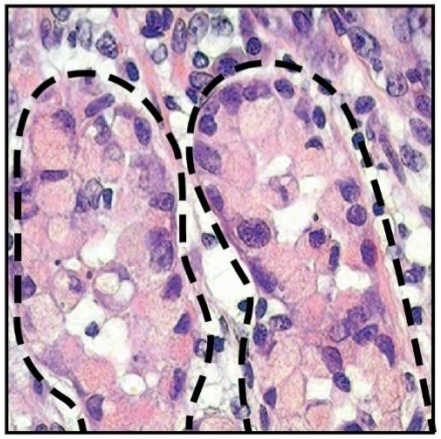

Oliveira et al; Lancet Oncology www.thelancet.com/oncology Vol 16 February 2015

Indolent carcinoma

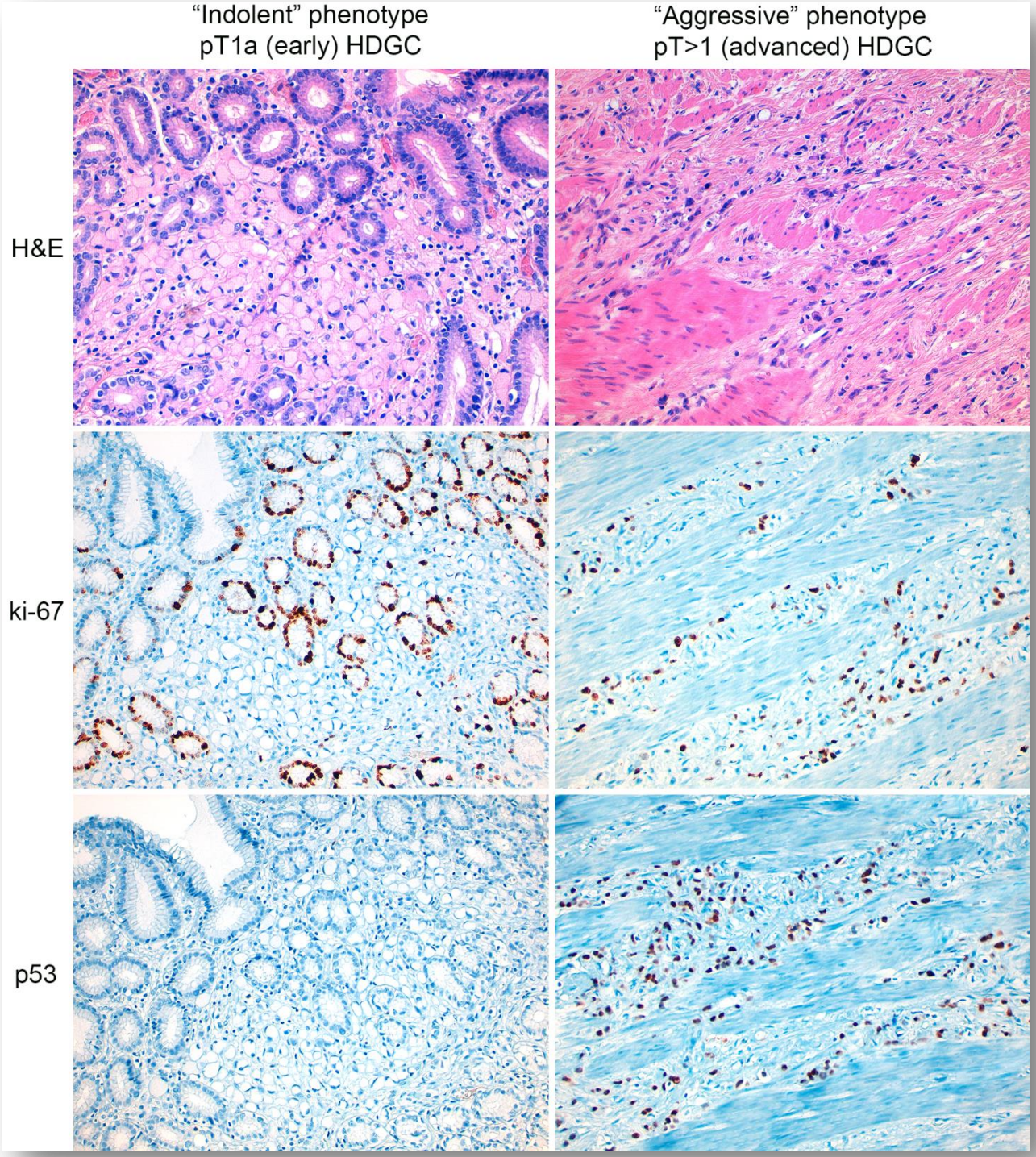

Aggressive pattern

Gullo I, 2015

HEREDITARY – Germline mutations

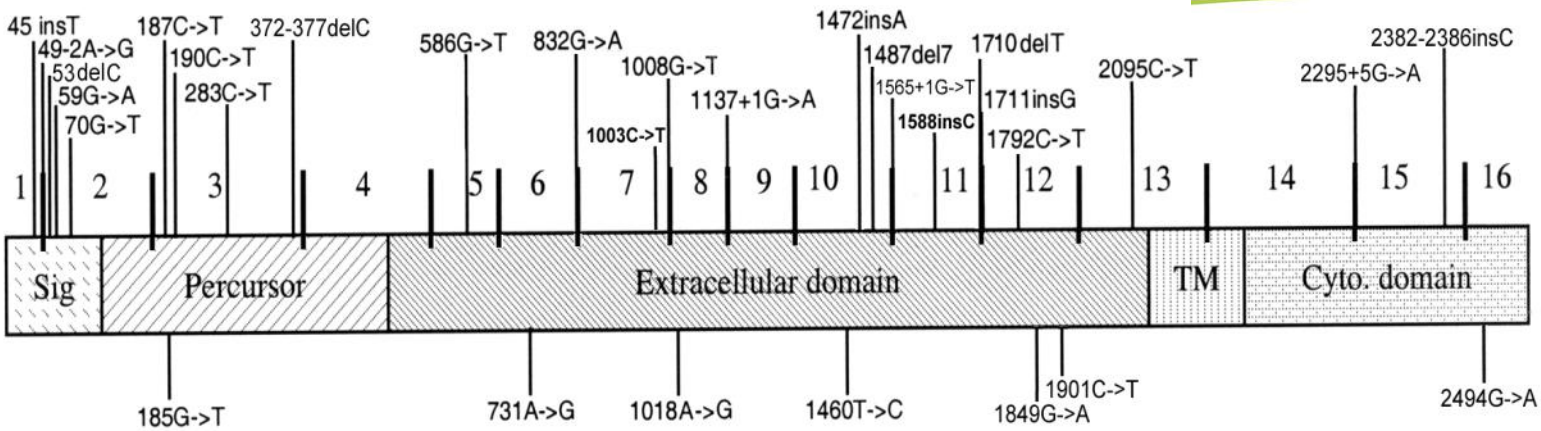

More recently…

An α-E-catenin (*CTNNA1*) mutation in hereditary diffuse gastric cancer

The Journal of Pathology
Volume 229, Issue 4, pages 621–629, March 2013

Even more recently…

Original Investigation

Hereditary Diffuse Gastric Cancer Syndrome
CDH1 Mutations and Beyond

within genes of high and moderate penetrance: *CTNNA1*, *BRCA2*, *STK11*, *SDHB*, *PRSS1*, *ATM*, *MSR1*, and *PALB2*.

JAMA Oncol. doi:10.1001/jamaoncol.2014.168

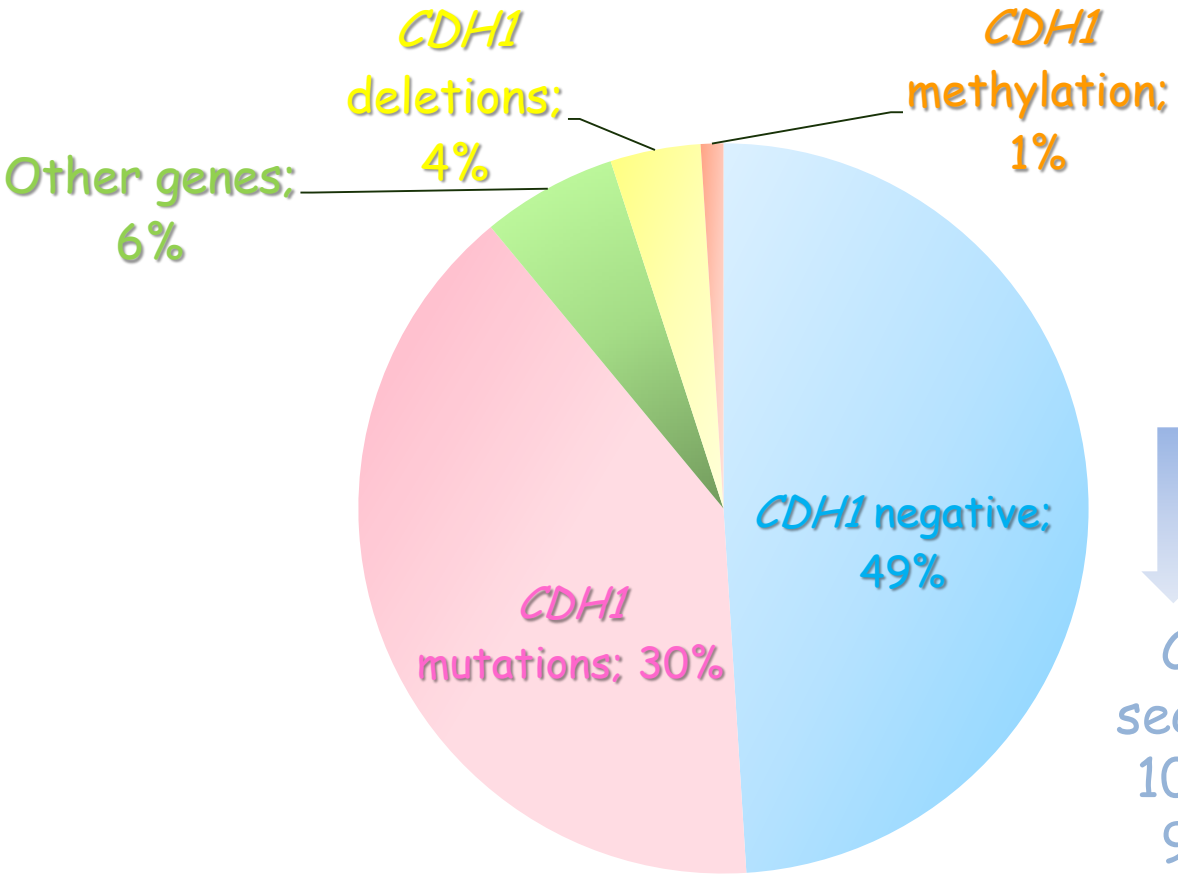

Currently, ongoing sequencing of the full 100kb *CDH1 locus* in 90 HDGC patients

Oliveira C et al, Hum Mol Genet, 2009
Pinheiro H et al. Hum Mol Genet, 2010

Gastric Adenocarcinoma and Proximal Polyposis of the Stomach (GAPPS): a new autosomal dominant syndrome.

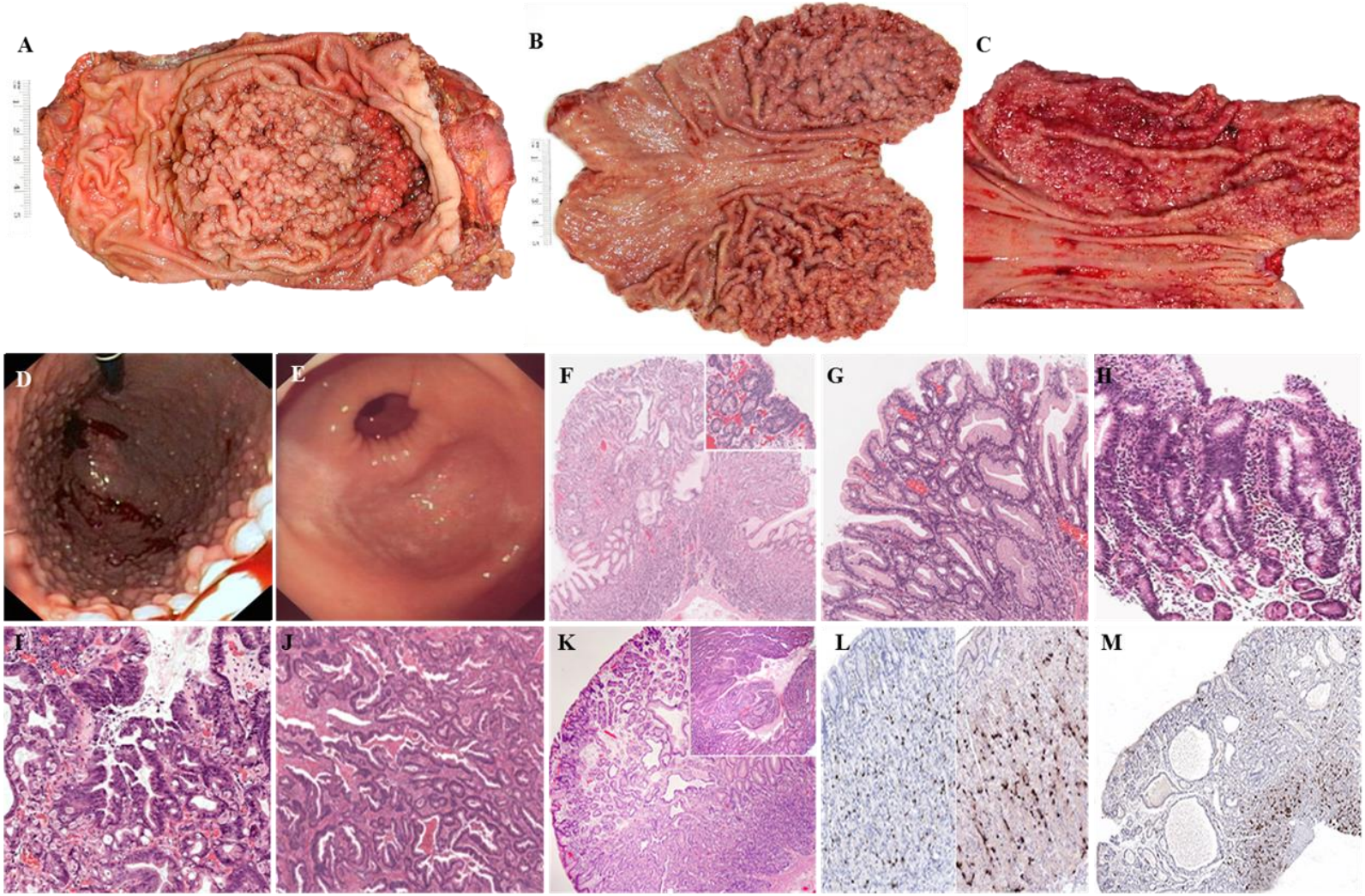

Genetic cause recently identified…

Worthley et al; Gut 61:774-779, 2012

Gastric adenocarcinoma and proximal polyposis of the stomach (GAPPS): a new autosomal dominant syndrome

D L Worthley,[1] K D Phillips,[2] N Wayte,[3] K A Schrader,[4] S Healey,[5] P Kaurah,[4] A Shulkes,[6] F Grimpen,[7] A Clouston,[7] D Moore,[8] D Cullen,[9] D Ormonde,[9] D Mounkley,[10] X Wen,[11] N Lindor,[11] F Carneiro,[11] D G Huntsman,[4] G Chenevix-Trench,[5] G K Suthers[2,12]

ABSTRACT

Objective The purpose of this study was the clinical and pathological characterisation of a new autosomal dominant gastric polyposis syndrome, gastric adenocarcinoma and proximal polyposis of the stomach (GAPPS).

Methods Case series were examined, documenting GAPPS in three families from Australia, the USA and Canada. The affected families were identified through referral to centralised clinical genetics centres.

Results The report identifies the clinical and pathological features of this syndrome, including the predominant dysplastic fundic gland polyp histology, the exclusive involvement of the gastric body and fundus, the app inverse association with current *Helicobacter pylori* infection and the autosomal dominant mode of inheritance.

Conclusions GAPPS is a unique gastric polyposis syndrome with a significant risk of gastric adenocarcinoma. It is characterised by the autosor dominant transmission of fundic gland polyposis, including areas of dysplasia or intestinal-type gastr adenocarcinoma, restricted to the proximal stomach with no evidence of colorectal or duodenal polypos other heritable gastrointestinal cancer syndromes.

include *MUTYH*-associated polypo generalised juvenile polyposis syndro Peutz Jeghers syndrome (PJS) an syndrome.[5 6] However, FGPs are relati MAP, an autosomal recessive disorder, a PJS are often characterised by the specific hamartomatous (rather th dysplastic fundic gland) polyps.[5 6]

Sporadic FGPs are usually inno syndromic FGPs can progress to dy gastric adenocarcinoma.[7 9] Therefor must distinguish patients with spo syndromic fundic gland polyposis so th

Downloaded from gut.bmj.com on October 31, 2011 - Published by group.bmj.com
Gut Online First, published on October 25, 2011 as 10.1136/gutjnl-2011-301384

PostScript

LETTER

Familial fundic gland polyposis with gastric cancer

We read with interest the article by Worthley *et al*[1] regarding a new autosomal dominant syndrome characterised by fundic gland polyposis (FGP) and gastric cancer, which was not associated with familial adenomatous polyposis (FAP). We have experienced two similar cases of gastric adenocarcinoma occurring in pedigrees with familial FGP without FAP.

CASE 1

A 56-year-old woman was referred to our institution for further investigation of her multiple gastric polyps. On admission, serology and ^{13}C urea breath test yielded negative results for *Helicobacter pylori*. Upper gastrointestinal endoscopy revealed polyps covering the us (figure 1A). In the a flat and discoloured polyps (figure 1B). A evealed well-differen- No other polyps or n the duodenum. The show any colorectal an of the chest and A total gastrectomy scopically, there were id lesions. There was measuring 6×5.5 cm figure 1C). Histologi- fundic gland polyps ted (figure 1D). The ferentiated adenocar- ling the superficial osa (figure 1E). Since tous polyposis was ed an upper endos- amily members: two o daughters, one son sult, five of the seven astric FGP (figure 2).

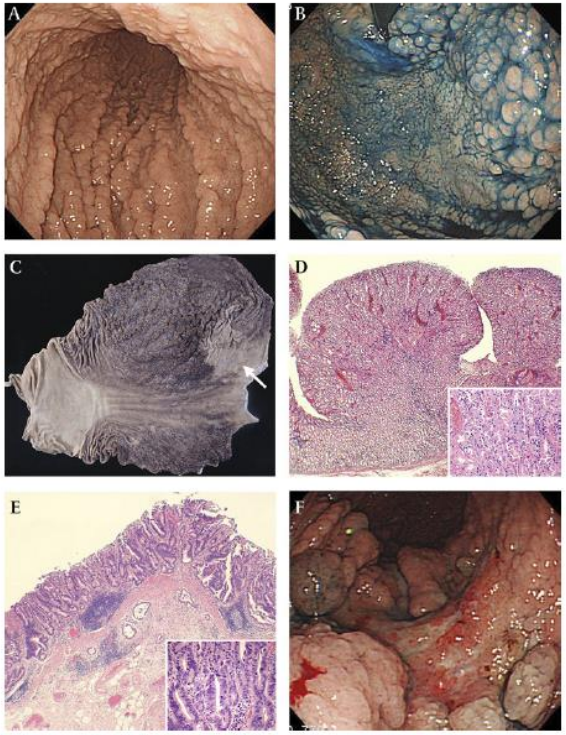

Figure 1 Endoscopic and pathological findings. (A and B) Case 1. Endoscopic images reveal numerous fundic gland polyps in the corpus (A), while a flat area circumscribed by polyps can be seen in the fundus (B). (C) Macroscopic finding of the gastrectomy specimen showing numerous

Mutations were excluded in the following genes:

- *APC*
- *MUTYH*
- *CDH1*
- *SMAD4*
- *BMPR1A*
- *STK11*
- *PTEN*

Point Mutations in Exon 1B of *APC* Reveal Gastric Adenocarcinoma and Proximal Polyposis of the Stomach as a Familial Adenomatous Polyposis Variant

Jun Li,[1] Susan L. Woods,[2] Sue Healey,[1] Jonathan Beesley,[1] Xiaoqing Chen,[1] Jason S. Lee,[1] Haran Sivakumaran,[1] Nicci Wayte,[1] Katia Nones,[1] Joshua J. Waterfall,[3] John Pearson,[1,4] Anne-Marie Patch,[1] Janine Senz,[5] Manuel A. Ferreira,[1] Pardeep Kaurah,[6] Robertson Mackenzie,[7] Alireza Heravi-Moussavi,[8] Samantha Hansford,[5] Tamsin R.M. Lannagan,[2] Amanda B. Spurdle,[1] Peter T. Simpson,[9,10] Leonard da Silva,[9,10] Sunil R. Lakhani,[9,10,11] Andrew D. Clouston,[12,13] Mark Bettington,[10,13,14] Florian Grimpen,[15] Rita A. Busuttil,[16,17,18] Natasha Di Costanzo,[16] Alex Boussioutas,[16,17,18,19] Marie Jeanjean,[20] George Chong,[21] Aurélie Fabre,[22,23,24] Sylviane Olschwang,[22,23,24] Geoffrey J. Faulkner,[25] Evangelos Bellos,[4,26] Lachlan Coin,[4] Kevin Rioux,[27] Oliver F. Bathe,[28,29] Xiaogang Wen,[30,31] Hilary C. Martin,[32] Deborah W. Neklason,[33] Sean R. Davis,[3] Robert L. Walker,[3] Kathleen A. Calzone,[3] Itzhak Avital,[34] Theo Heller,[35] Christopher Koh,[35] Marbin Pineda,[3] Udo Rudloff,[36] Martha Quezado,[37] Pavel N. Pichurin,[38] Peter J. Hulick,[39] Scott M. Weissman,[40] Anna Newlin,[39] Wendy S. Rubinstein,[41] Jone E. Sampson,[42] Kelly Hamman,[42] David Goldgar,[43] Nicola Poplawski,[44,45] Kerry Phillips,[44,45] Lyn Schofield,[46] Jacqueline Armstrong,[44] Cathy Kiraly-Borri,[46] Graeme K. Suthers,[45] David G. Huntsman,[7,47] William D. Foulkes,[20,48] Fatima Carneiro,[30,49] Noralane M. Lindor,[50] Stacey L. Edwards,[1] Juliet D. French,[1] Nicola Waddell,[1,4] Paul S. Meltzer,[3] Daniel L. Worthley,[2] Kasmintan A. Schrader,[6,7] and Georgia Chenevix-Trench,[1,*]

The genetic defect is now identified

The American Journal of Human Genetics (2016), http://dx.doi.org/10.1016/j.ajhg.2016.03.001

APC: Genotype – Phenotype correlations

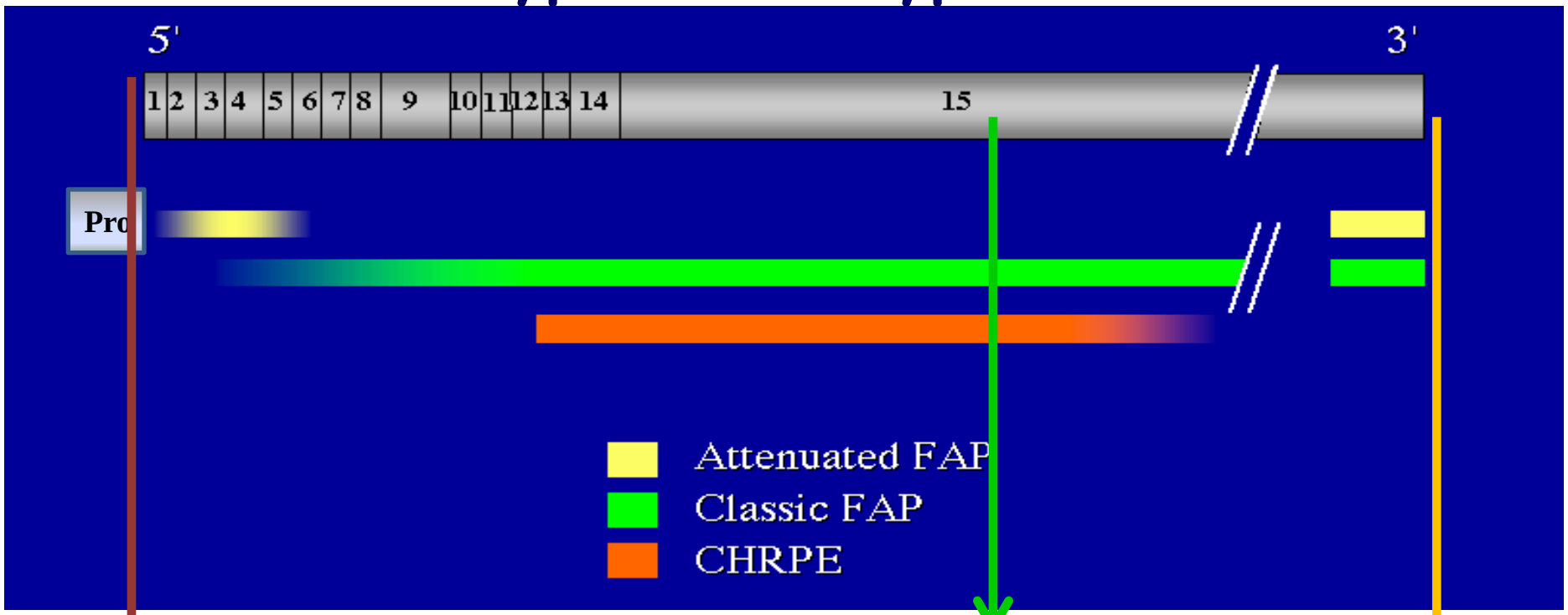

GAPPS
(the stomach is the target)

Severe FAP
(the colon is the main target)

Attenuated FAP
(colon & stomach are the targets)

Hereditary gastric cancer

(1–3% of the burden of stomach cancer)

Hereditary Diffuse Gastric Cancer
HDGC
(*CDH1 ,CTNNA1 and other genes*)

Gastric Adenocarcinoma and Proximal Polyposis of the Stomach (GAPPS)
HIGC
(APC gene)

ESMO 18TH WORLD CONGRESS ON Gastrointestinal CANCER 29 JUNE – 2 JULY 2016 BARCELONA, SPAIN Imedex

PATHWAYS OF GASTRIC CARCINOGENESIS (SPORADIC AND HEREDITARY)

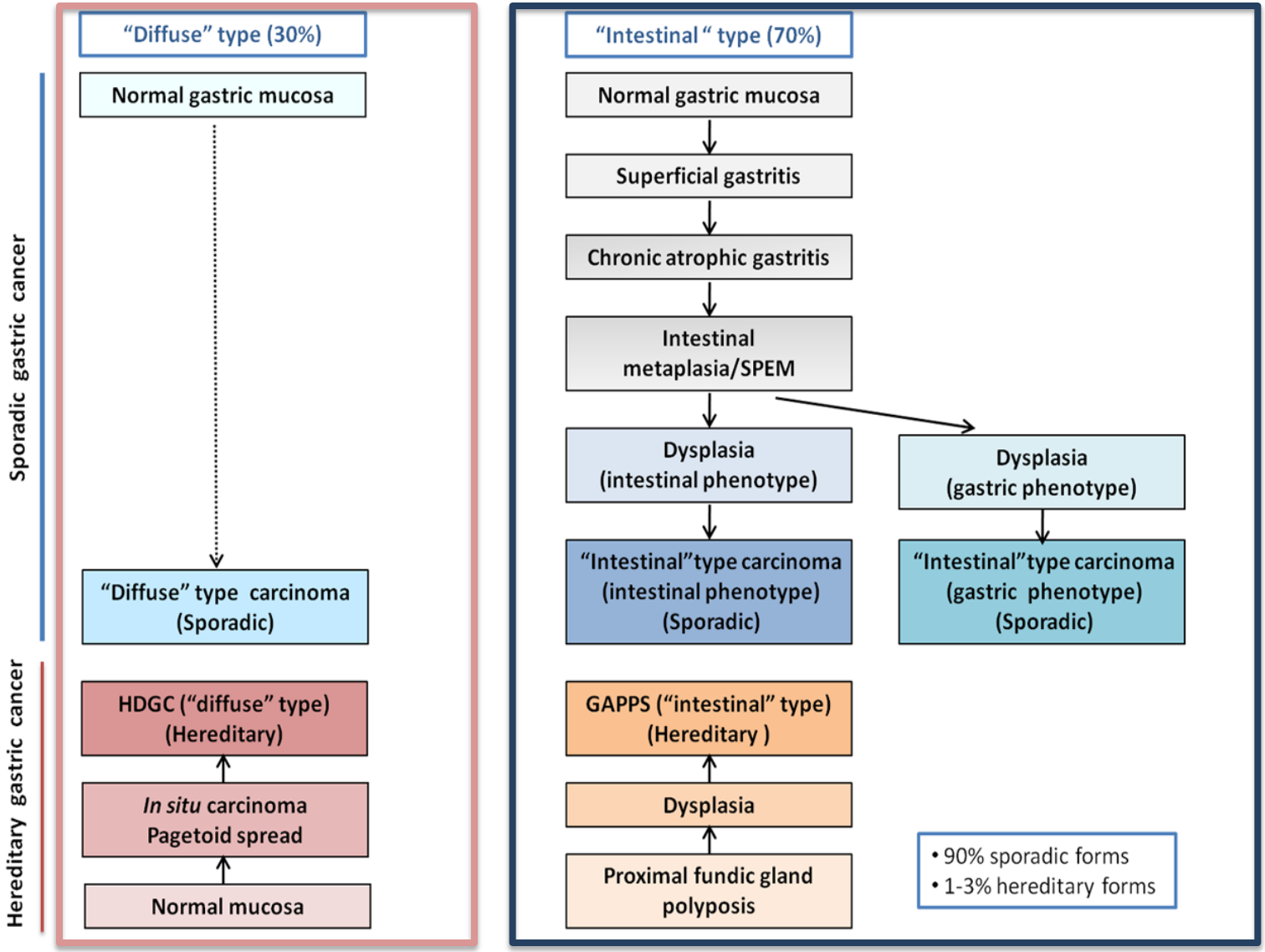

IPATIMUP

Carla Oliveira
Gianpaolo Suriano
José Carlos Machado
Céu Figueiredo
Paulo Ferreira
Rita Mateus
Rachid Karam
Herculano Moreira
Manuel Cardoso de Oliveira
Fátima Carneiro
Raquel Seruca
Manuel Sobrinho-Simões

Hospitais da Universidade de Coimbra

Augusta Cipriano
Mário Rui Silva

UMC St Radboud

Han van Krieken & Joyce de Bruin

amc **Academic Medical Center**

Johan Offerhaus & Anya Milne

Department of Oncology,
University of Cambridge UK

Paul Pharoah & Carlos Caldas

UBC Faculty of Medicine
The University of British Columbia

David Huntsman & David Owen

University of Otago
Te Whare Wānanga o Otāgo
New Zealand

Parry Guilford, Vanessa Blair & Amanda Charlton

Queensland Institute of Medical Research

Georgia Chenevix-Trench

Thanks for your attention