GOOD SCIENCE
BETTER MEDICINE
BEST PRACTICE

ESMO Preceptorship Programme

Breast Cancer

Multidisciplinary management, standards of care, therapeutic targets and future perspectives

Lisbon, Portugal

16-17 September 2016

Locally advanced BC: radiation therapy

Philip Poortmans, MD, PhD

16 September 2016

Past-President

ESTRO
European Society for
RADIOTHERAPY
& ONCOLOGY

Department of
Radiation Oncology

Radboudumc

Conflict of interest: none

1. Introduction

2. Current evidence

3. A technical radiation oncology note

4. How to proceed

5. Conclusions

Radiation therapy for LABC: introduction

Definition:

Locally advanced breast cancer is a subset of breast cancer [illegible] nced breast tumours in the absence of distant metastasis [illegible]

NCCN ➔ AJCC stage III

- *Tumours more than 5 cm in size with [illegible]*
- *Tumours of any size with dire[illegible] les), regardless of regional [illegible]*
- *Presence of re[illegible] r, supraclavicular [illegible]*

Lo[illegible] based on the [illegible] initial surgical [illegible]

The definition of LABC is not uniform across centres globally, considering the varied spectrum of presentation: mind interpretation of studies!

Garg PK, Prakash G. Curr Oncol. 2015;22:e409-10.

Radiation therapy for LABC: introduction

Therapeutic approach:

High rate of locoregional and systemic failure despite the best efforts of surgeons to remove locoregional spread of the tumour in its entirety.

Multimodality treatment is required:

- Surgery
- Systemic therapy: chemotherapy; endocrine and targeted therapy (≈ ER/PR/HER2)
- Radiation therapy
- Possibly: combinations: radiochemotherapy (APBI)

Sequence of systemic and locoregional therapy makes no difference in survival.

Primary systemic therapy (PST) can improve the chances of R0 resection ➔ often preferred!

Garg PK, Prakash G. Curr Oncol. 2015;22:e409-10.

Radiation therapy for LABC: introduction

Therapeutic approach:

High rate of locoregional and systemic failure despite the best efforts of surgeons to remove locoregional spread of the tumour in its entirety.

Multimodality treatment is required:

- Surgery
- Systemic therapy: chemotherapy; endocrine and targeted therapy (≈ ER/PR/HER2)
- Radiation therapy
- Possibly: combinations: radiochemotherapy (APBI)

Sequence of systemic and locoregional therapy makes no difference in survival.

Primary systemic therapy (PST) can improve the chances of R0 resection ➔ often preferred!

Garg PK, Prakash G. Curr Oncol. 2015;22:e409-10.

Radiation therapy for LABC: introduction

Therapeutic approach:

High rate of locoregional and systemic failure despite the best efforts of surgeons to remove locoregional spread of the tumour in its entirety.

Multimodality treatment is required:

- Surgery
- Systemic therapy: chemotherapy; endocrine and targeted therapy (≈ ER/PR/HER2)
- Radiation therapy
- Possibly: combinations: radiochemotherapy (APBI)

Sequence of systemic and locoregional therapy makes no difference in survival.

Preoperative *(or primary)* systemic therapy (PST) can improve the chances of R0 resection ➔ often preferred!

Garg PK, Prakash G. Curr Oncol. 2015;22:e409-10.

Locally advanced breast cancer: radiation therapy

1. Introduction

2. **Current evidence**

3. A technical radiation oncology note

4. How to proceed

5. Conclusions

Radiation therapy for LABC: current evidence

Randomized phase III trials comparing neoadjuvant with adjuvant therapy using the same chemotherapy regimen

Study	*n* (stage and size)	Chemotherapy regimen	cRR (%)	pCR (%)	DFS benefit	OS benefit
Fisher et al. [3, 4], Wolmark et al. [5], NSABP B-18	1,523 (operable)	AC	80	13	No	No
Van der Hage et al. [6], EORTC 10902	698 (T1c–4bN0–1)	FEC	49	4	No	No
Gianni et al. [7, 8], ECTO	1,355	AT → CMF	78	23	No	No
Mauriac et al. [9]	272 (>3 cm)	EMV/MTV	81	NA	No	No
Scholl et al. [10], Broet et al. [11]	414 (T2–3N0–1)	FAC	85	NA	No	No
Makris et al. [12]	309 (operable)	MM(M)+Tam	84	10	No	No

Sachelarie, Grossbard, Chadha et al. *The Oncologist* 2006;11:574–589

Radiation therapy for LABC: current evidence

6 studies (713 pts) PST + surgery ± RT

JOURNAL OF CLINICAL ONCOLOGY ORIGINAL REPORT

Postmastectomy Radiation Improves Local-Regional Control and Survival for Selected Patients With Locally Advanced Breast Cancer Treated With Neoadjuvant Chemotherapy and Mastectomy

Eugene H. Huang, Susan L. Tucker, Eric A. Strom, Marsha D. McNeese, Henry M. Kuerer, Aman U. Buzdar, Vicente Valero, George H. Perkins, Naomi R. Schechter, Kelly K. Hunt, Aysegul A. Sahin, Gabriel N. Hortobagyi, and Thomas A. Buchholz

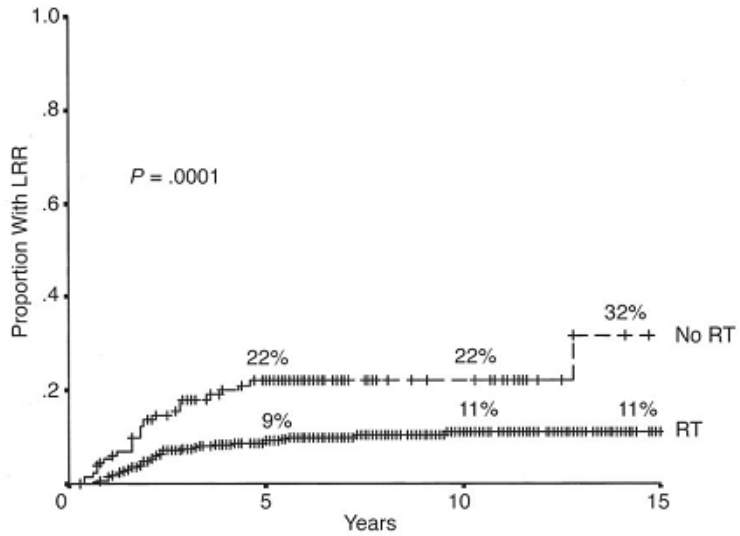

	No. Patients	No. Events
No RT	134	28
RT	542	50

Factor	10-year LRR Rate: No Radiation (%)	10-year LRR Rate: Radiation (%)	P
Clinical T-stage			
T1	0	8	.535
T2	10	7	.408
T3	22	8	.002
T4	46	15	< .0001
Clinical N-stage			
N0	23	10	.014
N1	14	9	.062
N2-3	40	12	< .0001
Pathological tumor size, cm			
0-2	13	8	.051
2.1-5.0	31	14	.002
≥ 5.1	52	13	.001
No. of positive nodes			
0	11	4	.010
1-3	13	11	.636
≥ 4	59	16	< .0001

Huang EH, et al. J Clin Oncol. 2004;22:4691-9.

Radiation therapy for LABC: current evidence

226 pts PST ➔ pCR + surgery ± RT

POSTMASTECTOMY RADIATION IMPROVES THE OUTCOME OF PATIENTS WITH LOCALLY ADVANCED BREAST CANCER WHO ACHIEVE A PATHOLOGIC COMPLETE RESPONSE TO NEOADJUVANT CHEMOTHERAPY

SEAN E. MCGUIRE, M.D., PH.D.,* ANA M. GONZALEZ-ANGULO, M.D.,† EUGENE H. HUANG, M.D.,* SUSAN L. TUCKER, PH.D.,‡ SHU-WAN C. KAU, PH.D.,† TSE-KUAN YU, M.D., PH.D.,* ERIC A. STROM, M.D.,* JULIA L. OH, M.D.,* WENDY A. WOODWARD, M.D., PH.D.,* WELELA TEREFFE, M.D.,* KELLY K. HUNT, M.D.,§ HENRY M. KUERER, M.D., PH.D.,§ AYSEGUL A. SAHIN, M.D.,‖ GABRIEL N. HORTOBAGYI, M.D.,† AND THOMAS A. BUCHHOLZ, M.D.*

Departments of *Radiation Oncology, †Breast Medical Oncology, ‡Biostatistics and Applied Mathematics, §Surgical Oncology, and ‖Pathology, The University of Texas M. D. Anderson Cancer Center, Houston, TX

Int. J. Radiation Oncology Biol. Phys., Vol. 68, No. 4, pp. 1004–1009, 2007

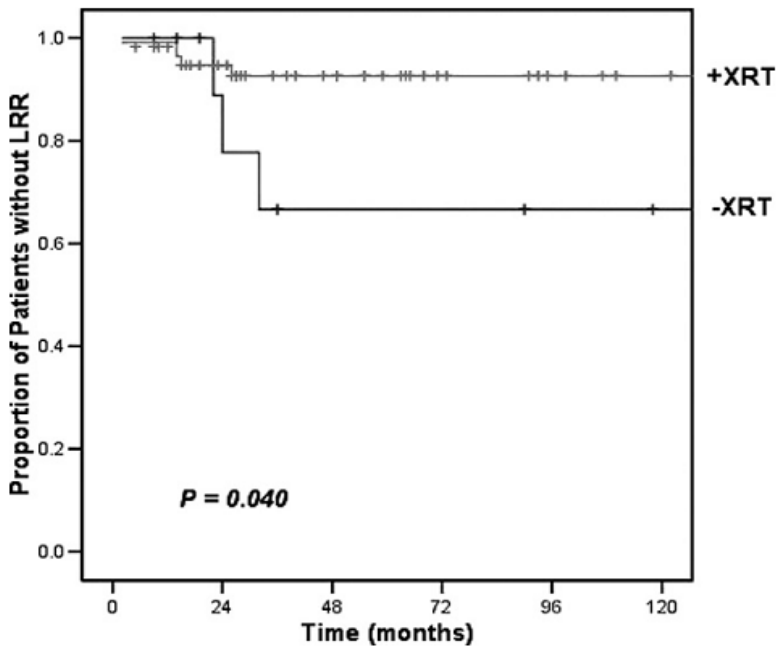

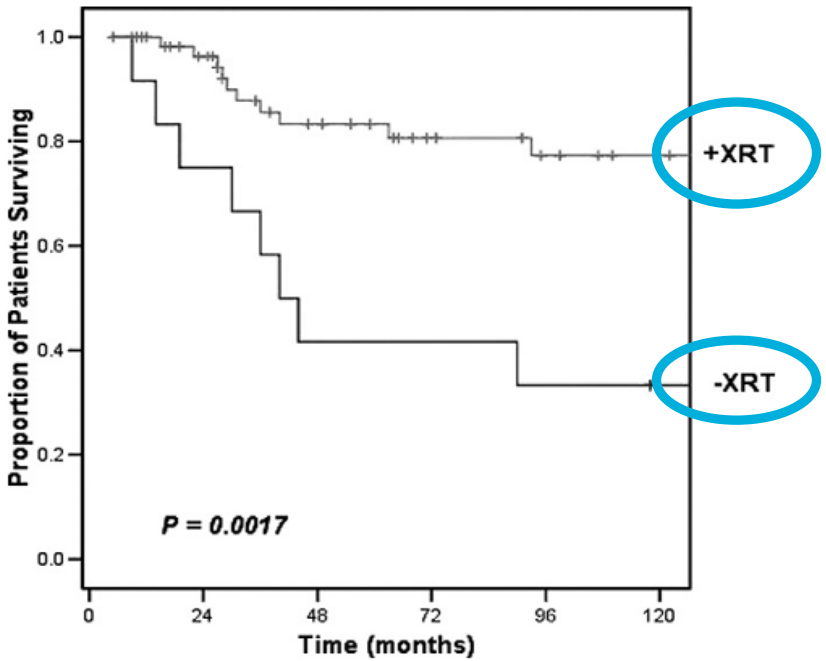

McGuire SE, et al. Int J Radiat Oncol Biol Phys. 2007;68:1004-9.

Radboudumc

Radiation therapy for LABC: interpretation

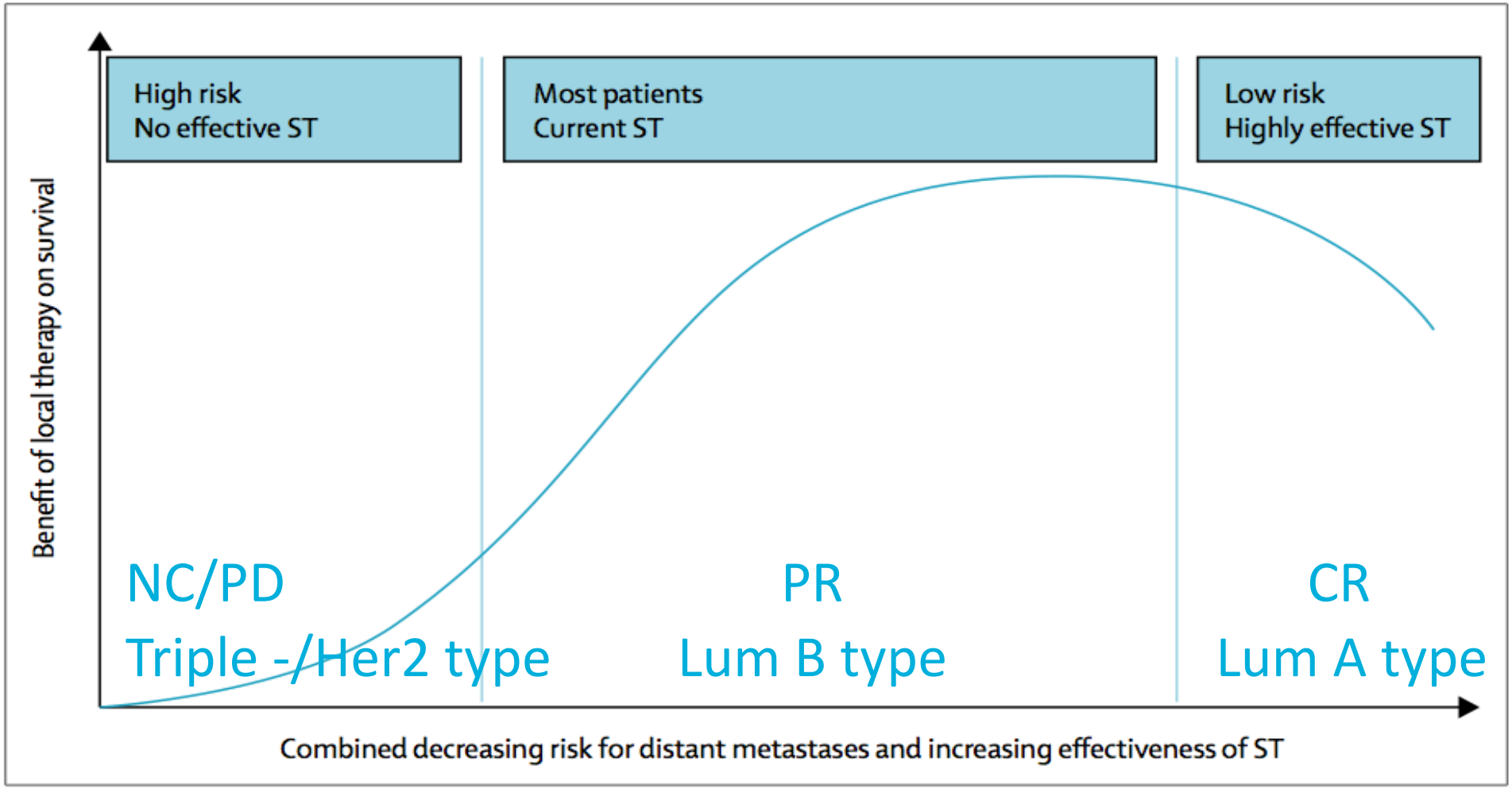

***Figure*: Combined hypothetical benefit of local tumour control on survival with increasing effectiveness of systemic therapy (ST) and decreasing risk of distant metastases of the primary tumour**

Poortmans P. Lancet. 2014 Jun 21;383(9935):2104-6.

Radboudumc

Radiation therapy for LABC: interpretation

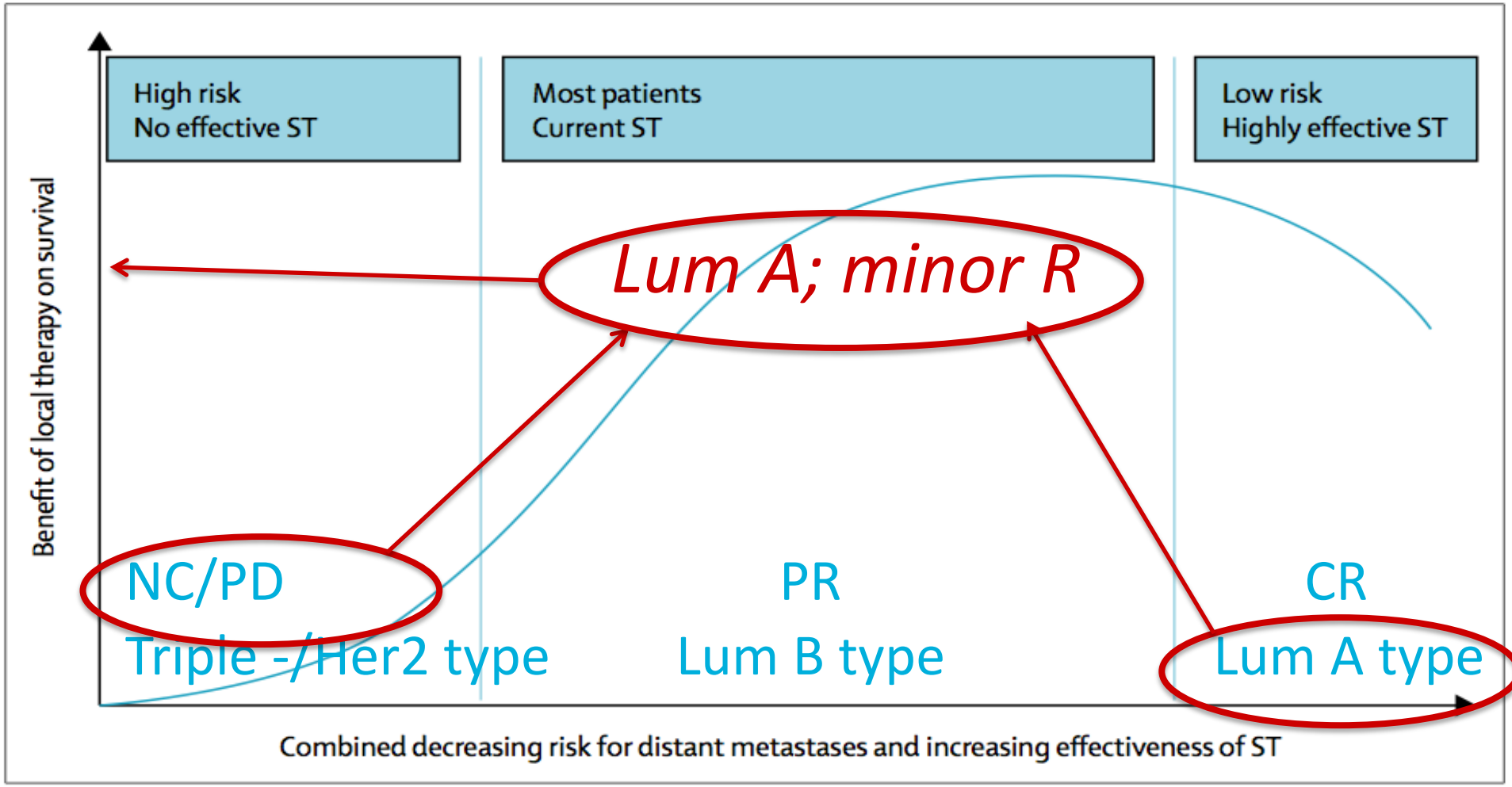

***Figure*: Combined hypothetical benefit of local tumour control on survival with increasing effectiveness of systemic therapy (ST) and decreasing risk of distant metastases of the primary tumour**

Poortmans P. Lancet. 2014 Jun 21;383(9935):2104-6.

Radboudumc

Radiation therapy for LABC: interpretation

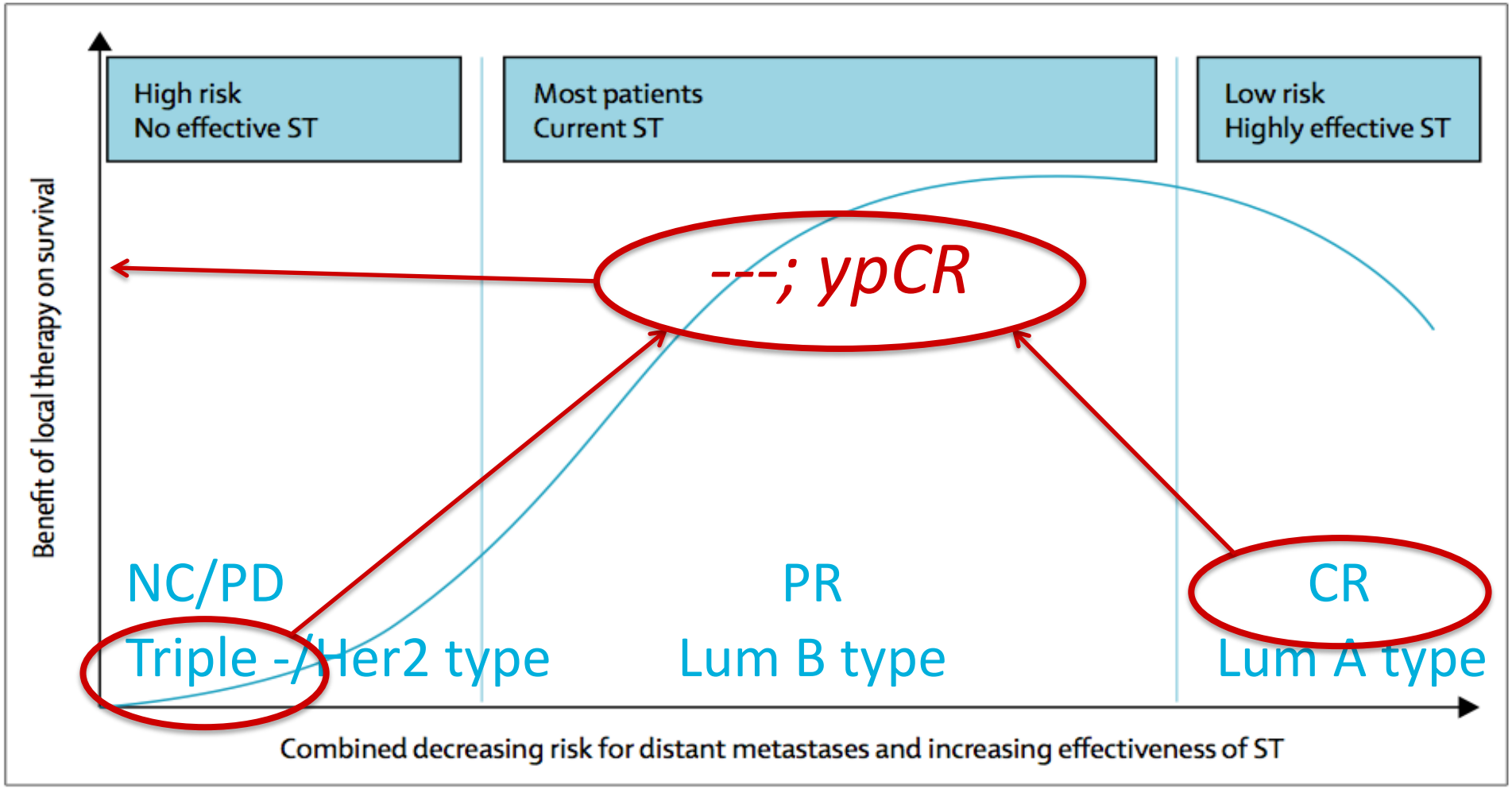

***Figure*: Combined hypothetical benefit of local tumour control on survival with increasing effectiveness of systemic therapy (ST) and decreasing risk of distant metastases of the primary tumour**

Poortmans P. Lancet. 2014 Jun 21;383(9935):2104-6.

Radboudumc

Radiation therapy for LABC: interpretation

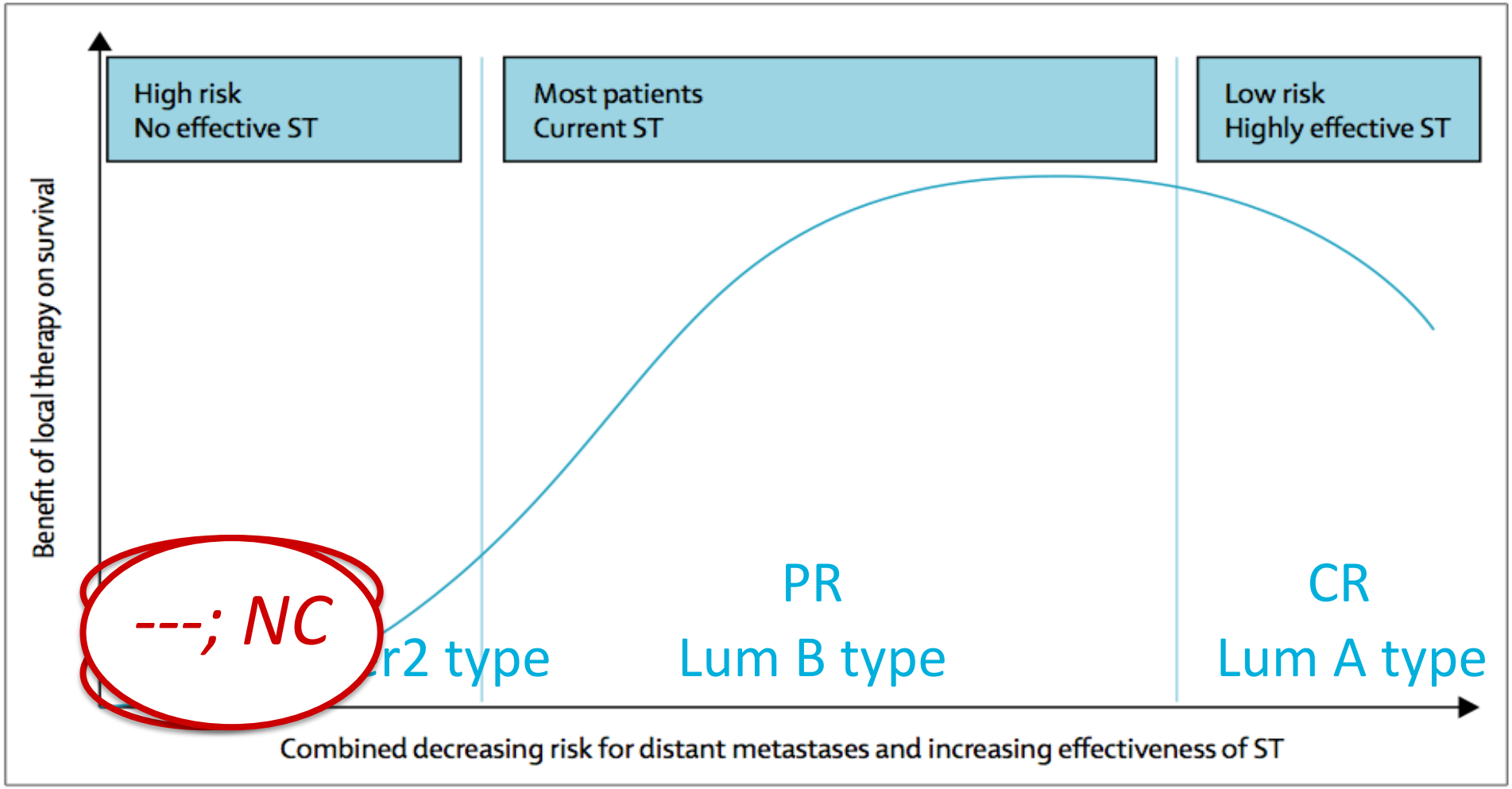

***Figure*: Combined hypothetical benefit of local tumour control on survival with increasing effectiveness of systemic therapy (ST) and decreasing risk of distant metastases of the primary tumour**

Poortmans P. Lancet. 2014 Jun 21;383(9935):2104-6.

Radboudumc

1. Introduction

2. Current evidence

3. A technical radiation oncology note

4. How to proceed

5. Conclusions

Radiation therapy for LABC: technical RT note

Planning-CT-scan before and after PST

March 2013: patient age 49

- Tumour central in left breast:
- Biopsy (histology): IDA G3; triple –
- FNA axillary LN: +
- FNA supraclavicular LN: +
- Conclusion after staging: cT3N3M0

Treatment: PST

- Referred for evaluation by RO
- TAC x 6

Radiation therapy for LABC: technical RT note

Planning-CT-scan before and after PST

May 2013:

- Major tumour regression on MRI

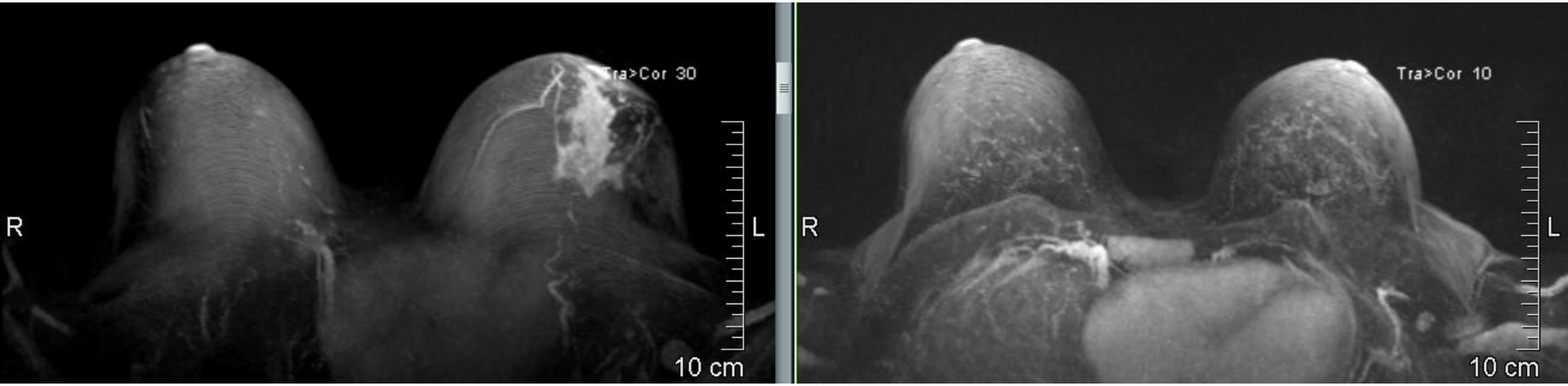

Treatment:

- Continue TAC ➔ July 2013
- MRM: ypT0ypN0
- PMRT + boost on non-removed nodes

Radiation therapy for LABC: technical RT note

Planning-CT-scan before and after PST

March 2013

September 2013

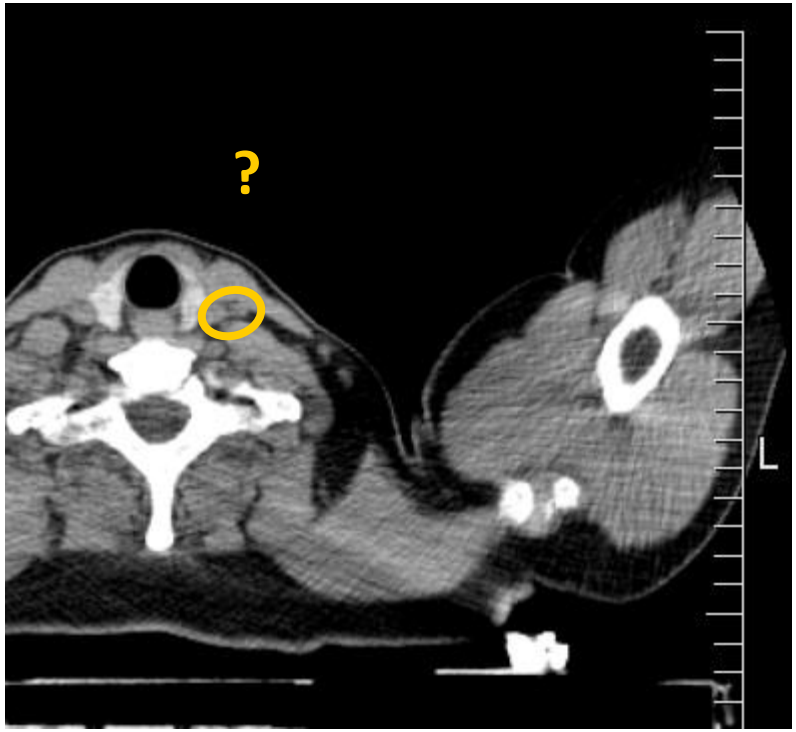

Radiation therapy for LABC: technical RT note

Planning-CT-scan before and after PST

March 2013

September 2013

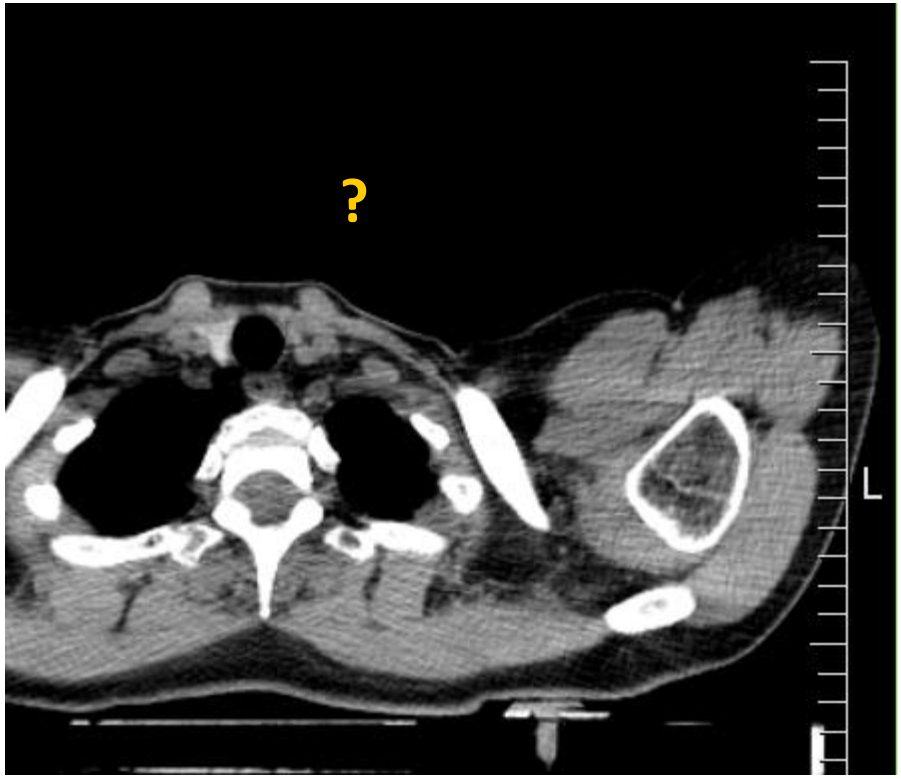

Radiation therapy for LABC: technical RT note

Planning-CT-scan before and after PST

March 2013

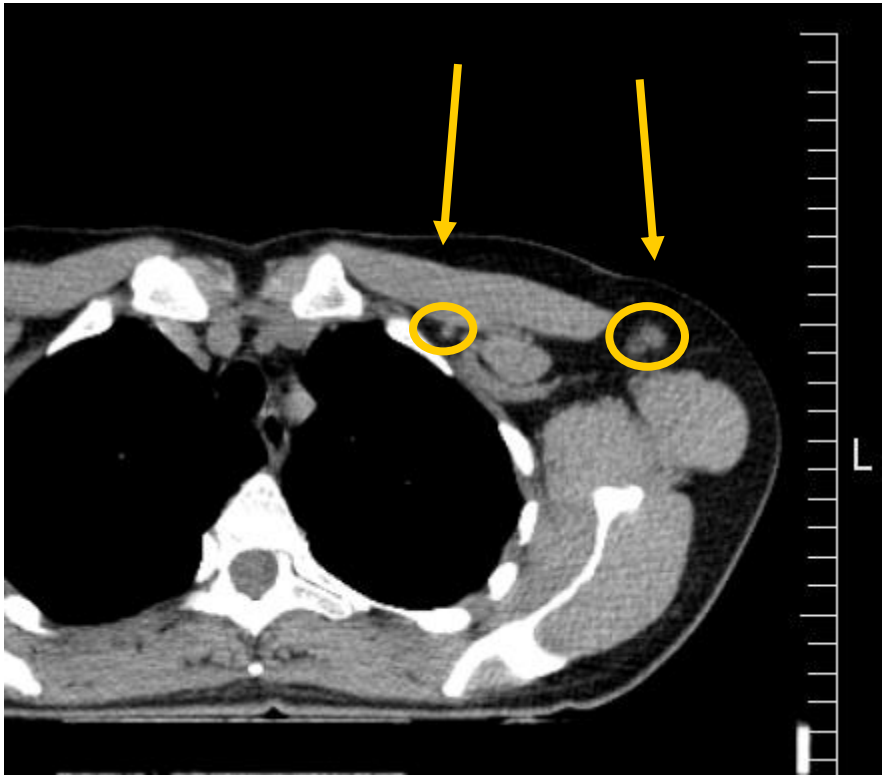

September 2013

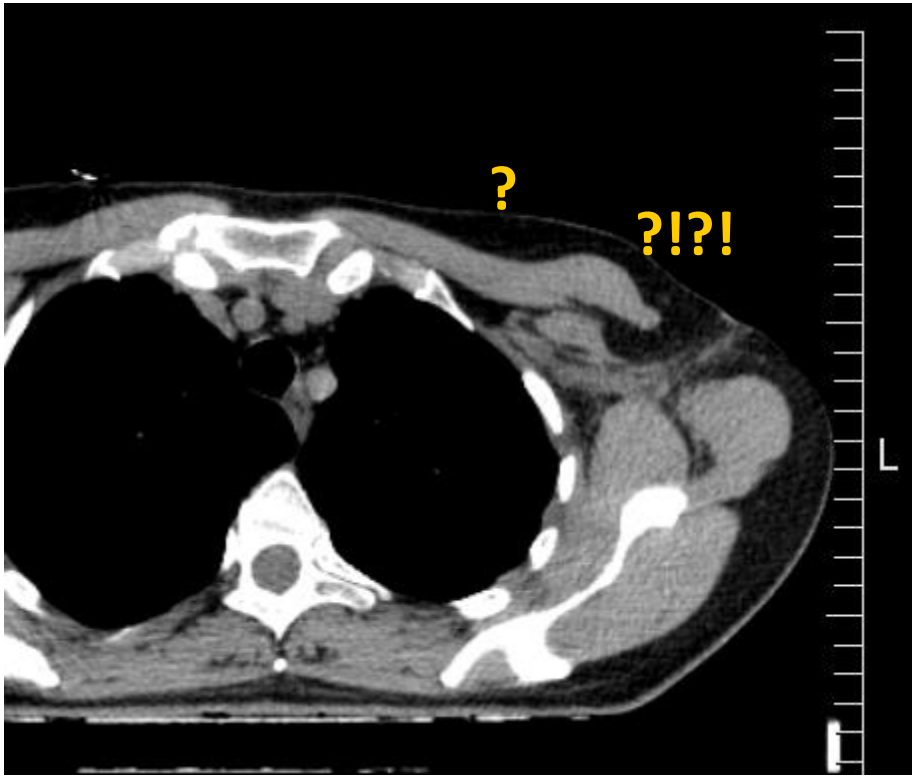

Radiation therapy for LABC: technical RT note

Planning-CT-scan before and after PST

March 2013

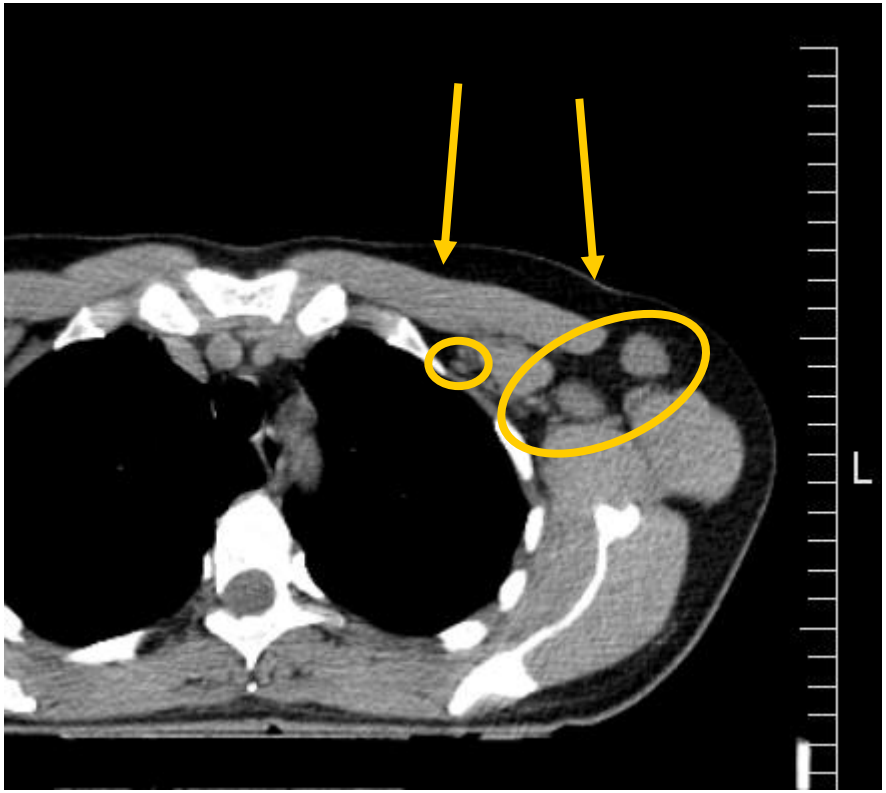

September 2013

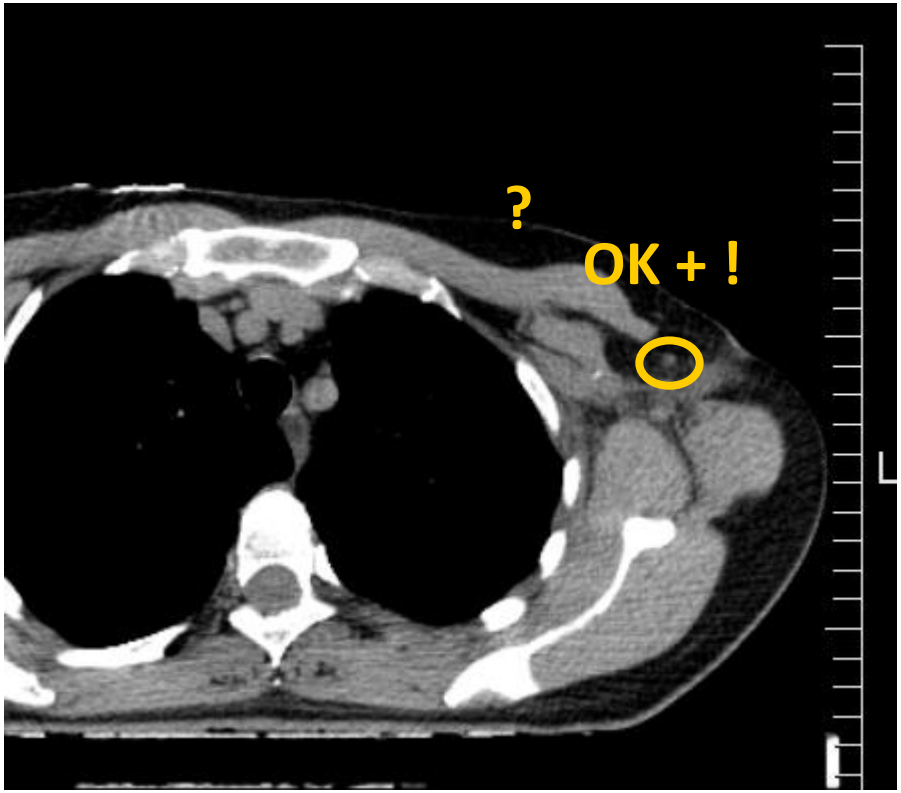

Radiation therapy for LABC: technical RT note

Planning-CT-scan before and after PST

March 2013

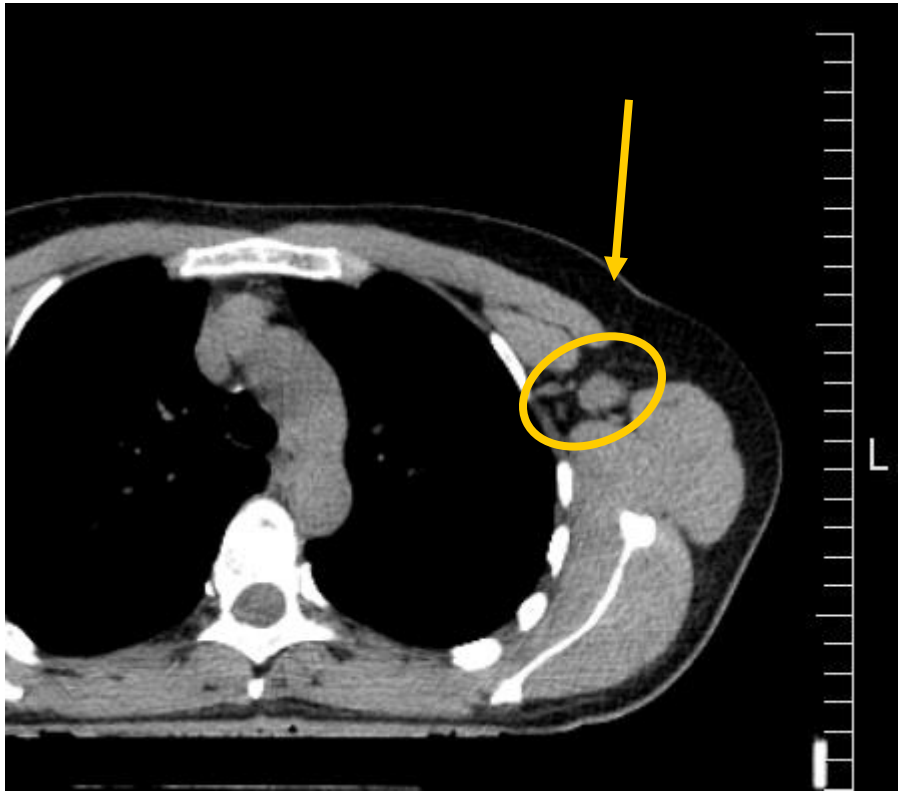

September 2013

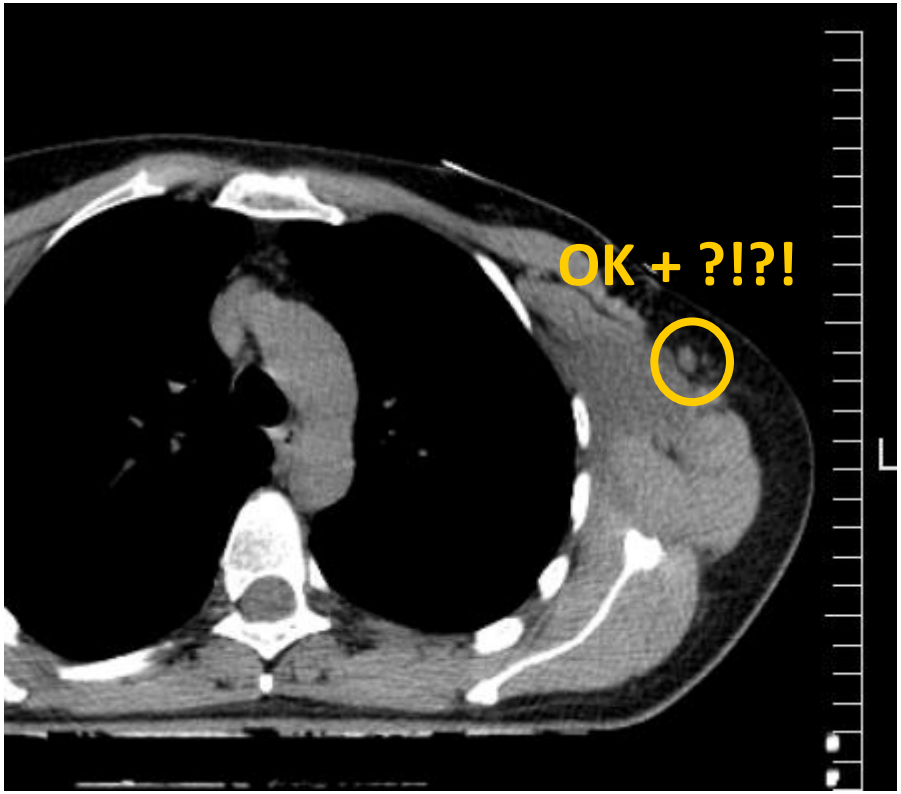

Radiation therapy for LABC: technical RT note

Planning-CT-scan before and after PST

March 2013

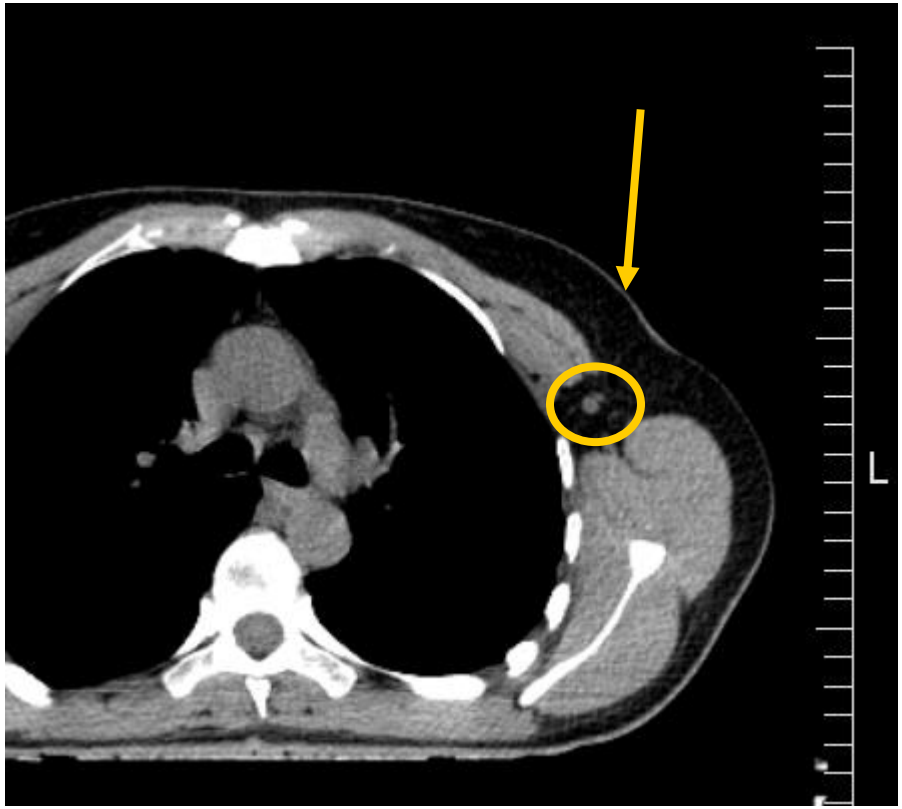

September 2013

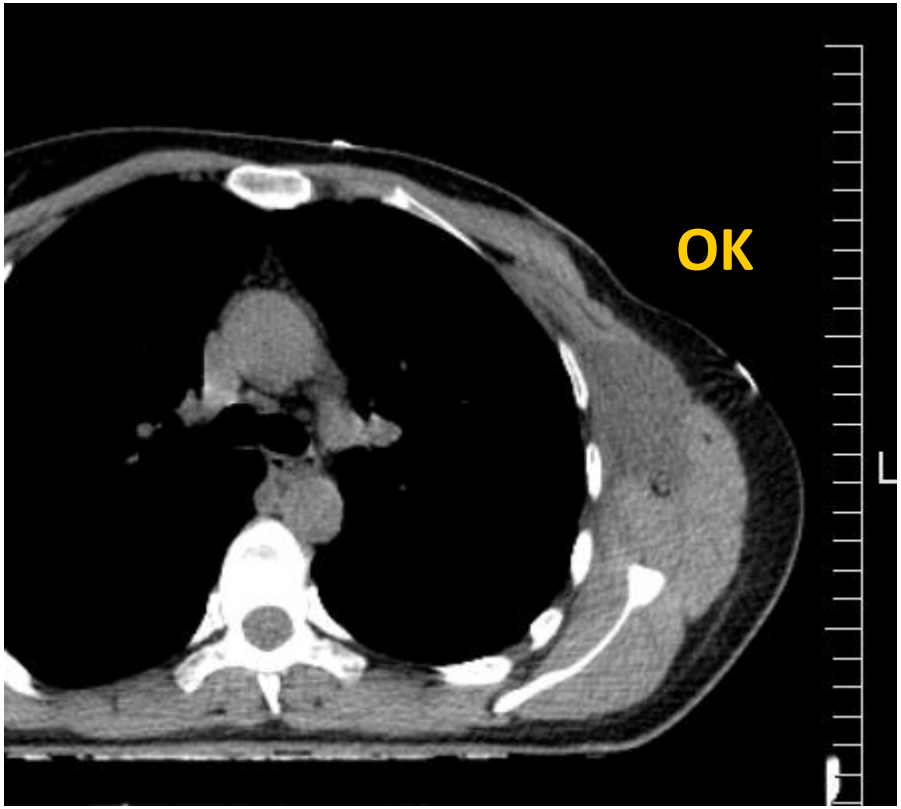

Radiation therapy for LABC: technical RT note

Value of PET-CT for TV delineation

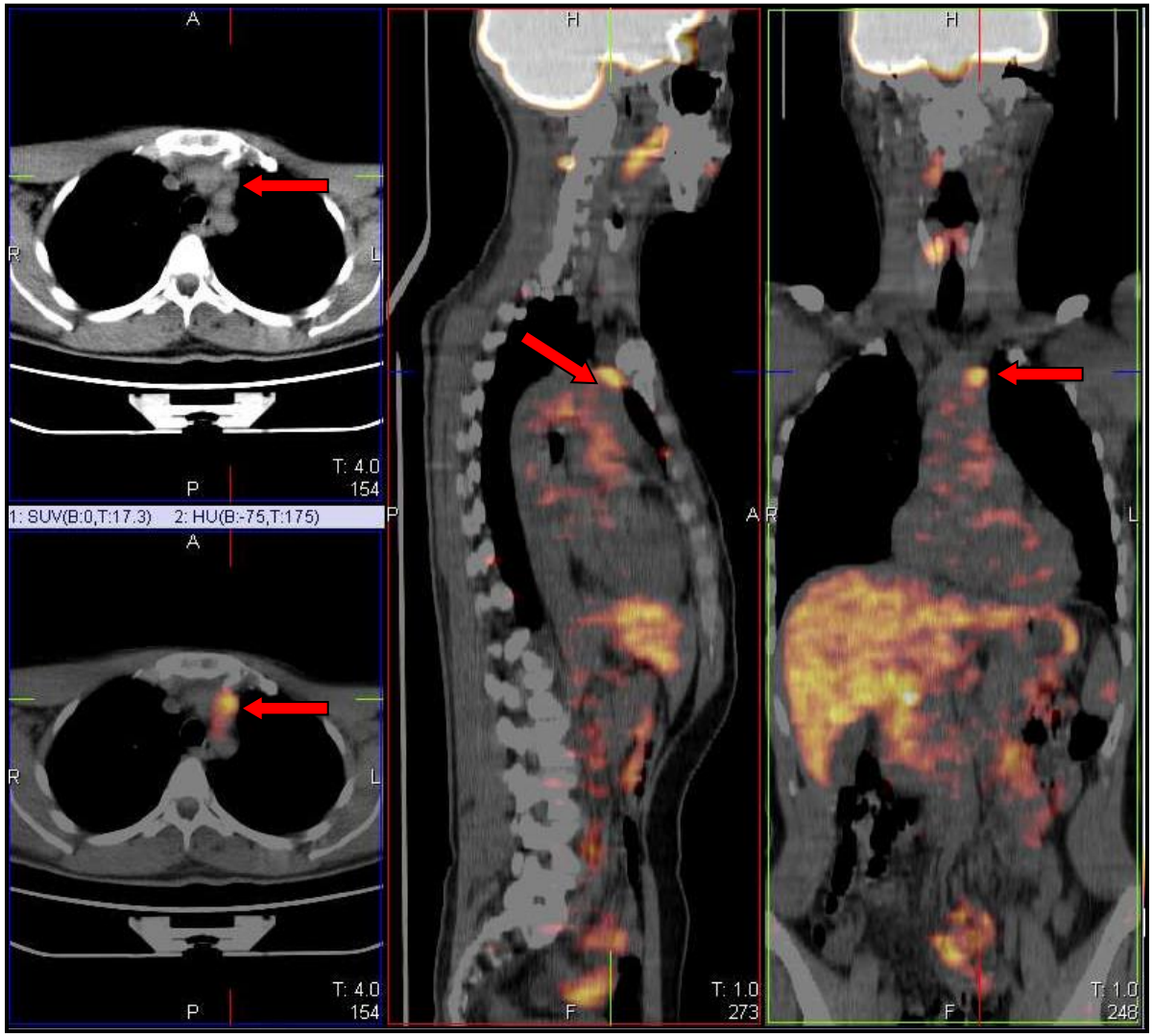

Courtesy of MC Valli and A Fozza

Locally advanced breast cancer: radiation therapy

1. Introduction

2. Current evidence

3. A technical radiation oncology note

4. **How to proceed**

5. Conclusions

Radiation therapy for LABC: how to proceed

National Comprehensive Cancer Network®

NCCN Guidelines Version 1 2.2016

Invasive Breast Cancer

NCCN Guidelines Index
Breast Cancer Table of Contents
Staging, Discussion

PRINCIPLES OF RADIATION THERAPY

In patients treated with preoperative systemic therapy, indications for radiation therapy and treatment fields should be based on the maximum stage from the pre-therapy clinical stage, pathologic stage, and tumor characteristics.

Current prospective studies

ACOSOG A0112012

cT1-T3 cN1 ➔ PST ➔ surgery including SLNB

If N+: ® ALND vs. RT

Radiation therapy for LABC: how to proceed

Current prospective studies

ACTO (Russia):

cT0-T3cN+ ➔ PST ➔ mastectomy

If N-: ® PMRT vs. observation

Radiation therapy for LABC: how to proceed

Current prospective studies

BOOG 2010-03 RAPCHEM

Radiotherapy After Primary CHEMotherapy

for cT1-2N1M0 breast cancer.

Registration project of the Dutch Breast Cancer Trialists' Group (BOOG) in collaboration with the Dutch Cancer Registry (NKR)
open per 1/1/2011

Radiation therapy for LABC: how to proceed

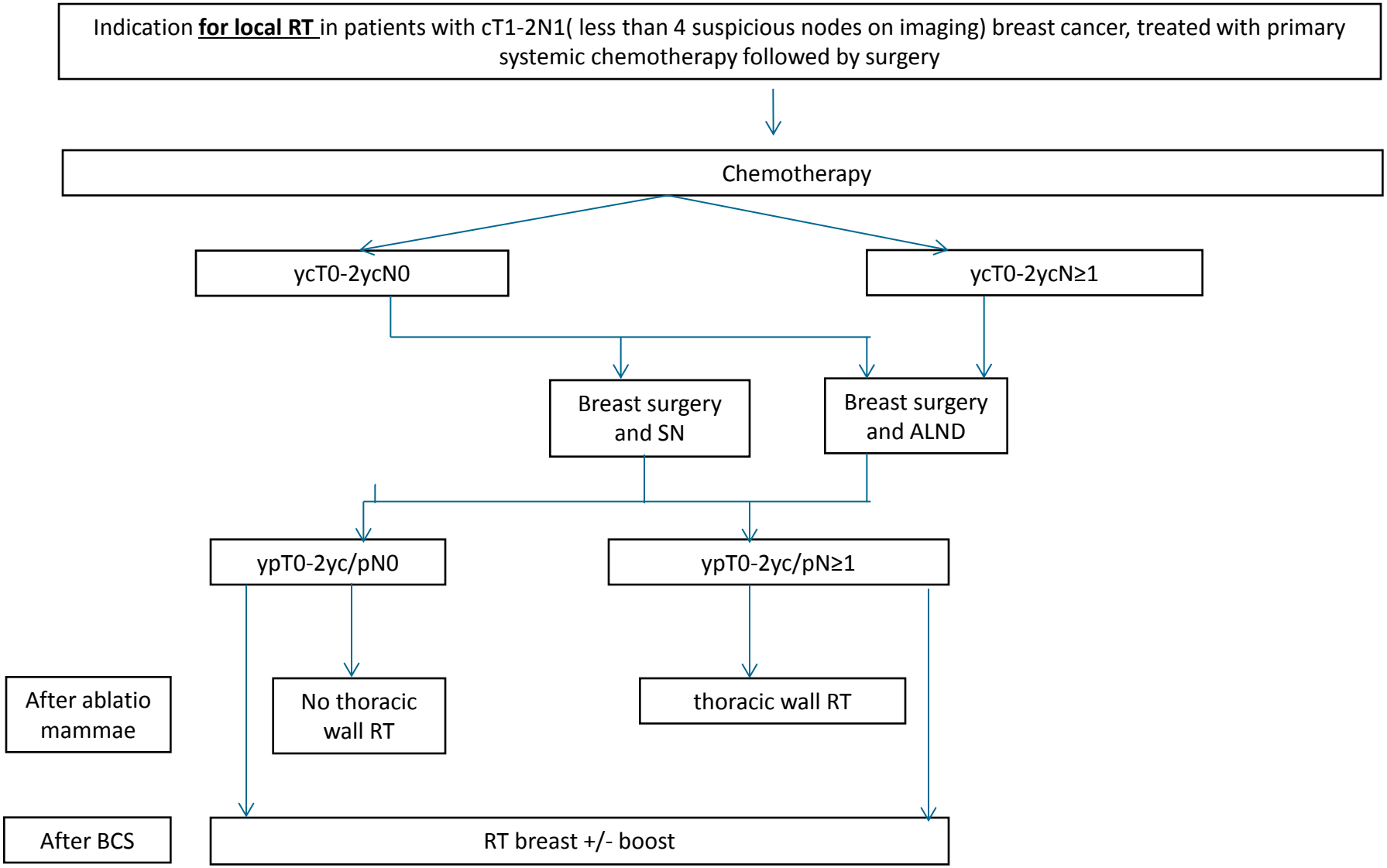

Radiation therapy for LABC: how to proceed

Indication **for nodal RT** in patients with cT1-2N1(less than 4 suspicious nodes on imaging) breast cancer, treated with primary systemic chemotherapy followed by surgery

Chemotherapy

ycT0-2ycN0

ycT0-2ycN≥1

Breast surgery and SN

Breast surgery and ALND

- Pre/post chemotherapy SLNB: micrometastases in ≤ 3 sentinel nodes, and no RF

No axillary RT

- Pre/post chemotherapy SLNB: micrometastases in ≤ 3 sentinel nodes AND ≥ 1 RF, OR
- Pre/post chemotherapy SLNB: Macrometastases in ≤ 2 sentinel nodes and no RF, OR
- Prechemotherapy :palpable nodes or positive nodes on imaging (PA proven)

Axillary RT level 1 and 2

- Pre/post chemotherapy SLNB: ≤ 2 macrometastases and ≥ 1 RF
- Prechemotherapy SLNB: 3 macromets; OR: 2 macro and 1 micromets; OR 1 macro- and 2 micrometastases.

Axillary RT level 1 and 2 AND periclav

ypT3-4, any yc/pN

Periclav RT ; axillary RT level 1 and 2 according to institutional guidelines

** RF = Risk factors on prechemo data: Grade 3, tumorsize > 3 cm, angioinvasion*

RT of Internal Mammary Chain acc to inst. Guidelines, or in case of positive SN in the IMC

Radiation therapy for LABC: how to proceed

Future prospective studies

Radiotherapy and Oncology 102 (2012) 82–88

Contents lists available at SciVerse ScienceDirect

Radiotherapy and Oncology

journal homepage: www.thegreenjournal.com

Phase II trial

Preoperative radio-chemotherapy in early breast cancer patients: Long-term results of a phase II trial ☆

Marc A. Bollet [a], Lisa Belin [b], Fabien Reyal [c], François Campana [a], Rémi Dendale [a], Youlia M. Kirova [a], Fabienne Thibault [d], Véronique Diéras [e], Brigitte Sigal-Zafrani [f], Alain Fourquet [a,*]

[a] Department of Radiation Oncology; [b] Department of Biostatistics; [c] Department of Surgery; [d] Department of Radiology; [e] Department of Medical Oncology; and [f] Department of Tumor Biology, Institut Curie, Paris, France

Bollet MA, et al. Radiother Oncol 2012;102:82-88.

Radiation therapy for LABC: how to proceed

Future prospective studies

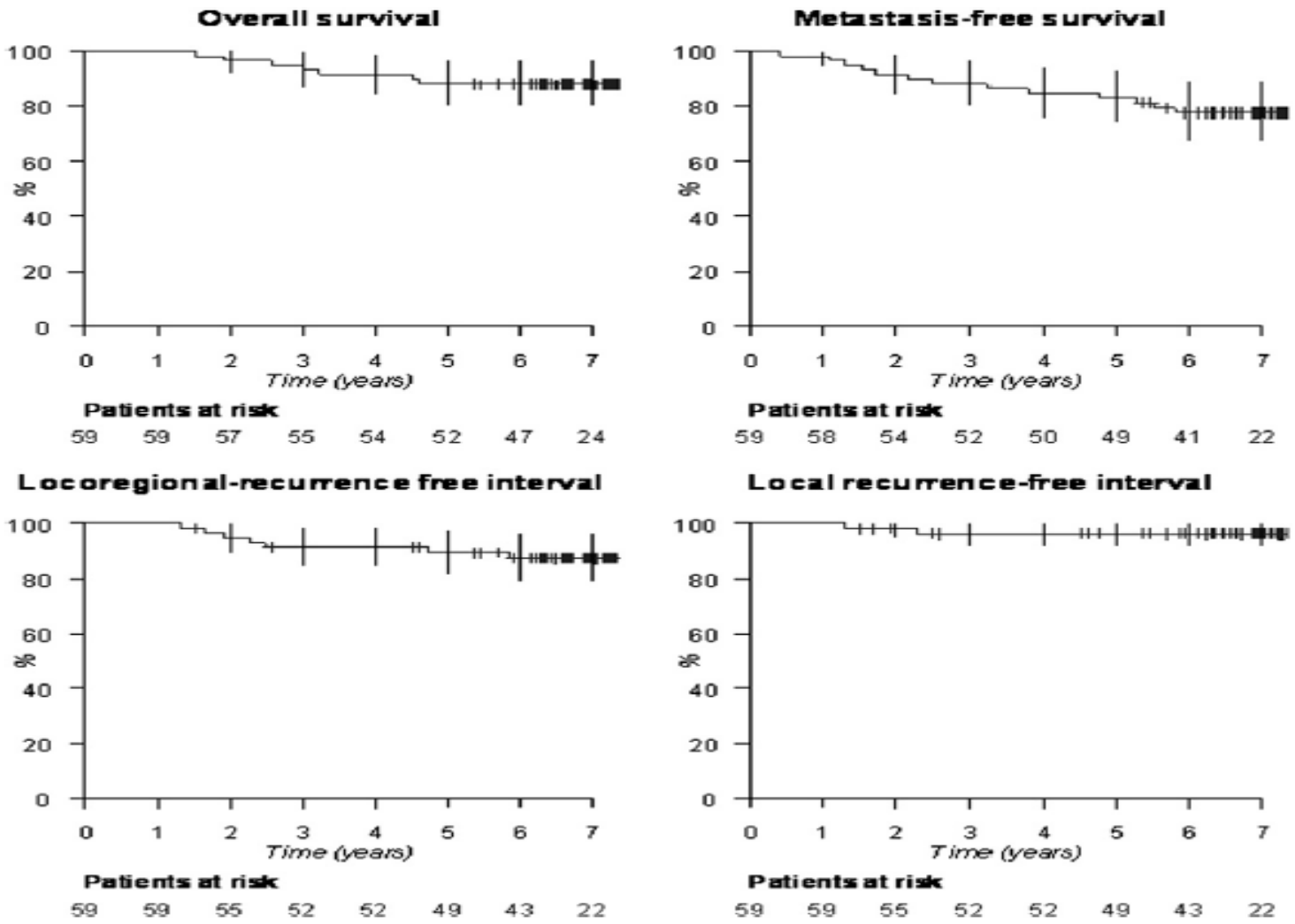

Bollet MA, et al. Radiother Oncol 2012;102:82-88.

Radboudumc

Radiation therapy for LABC: how to proceed

Future prospective studies

In conclusion, preoperative concomitant radio-chemotherapy appears to be a feasible and effective alternative to primary chemotherapy in the treatment of large but operable breast cancers that could be amenable to a secondary breast conserving approach.

These results also prompt us to consider more effective preoperative approaches combining other chemotherapy regimens, radiotherapy including the irradiation of the axilla and targeted therapies. Ultimately, a randomized study between preoperative chemo-radiotherapy and chemotherapy alone will be required.

Bollet MA, et al. Radiother Oncol 2012;102:82-88.

Radiation therapy for LABC: how to proceed

Future prospective studies

Proceedings of the 52nd Annual ASTRO Meeting

207 **Pathologic Features Predicting for High Rates of Local-Regional Recurrence after Neoadjuvant Chemotherapy and Radiation Therapy for Breast Cancer**

K. E. Hoffman, W. F. Symmans, J. Oh, W. Tereffe, T. K. Yu, G. H. Perkins, E. A. Strom, A. M. Gonzalez-Angulo, T. A. Buchholz, W. A. Woodward

The University of Texas M. D. Anderson Cancer Center, Houston, TX

Conclusions: Women with breast cancer that is ER-negative or LVSI-positive who have at least a modest residual cancer burden after neoadjuvant chemotherapy are at markedly increased risk of LRR after surgical resection and local radiation therapy. These women should be considered for enrollment in clinical trials investigating ways to enhance local control, such as trials evaluating concurrent radiosensitizing agents.

So in the meantime…

➔ *consensus agreements*

1. Mastectomy for cT1-4; cN0 (US) no PST

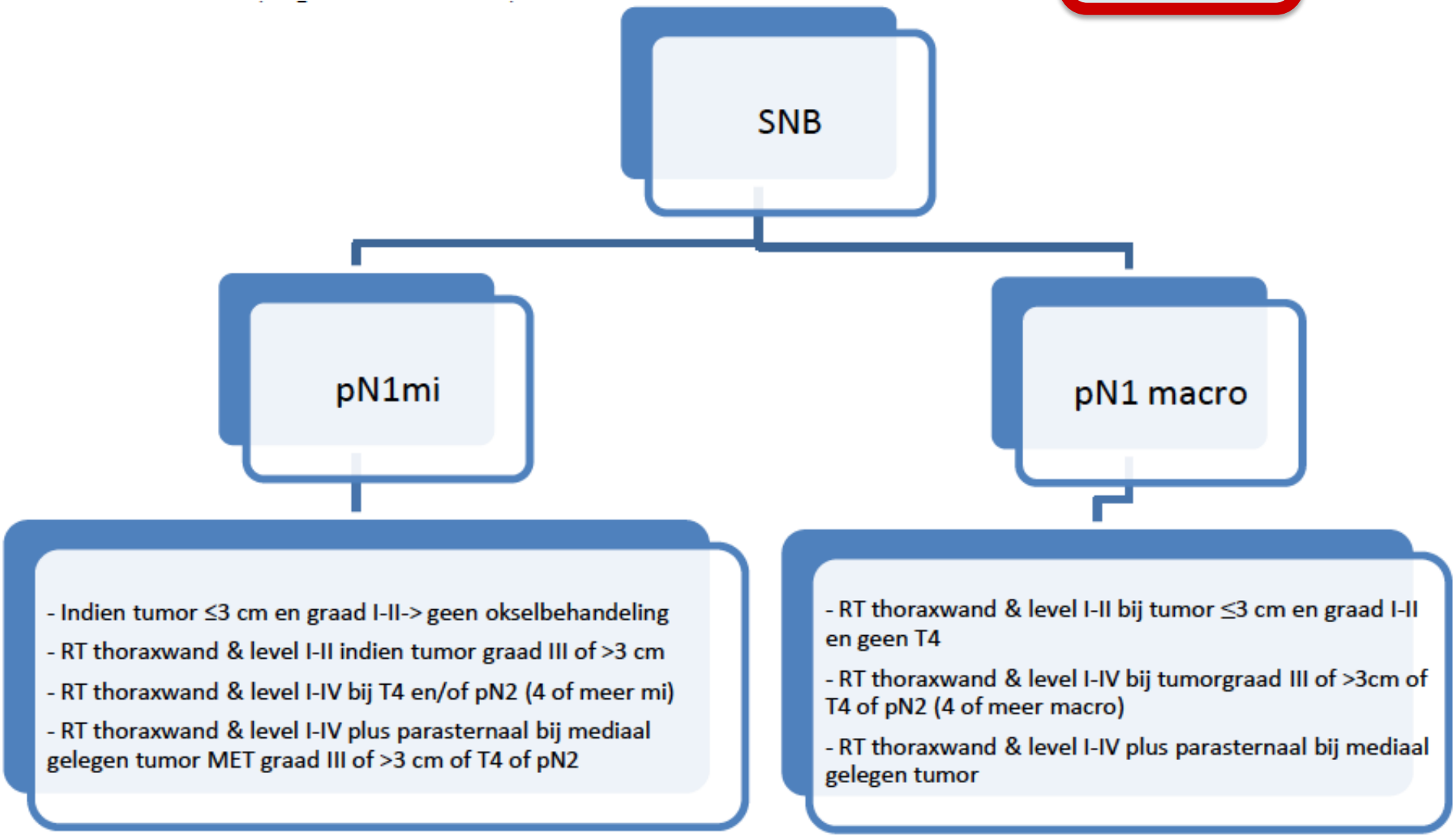

2. BCT for cT1-3; cN0 (US); no PST

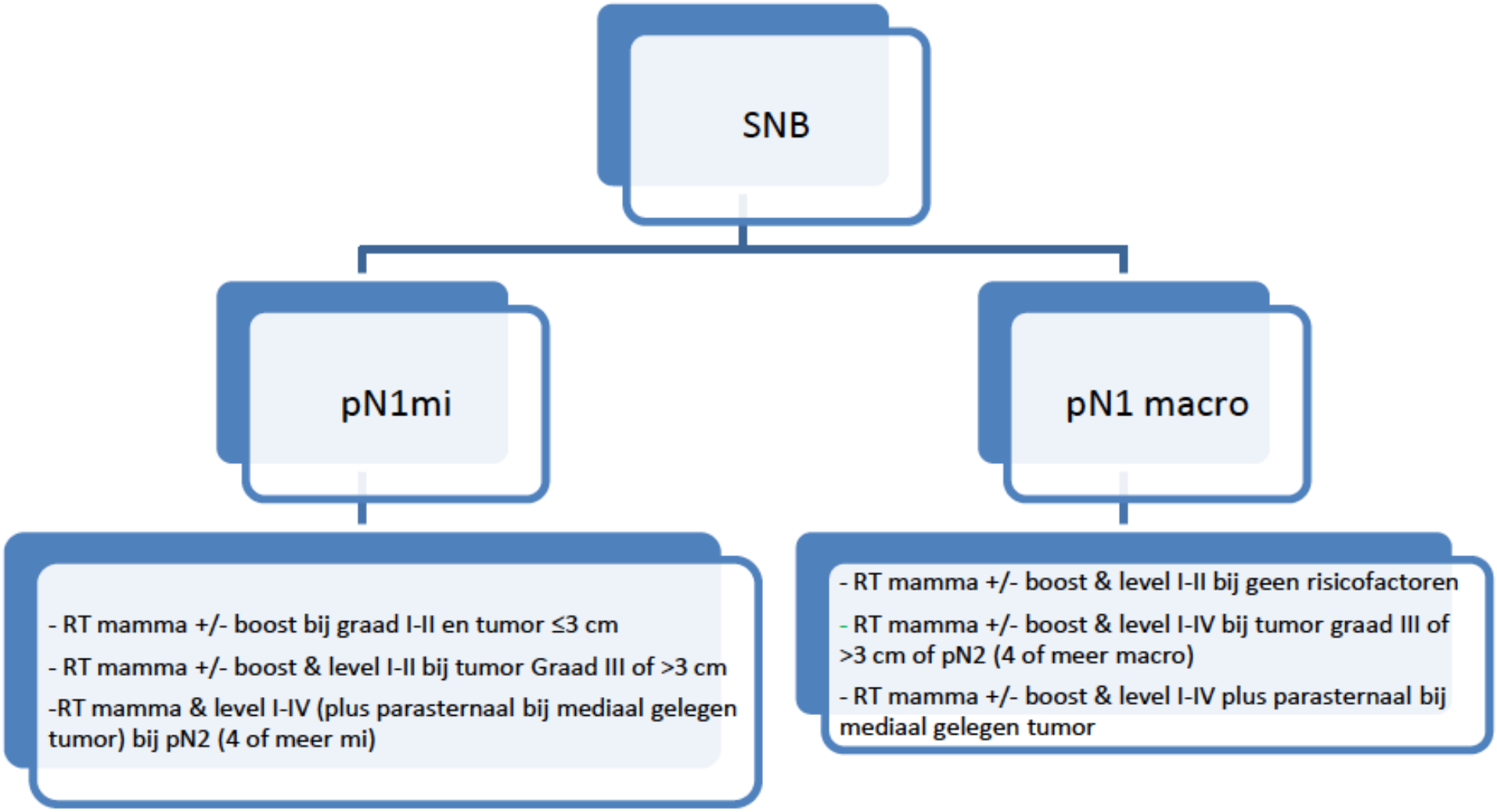

3.1 PST; cN0 (US +/- FNA)

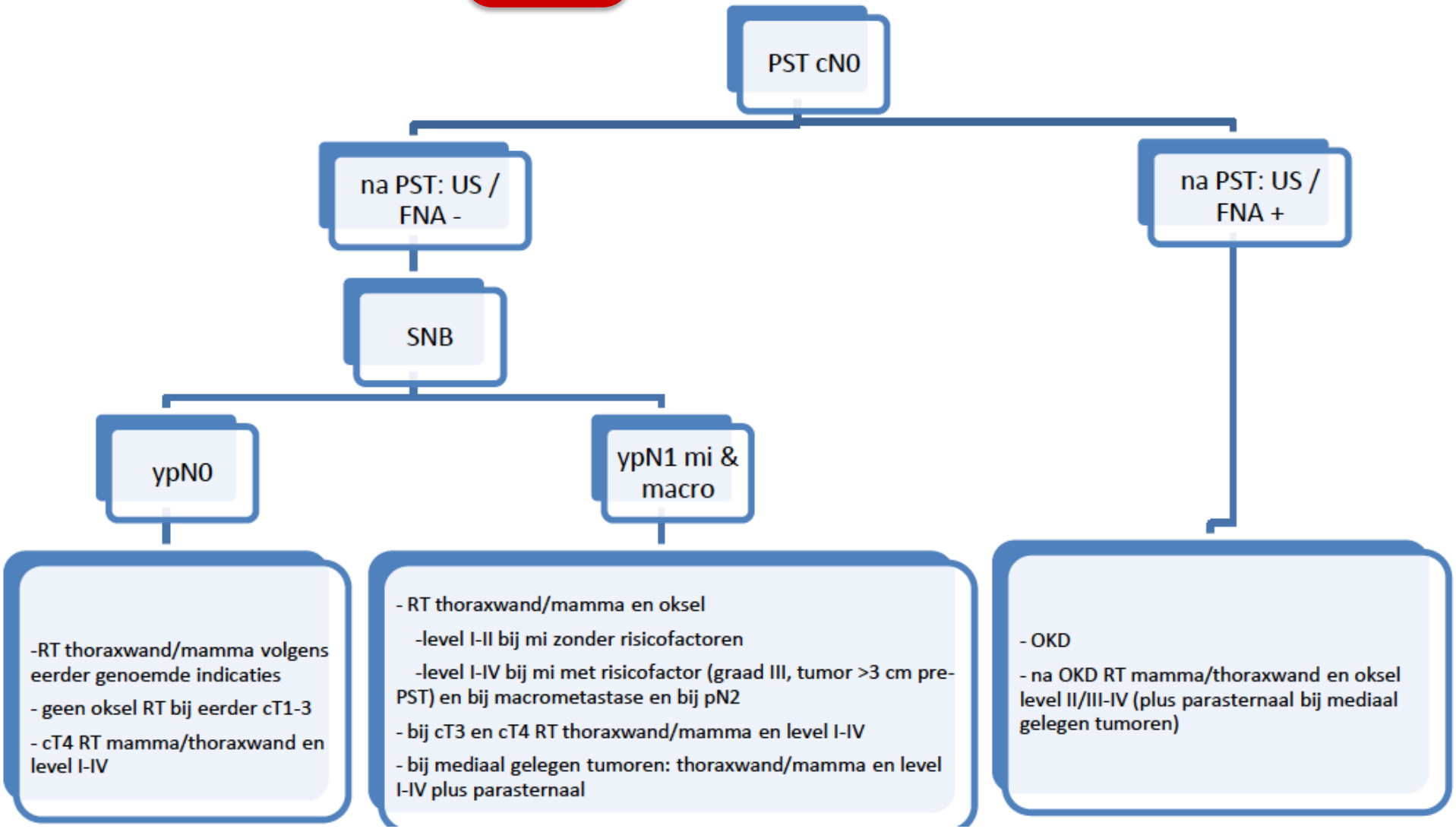

3.2 PST; cN+(1-3) (US +/- FNA); *MARI advised*

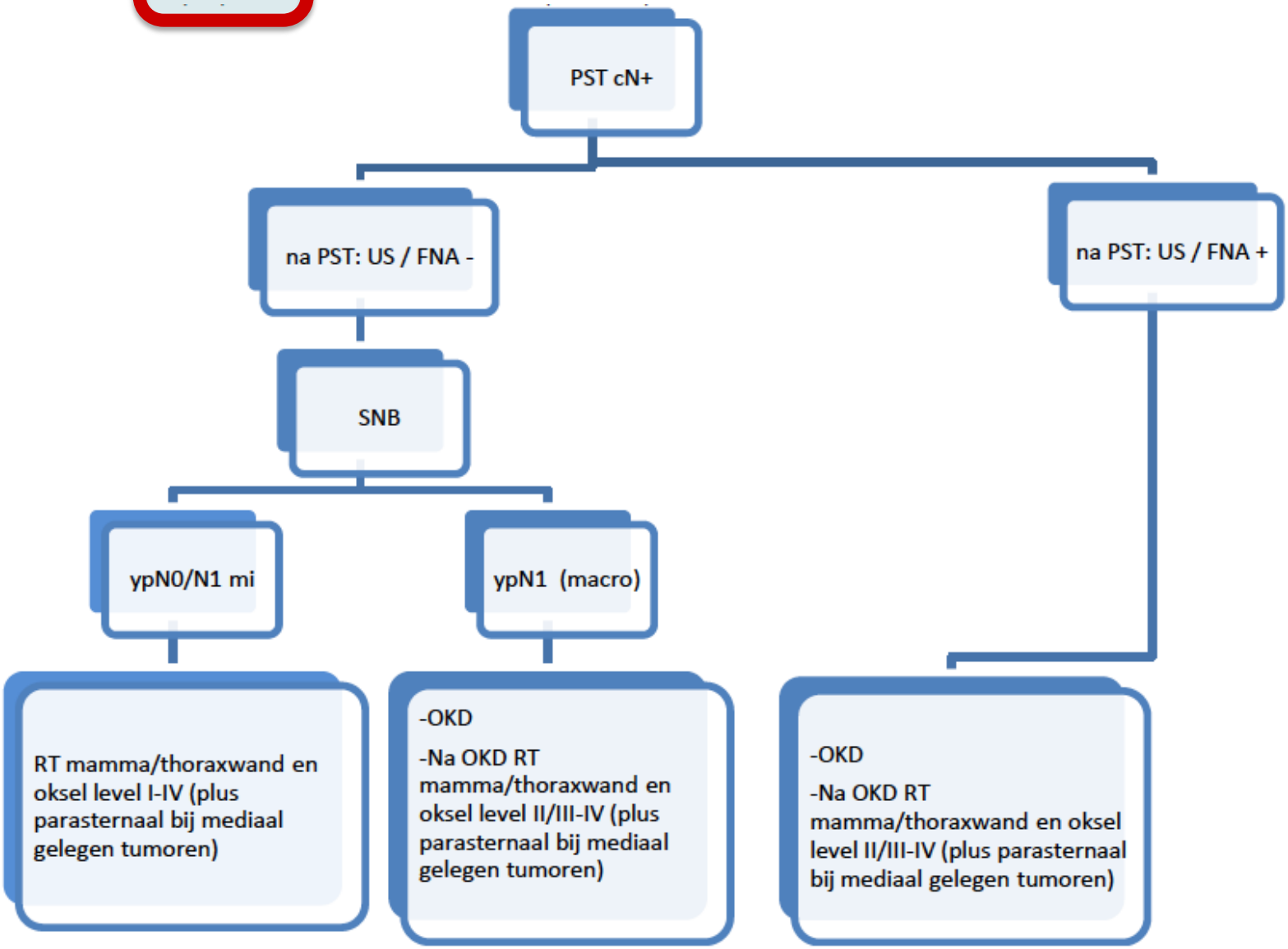

Protocol Radboud umc, March 2016.

Radboudumc

Locally advanced breast cancer: radiation therapy

1. Introduction
2. Current evidence
3. A technical radiation oncology note
4. How to proceed
5. Conclusions

Radiation therapy for LABC: conclusions

- Initial staging, especially the LN, should guide the decision
- SLNB pre-PST = more info … but relevance depends on protocol
- T3-T4 N2-N3 ➔ RT
- T1-T2 with pN0 after PST ➔ doubts

Tools to individualise:

- Pre-PST stage incl histology; VI; molecular profile; …
- Response to PST
- Age
- Pre-PST consult by radiation oncologist including T-scan!!!!

Radiation therapy for LABC: conclusions

Interaction systemic and locoregional treatments

RT & survival:

➔ X interaction with surgery and systemic treatment

↓ risk for death < M+ ➔ ↑ importance of LC

➔ earlier stage BC

➔ improved systemic therapy ➔ ***also when stage IV?***

An individualised case…

Case NJO

- Born in 1976
- Menarche 13; G1P1A0 (28); premenopausal
- Nurse (home care), never smoked, family -
- Medical history: congenital cardiac valve insufficiency; scoliosis; urethral valves; volume left breast was always > right breast

An individualised case…

Case NJO *(born 1976)*

- Age = 30: lump left breast upper inner quadrant
- GP ➔ mammography/ultrasound: not suspect
- Planned follow up after 3 months: progression on ultrasound!

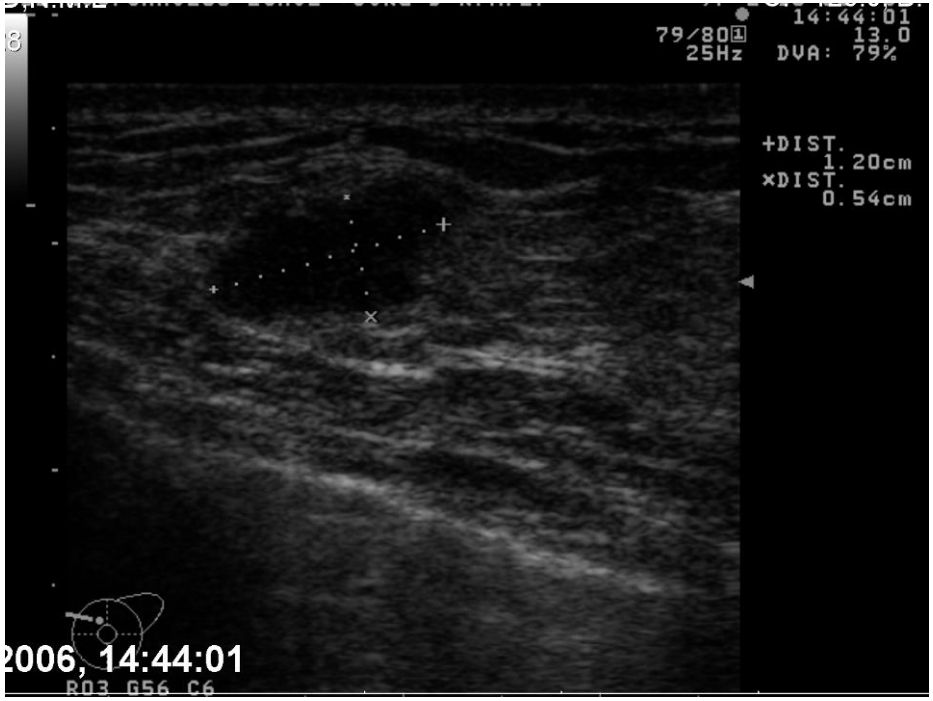

16.02.2006: not suspicious 12 x 5 mm

➔ To be repeated in 3 months

11.05.2006: 20 x 8 mm

➔ biopsy!

An individualised case…

Case NJO *(born 1976)*

- Lumpectomy: 1.8 cm IDA; G3; triple negative; R1
- Re-excision &SN: no residual tumour; SN 1/1
- ALND: 2+/12 (total 3/13)

2nd opinion ➔ RT first

- Breast + boost (refused YBT)
- Regional RT then not indicated (2006)

An individualised case…

Case NJO *(born 1976)*

- August 2006, end of RT: LN supraclavicular!

Back to place of 2nd opinion

- CT-scan; PET-scan: (only) N+:
  - Supraclavicular; aortic arch; subcarinal; infraclavicular/top axilla
  - Error in reporting ~ specific anatomy
  - Everything left side except suspicious upper mediastinal LN

An individualised case…

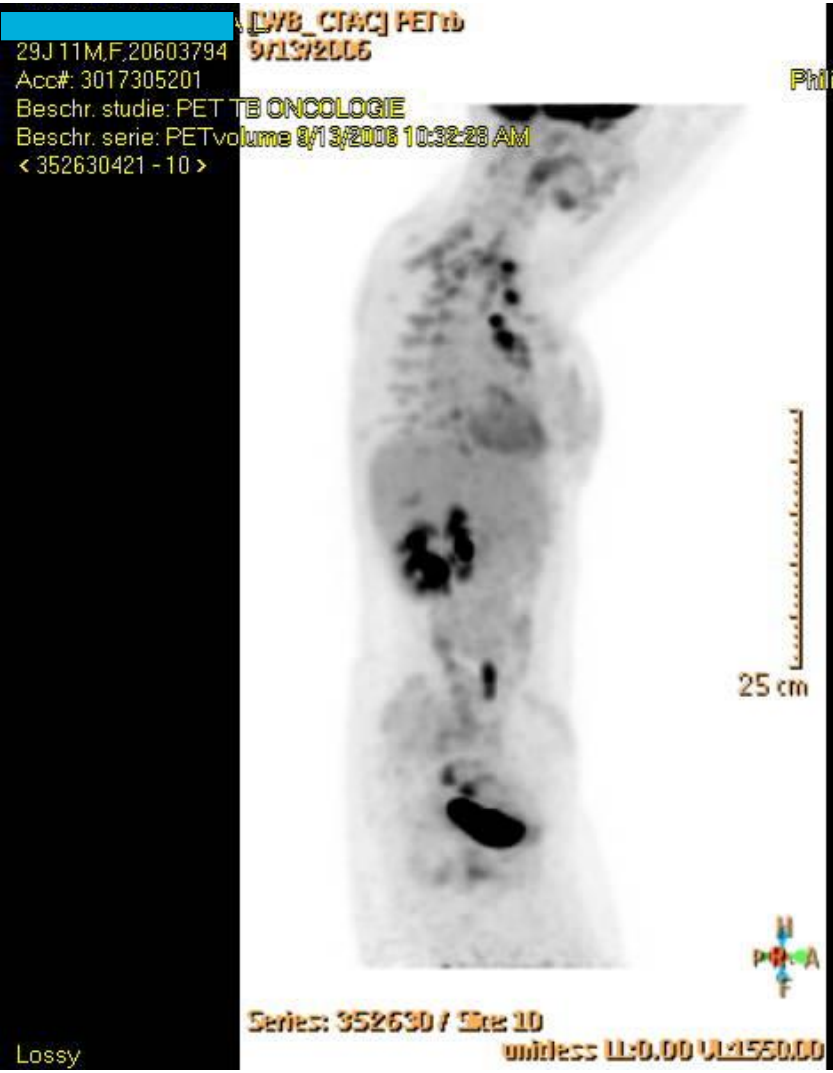

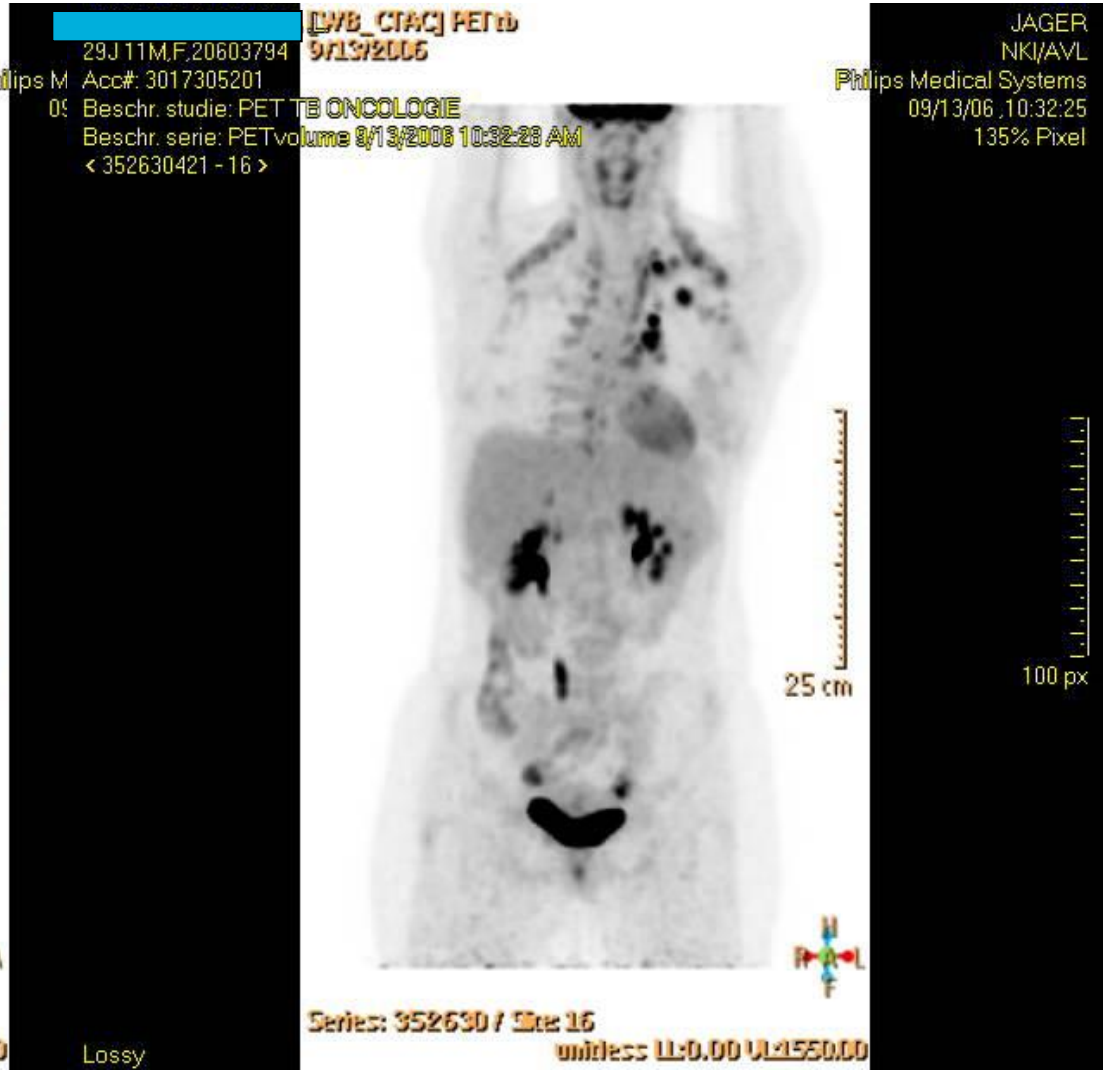

An individualised case…

Case NJO *(born 1976)*

At place of 2nd opinion

- Dose-dense chemotherapy (AC)
- Clinical complete remission after 3 cycles
- No 6th cycle ~ toxicity: leucopoenia; anal fissure; abscess sphenoid sinus

An individualised case…

Case NJO *(born 1976)*

Referred from place of 2nd opinion for

- Consolidating 3D-CRT 45-50 Gy/25 sessions on all PET + spots

An individualised case…

Second radiotherapy

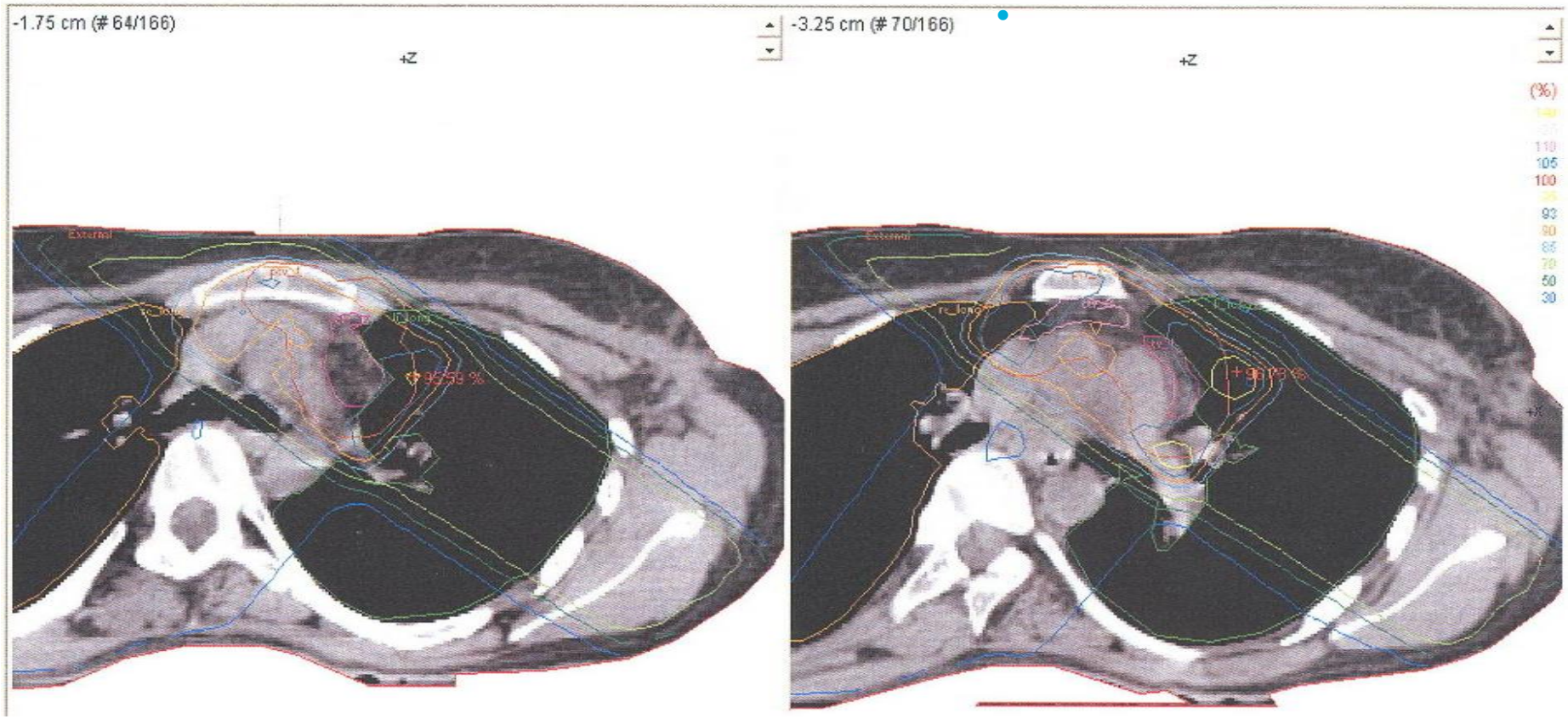

An individualised case…

Second radiotherapy

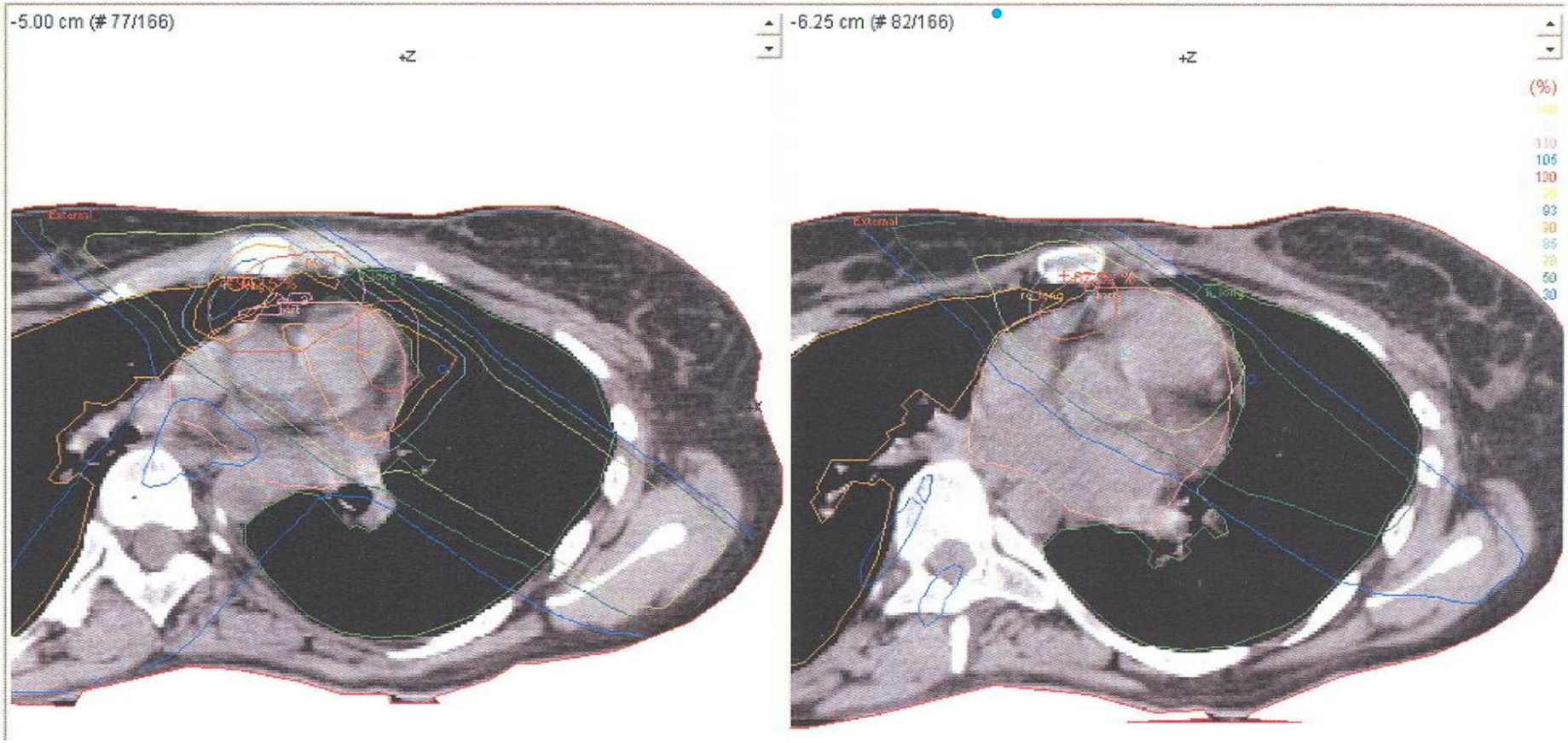

An individualised case…

Combined plan (first + second)

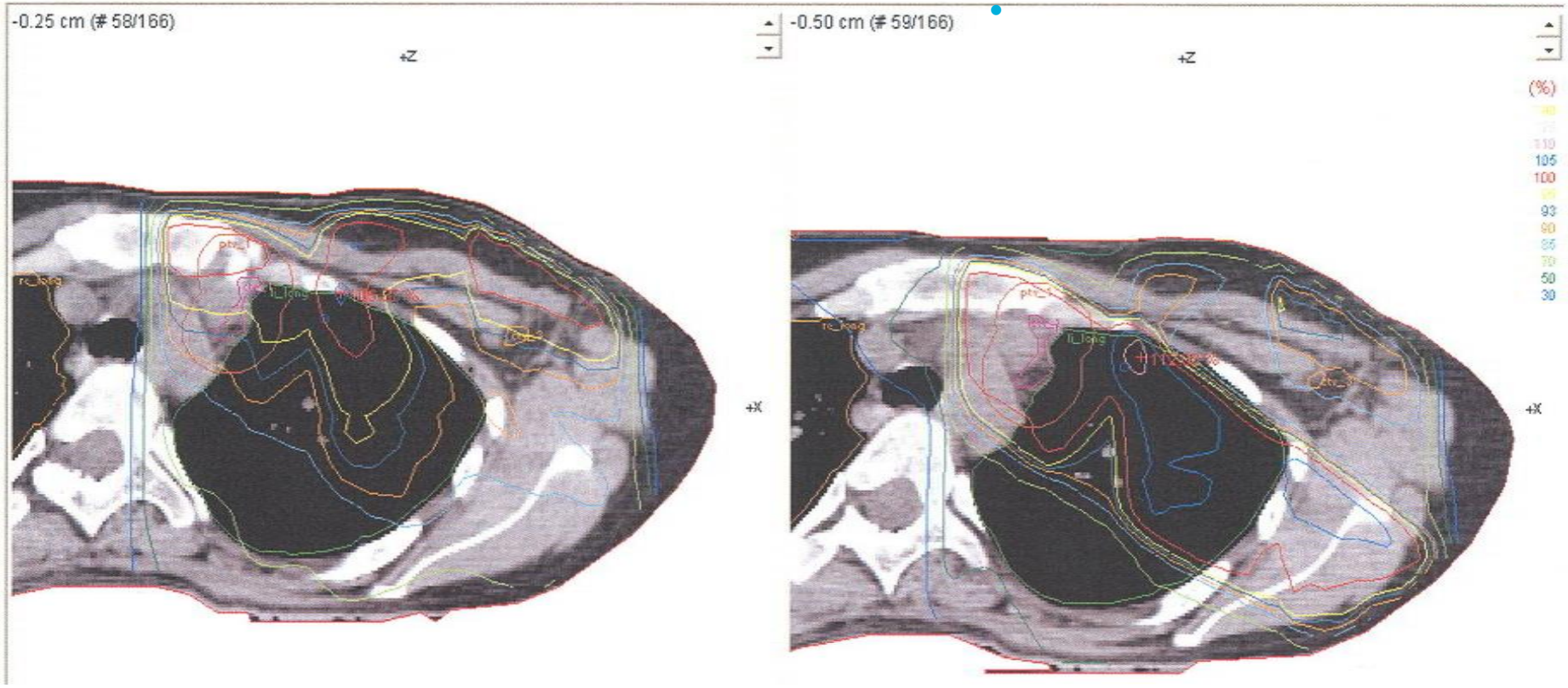

An individualised case…

Combined plan (first + second)

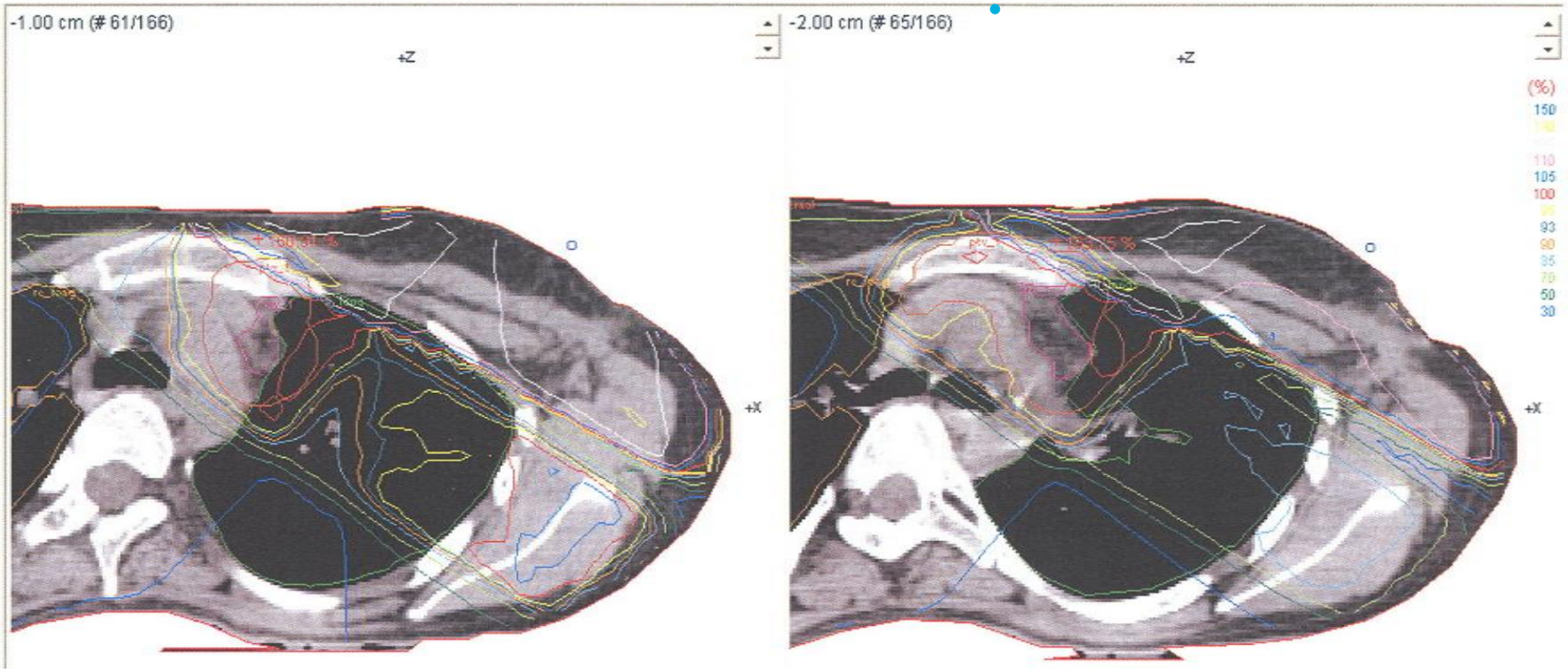

An individualised case…

Combined plan (first + second)

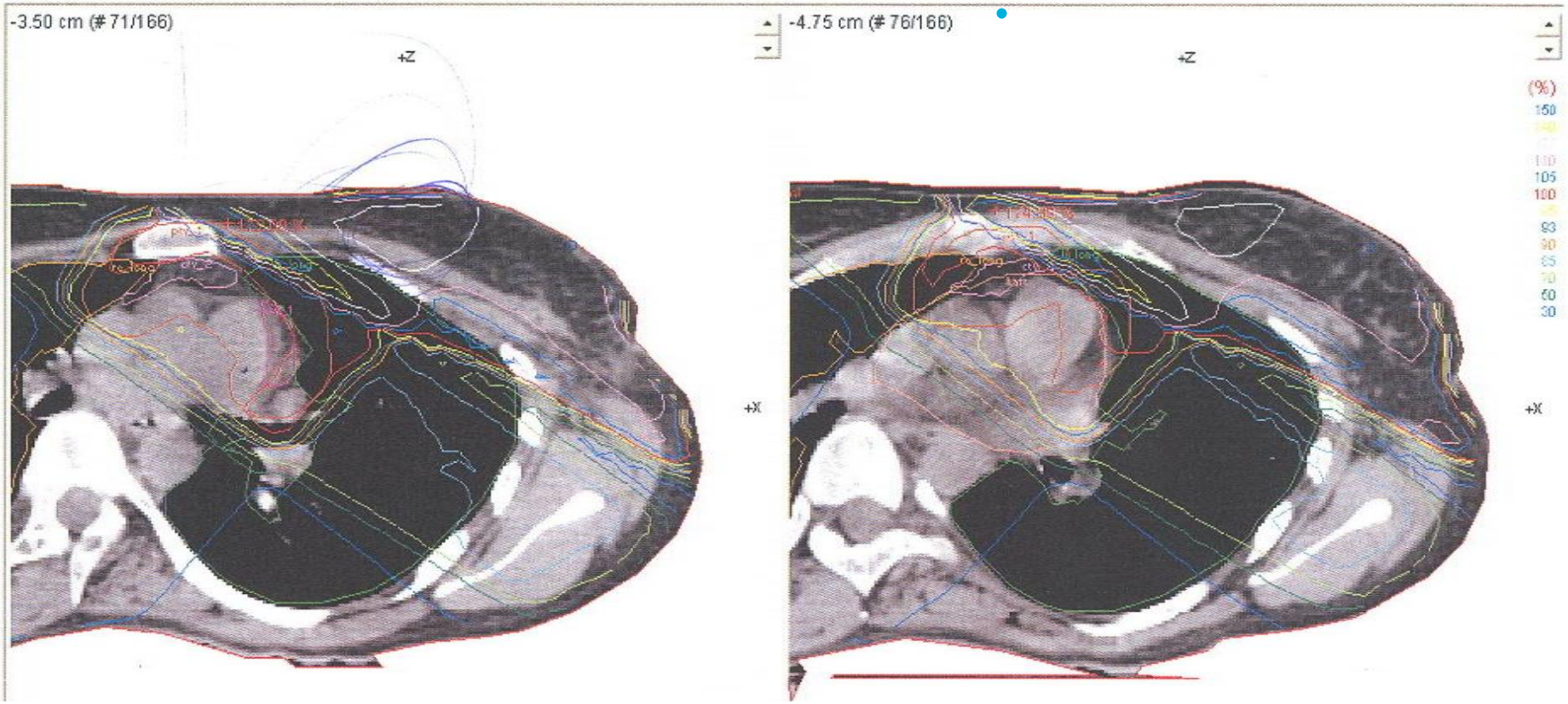

An individualised case…

totaalplan
mamma 2006
+
Elieren 2007

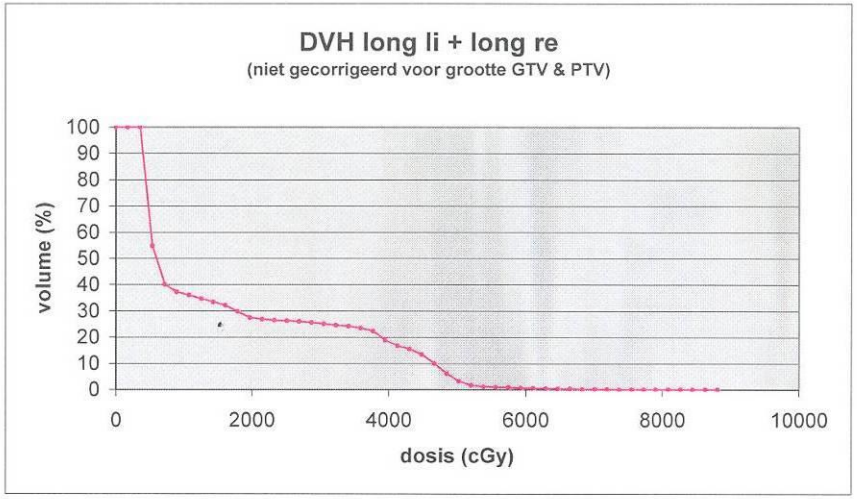

voorgeschreven dosis	5000	cGy
overlap volume PTV met linker long	0	cc
overlap volume GTV met linker long	0	cc
totaal volume linker long	964	cc
V20 links	540.88	cc
overlap volume PTV met rechter long	0	cc
overlap volume GTV met rechter long	0	cc
totaal volume rechter long	1125	cc
V20 rechts	30.75	cc
gemiddelde longdosis rechter long	672	cGy
gemiddelde longdosis linker long	2784	cGy
gemiddelde longdosis (ongecorrigeerd)	1647	cGy
gemiddelde longdosis (gecorrigeerd voor GTV)	1647	cGy
gemiddelde longdosis (gecorrigeerd voor PTV)	1647	cGy

uitgangspunten voor correctie
Het GTV krijgt tenminste de voorgeschreven dosis
Het PTV krijgt tenminste 20Gy

Combined plan (first + second)

totaal longvolume	2089	cc	(Va)
V20 (ongecorrigeerd)	572	cc	(Va20)
V20 (ongecorrigeerd)	27.4%		(Va20)
V20 (gecorrigeerd voor GTV)	27.4%		(V20)
V20 (gecorrigeerd voor PTV)	27.4%		(V20)

An individualised case…

Case NJO *(born 1976)*

Alternating FU with place of 2nd opinion

An individualised case…

Case NJO *(born 1976)*

Alternating FU with place of 2nd opinion

- 3 years later: NED
  - Free fat transplants to “fill” volume defect in PTB
  - Pregnant ➔ prosperous delivery of a son!

An individualised case…

Case NJO *(born 1976)*

Alternating FU with place of 2nd opinion

- 3 years later: NED
  - Free fat transplants to “fill” volume defect in PTB
  - Pregnant ➔ prosperous delivery of a son!
- > 9 years later: NED

Radiation therapy for LABC: acknowledgements

Angel Montero Luis

Meritxell Arenas Prat

Harry Bartelink

Paula Elkhuizen

Yazid Belkacemi


Radboudumc