

**Amiran Matitashvili M.D.**

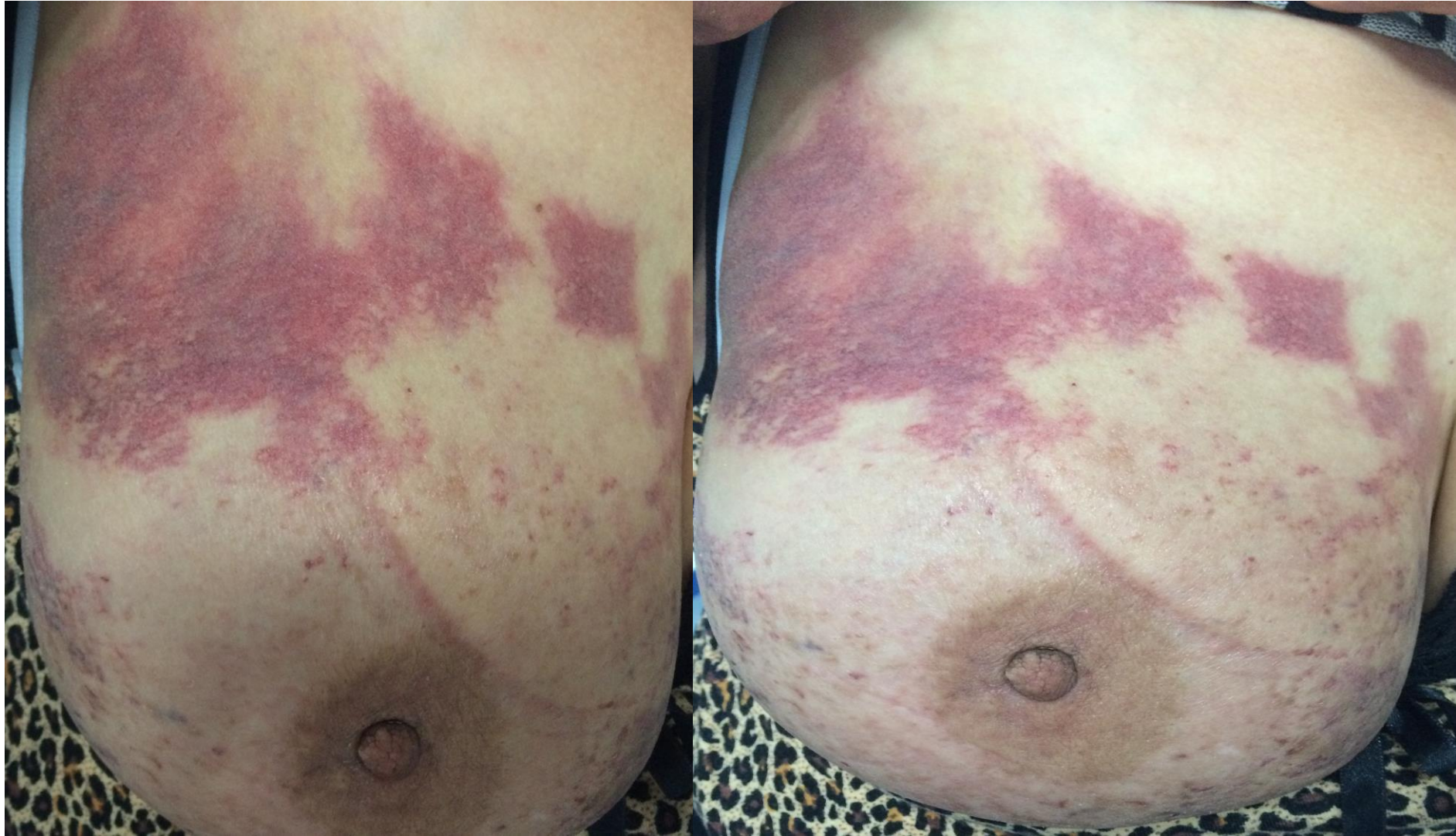**MARDALEISHVILI CANCER RESEARCH CENTRE**

# **Neo-adjuvant treatment of locally advanced Breast Cancer**

# Initial Presentation

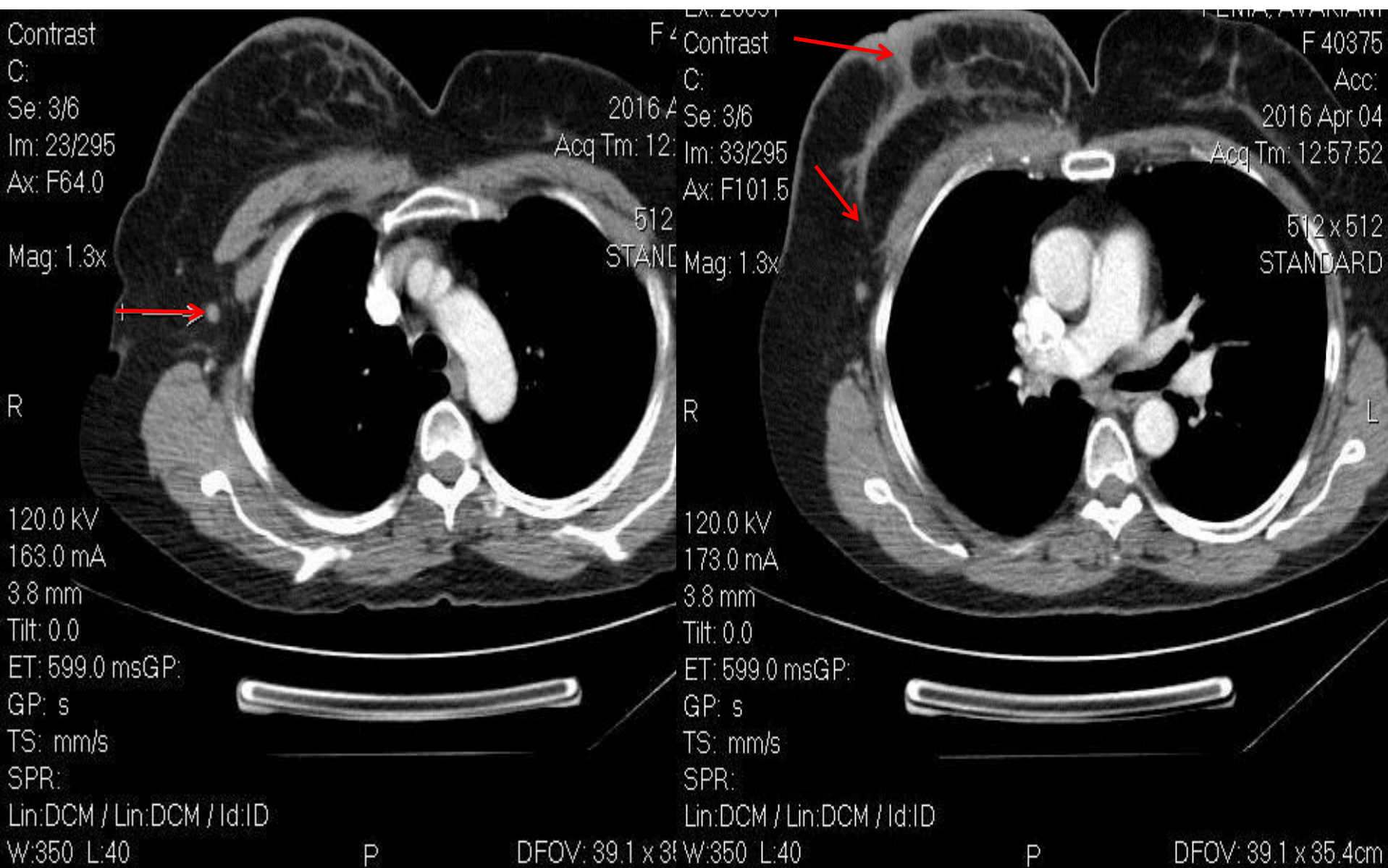
- ◉ Female patient 59 y old
- ◉ No comorbidities
- ◉ From Her past Medical Records was revealed that in February 2016 patient was diagnosed with **Right Inflammatory Breast Cancer cT4N1M0 IIIB stage. ER/PR(negative) Her2/neu (3+) and she had already received 3 cycles of chemotherapy AC regimen.**

# Images at Presentation

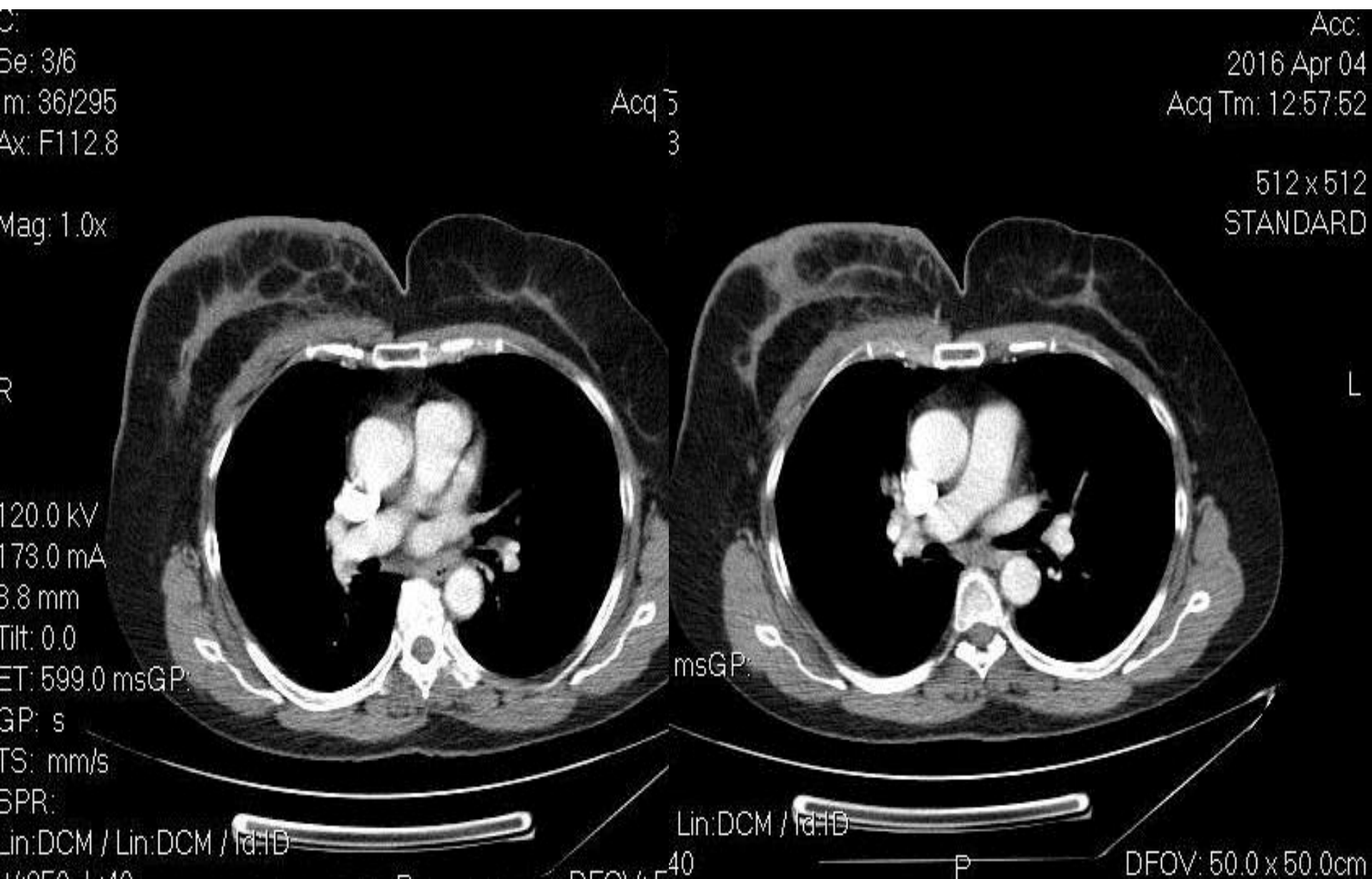




# CT images



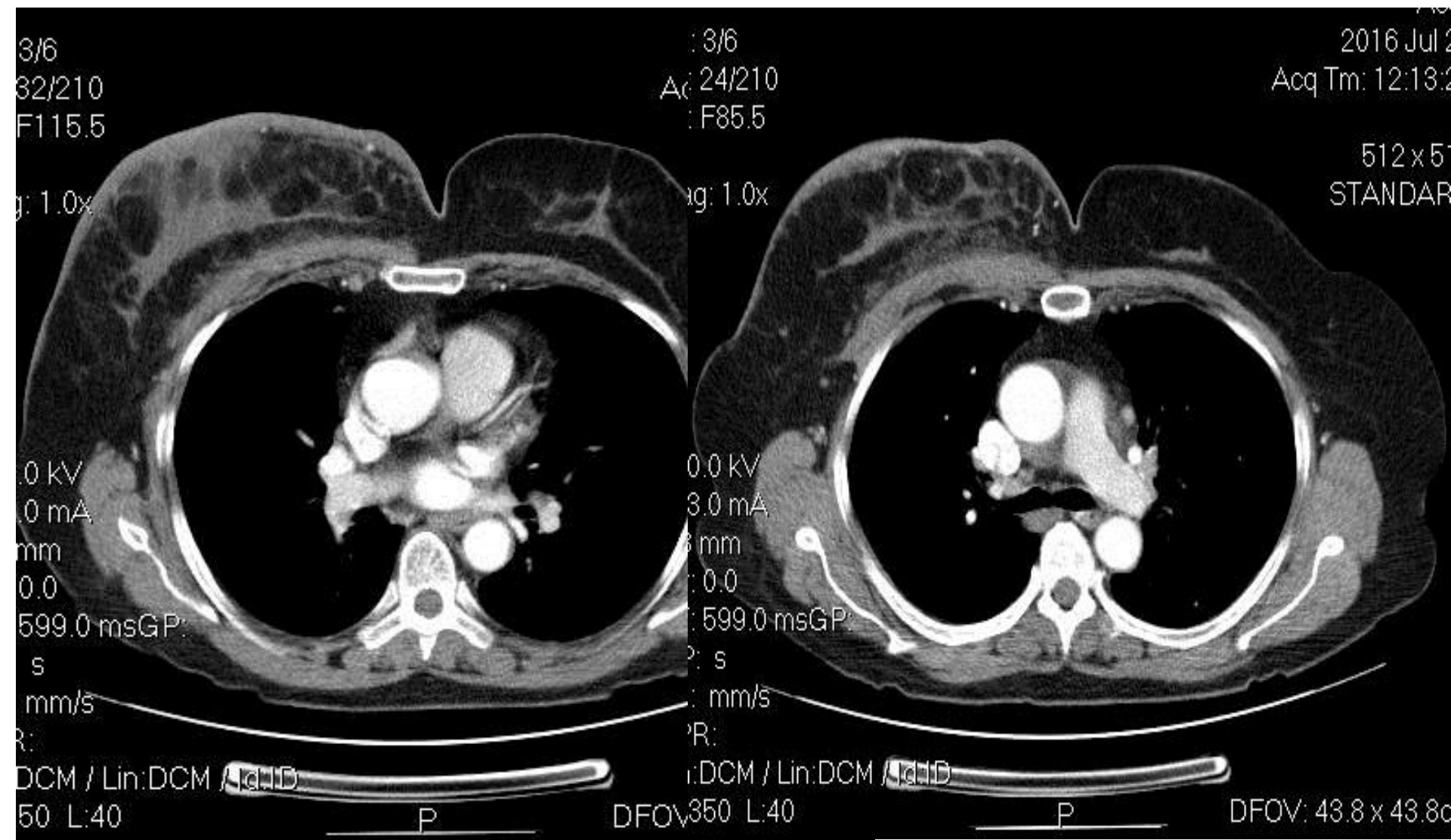
# CT images



# Neo Adjuvant Treatment

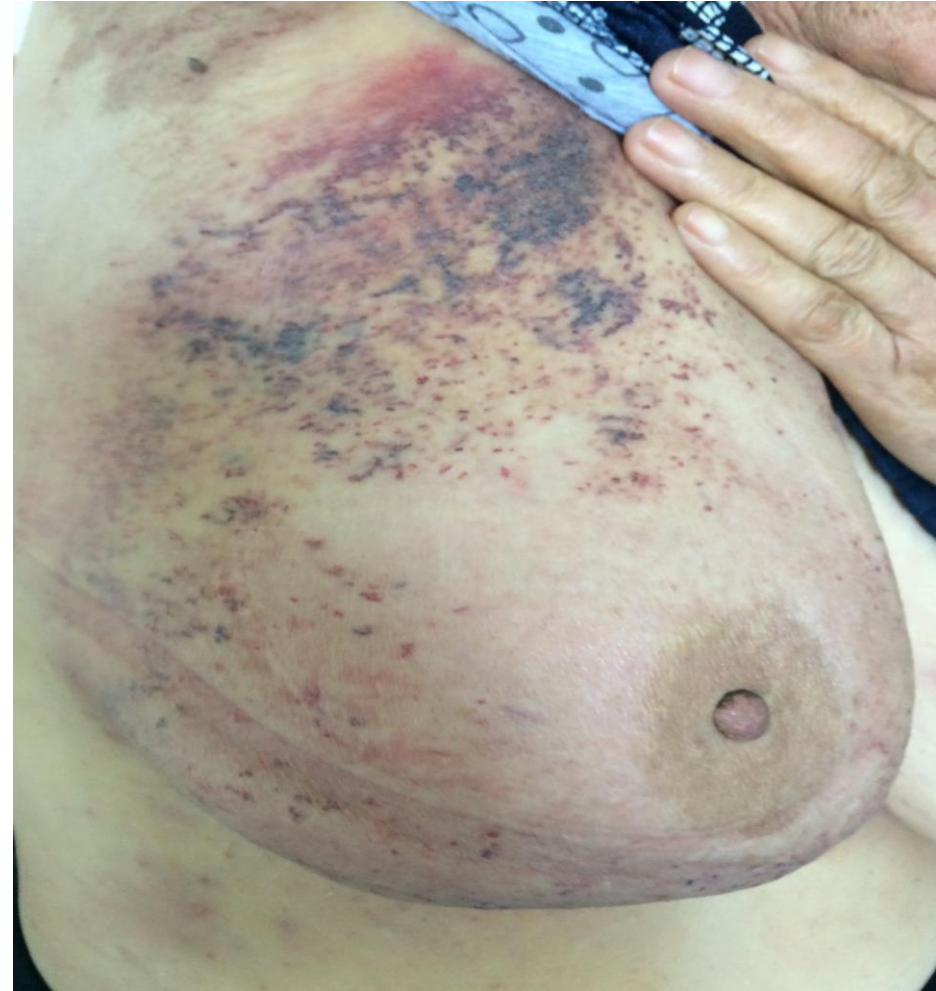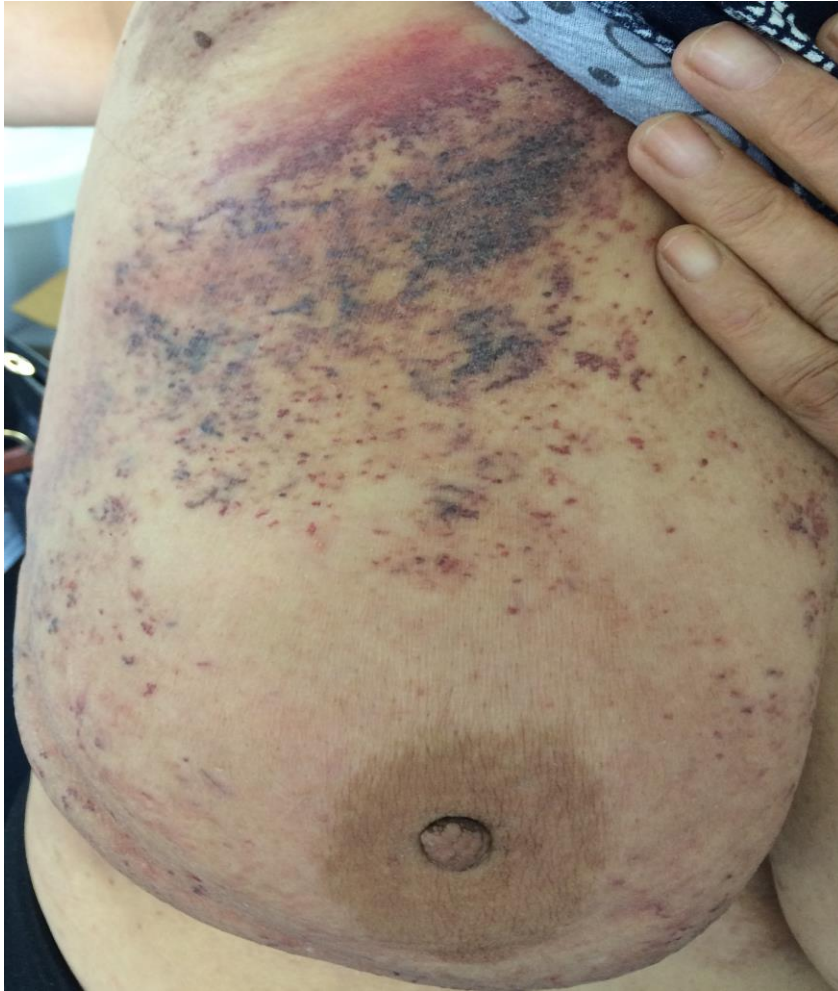- After extensive discussion with patient and her family we decided to continue treatment with neo adjuvant regime. (was done 4<sup>th</sup> cycle of AC chemotherapy)
- 06/05/2016 – 12/07/2016 Performed neo-adjuvant chemotherapy and Her 2 targeted therapy with :  
**Docetaxel 75mg/m<sup>2</sup> (135mg) and initial dose Herceptin 8mg/kg(640mg) and then 6mg/kg(440mg )plus initial dose Perjeta 840 mg and then 420mg every three week interval.**

# After Neo –Adjuvant Treatment





# Clinical Presentation after Neo Adjuvant treatment - Patient received additional 2 cycles of Trastuzumab every three week interval after she finished chemotherapy cycle





# What would be the next best Treatment option

- ⦿ **Surgery**
- ⦿ **RT**
- ⦿ **Chemotherapy plus Anti Her agents**