Atezolizumab and severe cutaneous adverse reactions: data mining of the FDA Adverse Event Reporting System (FAERS) database

1862P

Alessandro Pecere [1], Giulia Carlotta Bisinella [2]

[1] Department of Pharmaceutical Science, Università degli Studi di Milano, Milano, Italy

[2] Department of Physiology and Pharmacology, Università degli Studi di Roma "La Sapienza", Roma, Italy

2021 ESMO congress

16-21 SEPTEMBER 2021

Background

Atezolizumab is a humanized IgG1 monoclonal antibody that targets PD-L1, used in different kinds of advanced carcinoma including metastatic non-small cell lung cancer.

Recently, a warning has been issued by the European Medicine Agency regarding the risk of Steven-Johnson syndrome (SJS) and toxic epidermal necrolysis (TEN) in patients treated with atezolizumab.

SJS and TEN, along with acute generalized exanthematous pustulosis (AGEP) and drug reaction with eosinophilia and systemic symptoms (DRESS), are classified as severe cutaneous adverse reactions to drugs (SCARs).

The aim of this study was to investigate whether a disproportionally elevated signal of developing SCARs may be detected in patients treated with atezolizumab as compared to those treated with other drugs.

Methods

A retrospective analysis of spontaneously reported cases of SCARs contained in the free and publicly available database FDA Adverse Event Reporting System (FAERS) was conducted in the period 2014-2020.

As a signal of disproportionality, we calculated the reporting odds ratio (ROR) and the relative 95% confidence interval (CI) of SCARs in patients treated with atezolizumab.

The signal was considered significant when the ROR lower limit of the 95% CI was > 1.

Results

There were 36 reports of SCARs in patients treated with atezolizumab: 25 SJS, 3 DRESS, 7 TEN and 1 AGEP, respectively.

The majority of these reports referred to patients aged 68-85 years (47.06%) and female (58.82%).

A significant signal was only detected for SJS: ROR = 4.74; 95% CI 3.20-7.03.

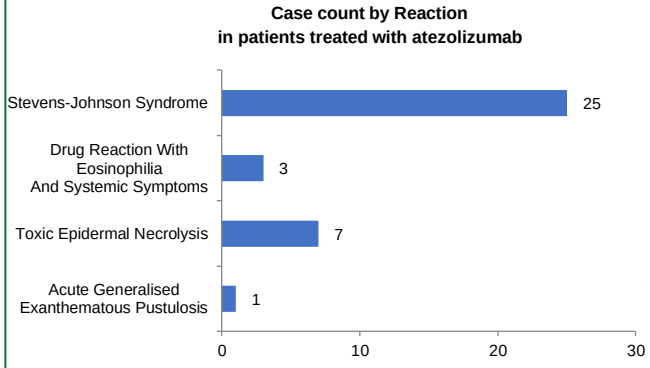

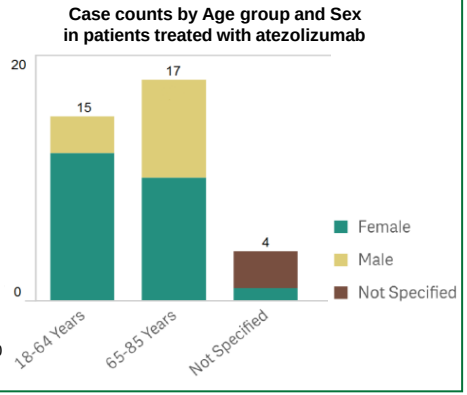

Conclusions

With this study we demonstrated that in patients treated with atezolizumab, SJS was the only SCAR for which a signal of disproportionate reporting was detected.

In order to find any discrepancies, it would be of interest to further analyze reports of SCARs associated with the use of atezolizumab, comparing signals deriving from FAERS and those deriving from the European pharmacovigilance database EudraVigilance.

Authors declare no conflict of interests