

Clinical challenges in neuro-oncology



# **Brain Metastases: (When & How) To Treat or not to Treat**

Yoko Nakasu, MD  
Division of Neurosurgery  
Shizuoka Cancer Centre, Japan

ESMO Asia Singapore 18/12/2015

# Disclosure

No conflict of interest

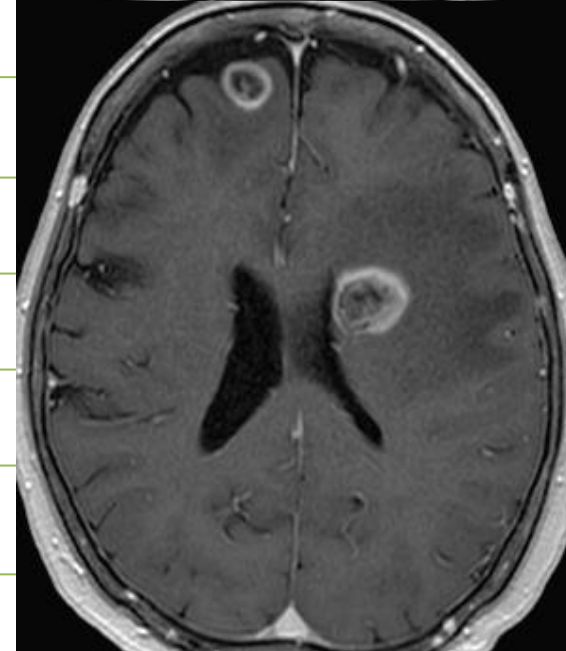
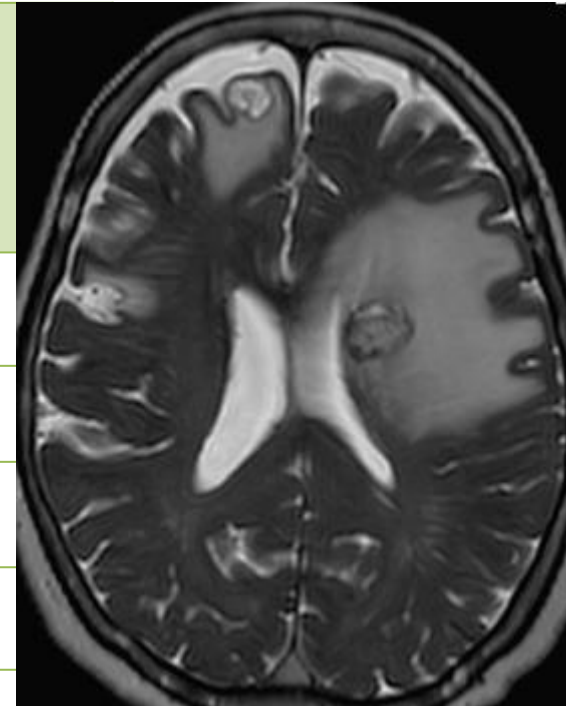
**Brain Metastases:**  
(When & How) To Treat or not to Treat

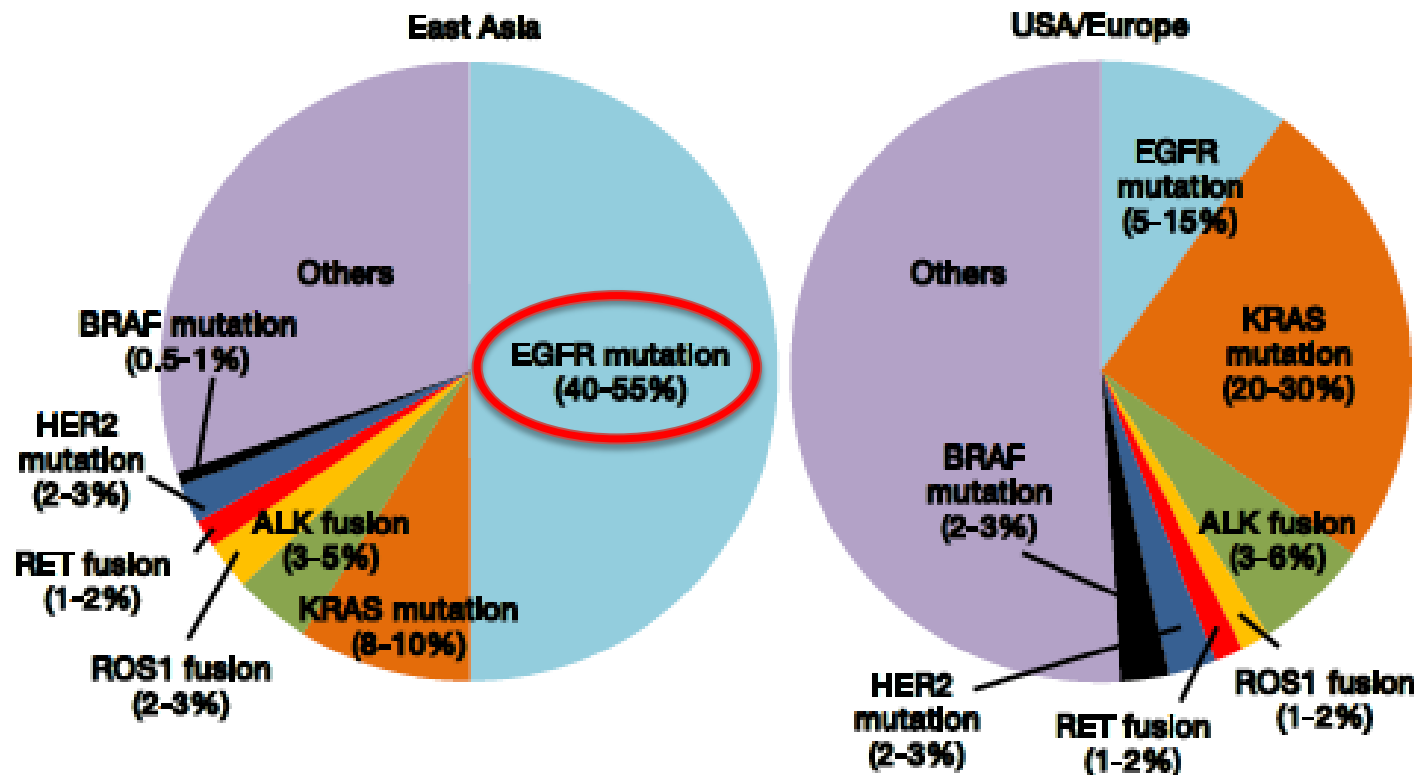
Yoko Nakasu, MD

Division of Neurosurgery

Shizuoka Cancer Centre, Japan

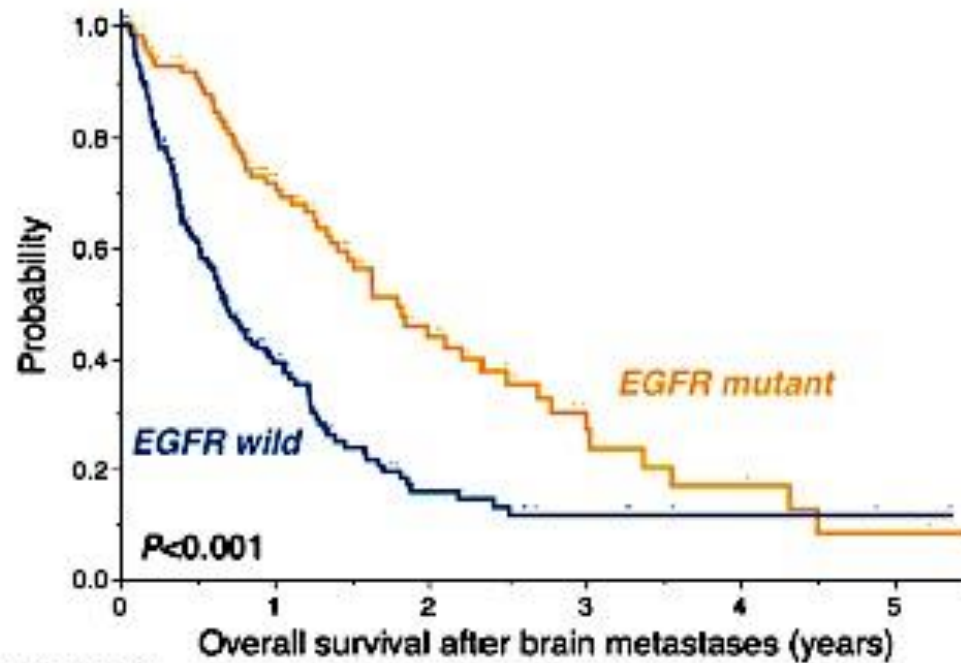
<b>Case 1</b>	<b>NSCLC Adenocarcinoma</b>
<b>70 y.o.</b>	<b>T1N2M0 EGFR mutation +</b>
<b>Woman</b>	<b>No complication</b>
July/200X	Lung lobectomy
Oct/200X	Systemic=CR, CSN=PD single <b>GKS</b>
Aug/200Y	Systemic=PD (lung, adrenal)
Sep/200Y	<b>CBDCA+paclitaxel ~ Gefitinib</b>
Mar/201Z	Systemic=PD <b>Erlotinib</b>
Sep/201Z	Systemic=PD, to Hospice
Nov/201Z	CNS=PD Aphasia
<b>(How) to treat?</b>	





## Beyond *ALK-RET*, *ROS1* and other oncogene fusions in lung cancer

Takashi Kohno<sup>1,2,3</sup>, Takashi Nakaoku<sup>1</sup>, Koji Tsuta<sup>4</sup>, Katsuya Tsuchihara<sup>2</sup>, Shingo Matsumoto<sup>2,3</sup>, Kiyotaka Yoh<sup>3</sup>, Koichi Goto<sup>3</sup>



<b>EGFR mutant</b>						
n 104	58	24	10	6	3	
Events 0	27	18	7	3	2	
<b>EGFR wild</b>						
n 157	43	13	6	3	2	
Events 0	24	22	2	0	0	

Int J Clin Oncol (2015) 20:674–679  
 DOI 10.1007/s10147-014-0760-9

ORIGINAL ARTICLE

## Frequency of brain metastases in non-small-cell lung cancer, and their association with epidermal growth factor receptor mutations

Toshihiko Iuchi · Masato Shingyoji · Meiji Itakura · Sana Yokoi · Yasumitsu Moriya · Hajime Tamura · Yasushi Yoshida · Hironori Ashinuma · Koichiro Kawasaki · Yuzo Hasegawa · Tsukasa Sakaida · Toshihiko Iizasa

**Case 2**  
**42 y.o.**  
**Man**

**NSCLC Adc**  
**T1bN3M1b (Liver, Adrenal)**  
**Stage IV, EGFR- / ALK+**  
**No complication**

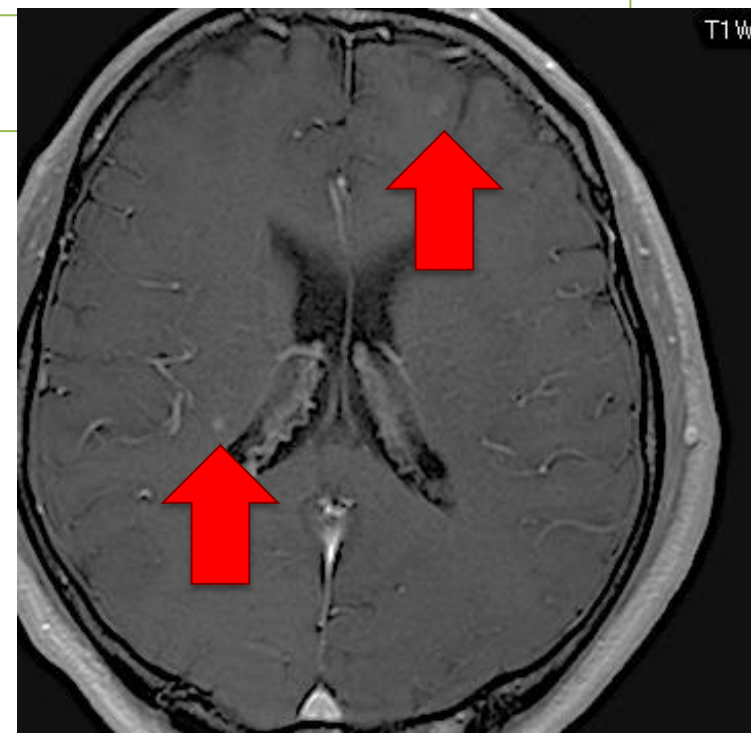
Mar/201X

**Crizotinib**

Jan/201Y

Systemic=PR,  
CSN=PD asymptomatic

(How) to treat?



**Case 2**  
**42 y.o.**  
**Man**

**NSCLC Adc**  
**T1bN3M1b (Liver, Adrenal)**  
**Stage IV, EGFR- / ALK+**  
**No complication**

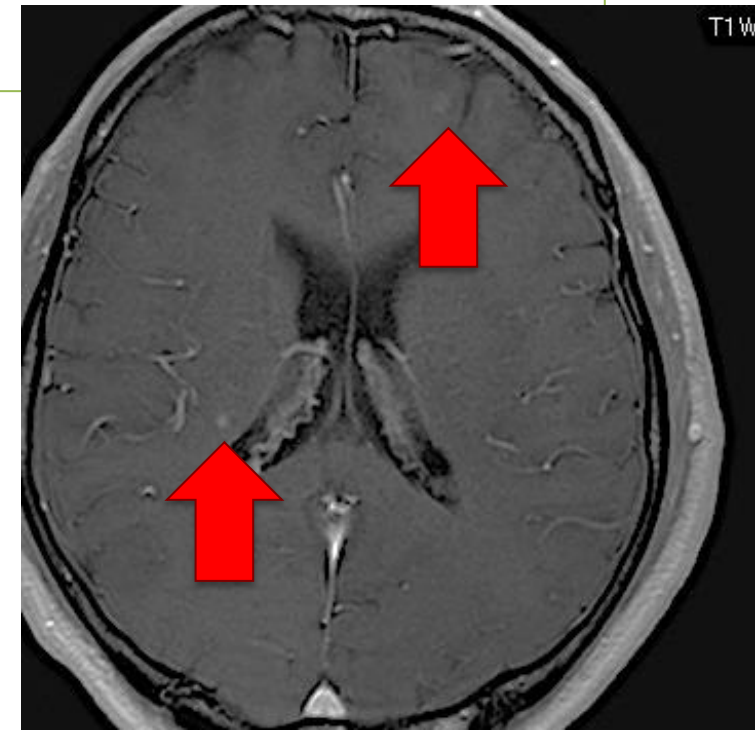
Mar/201X

**Crizotinib**

Jan/201Y

Systemic=PR,  
CSN=PD asymptomatic

**GKS**



**Case 2**  
**42 y.o.**  
**Man**

**NSCLC Adc**  
**T1bN3M1b (Liver, Adrenal)**  
**Stage IV, EGFR- / ALK+**  
**No complication**

Mar/201X

**Crizotinib**

Jan/201Y

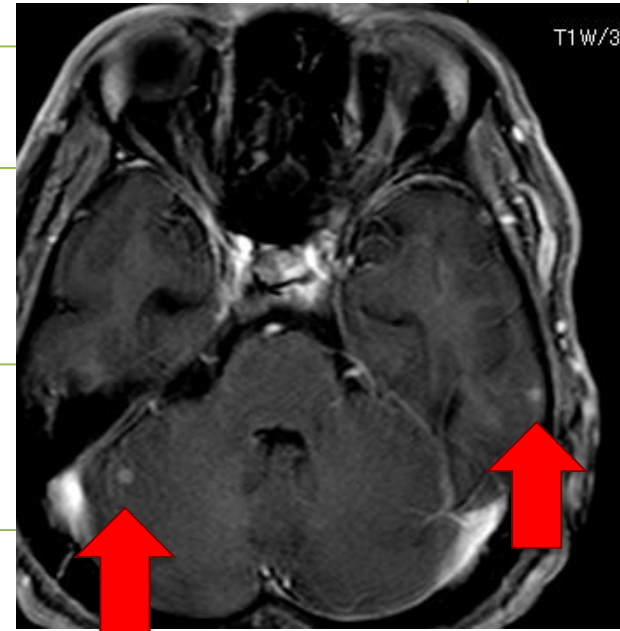
Systemic=PR,  
CSN=PD asymptomatic

**GKS**

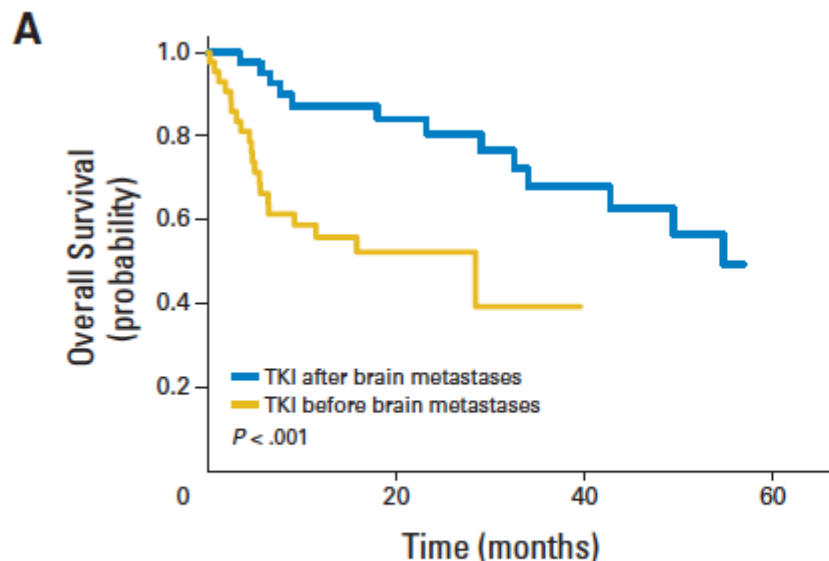
Mar/201Z

Systemic=PR,  
CSN=PD asymptomatic

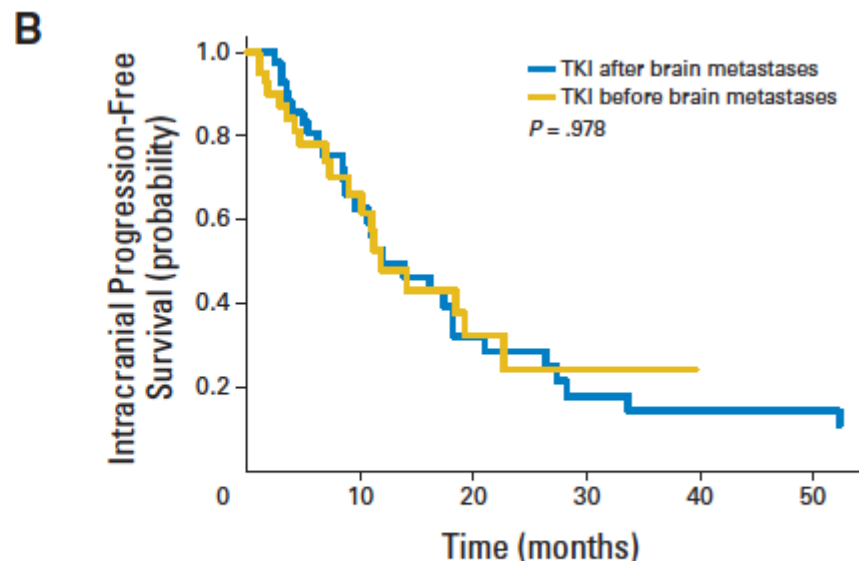
(How) to treat?







No. at risk	0	20	40	60
TKI after	46	25	14	4
TKI before	44	11	0	0



No. at risk	0	10	20	30	40	50
TKI after	45	19	9	5	4	4
TKI before	44	15	6	2	0	0

## Extended Survival and Prognostic Factors for Patients With *ALK*-Rearranged Non–Small-Cell Lung Cancer and Brain Metastasis

Kimberly L. Johung, Norman Yeh, Neil B. Desai, Terence M. Williams, Tim Lautenschlaeger, Nils D. Arvold, Matthew S. Ning, Albert Attia, Christine M. Lovly, Sarah Goldberg, Kathryn Beal, James B. Yu, Brian D. Kavanagh, Veronica L. Chiang, D. Ross Camidge, and Joseph N. Contessa

**Case 3**

**53 y.o.**

**Man**

**ED-SCLC**

**T1aN2M1b (cerebellum only, asymptomatic)**

**Stage IV**

**No complication**

Sep~Nov/201X

**CDDP+VP16**

Nov/201X

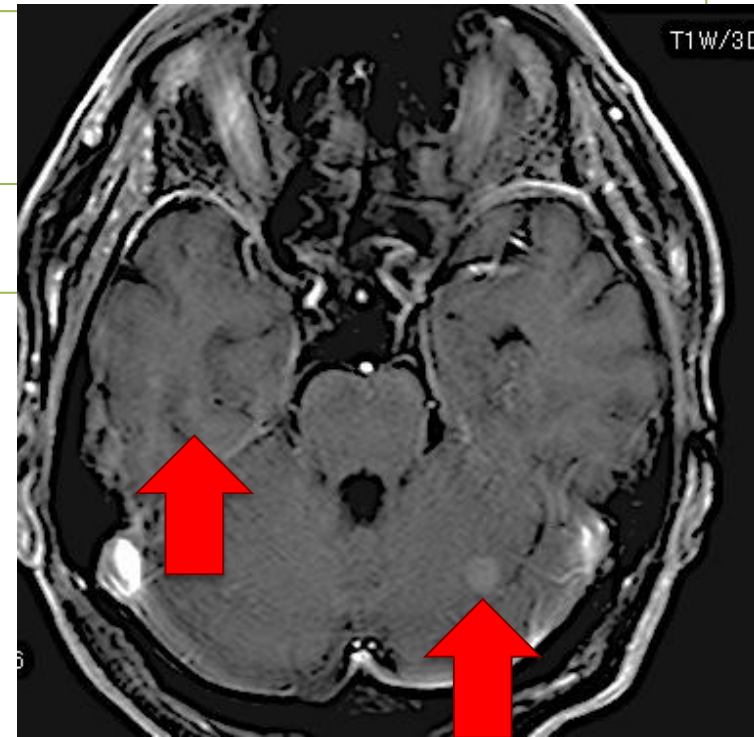
Systemic=PR, CNS=SD

Jan/201Y

CNS=PD

Asymptomatic

(How) to treat?



**Case 3**  
**53 y.o.**  
**Man**

**ED-SCLC**  
**T1aN2M1b (cerebellum only, asymptomatic),**  
**Stage IV**  
**No complication**

Sep~Nov/201X

**CDDP+VP16**

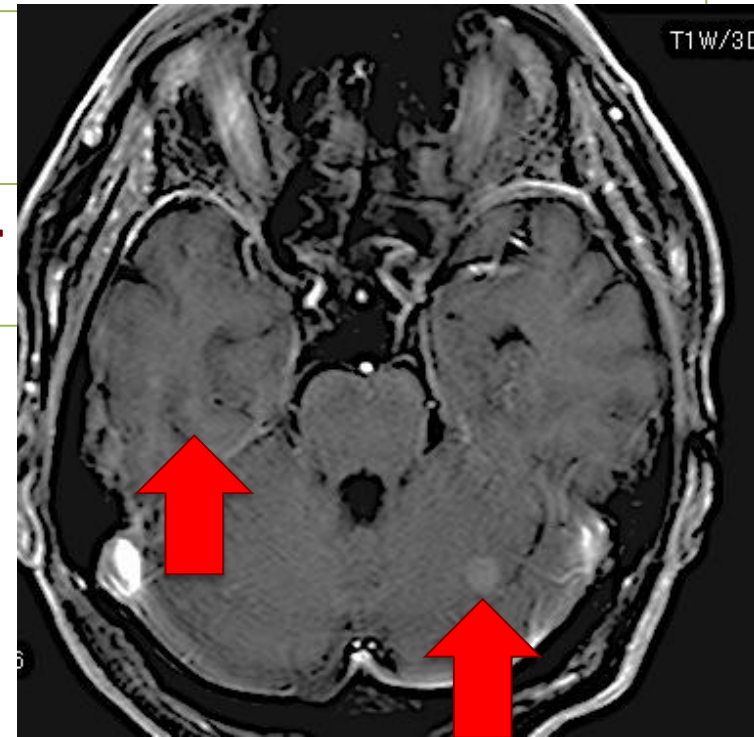
Nov/201X

Systemic=PR, CNS=SD

Jan/201Y

CNS=PD  
Asymptomatic

**WBRT 30Gy/10fr**



**Case 3**  
**53 y.o.**  
**Man**

**ED-SCLC**  
**T1aN2M1b (cerebellum only, asymptomatic)**  
**Stage IV**  
**No complication**

Sep~Nov/201X

**CDDP+VP16**

Nov/201X

Systemic=PR, CNS=SD

Jan/201Y

CNS=PD  
Asymptomatic

**WBRT 30Gy/10fr**

Mar/201Y

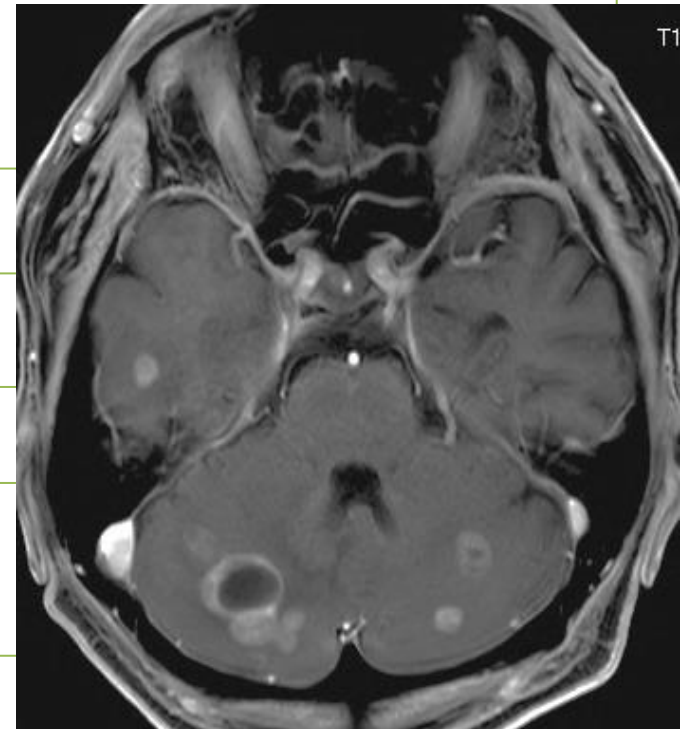
Systemic=PD

**AMR**

Oct/201Y

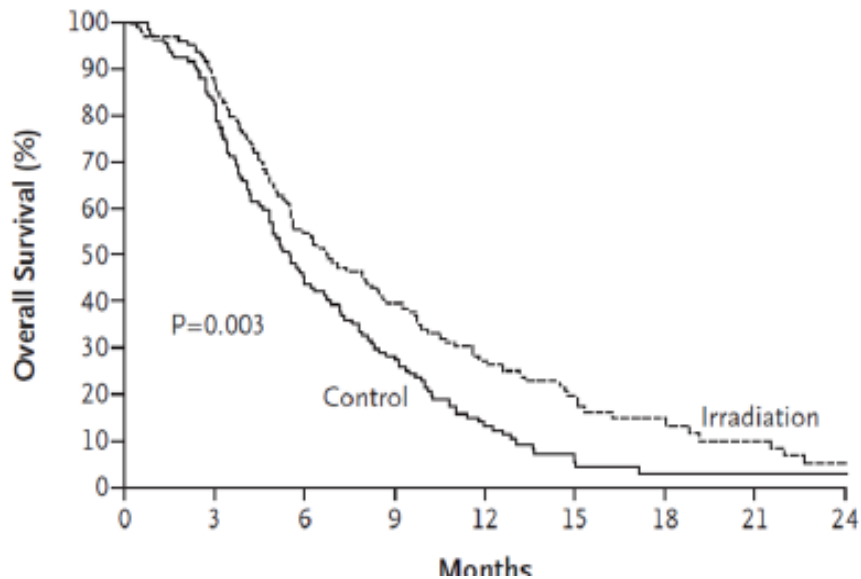
Systemic=PR  
CNS=PD

(How) to treat?



# PCI for ED-SCLC

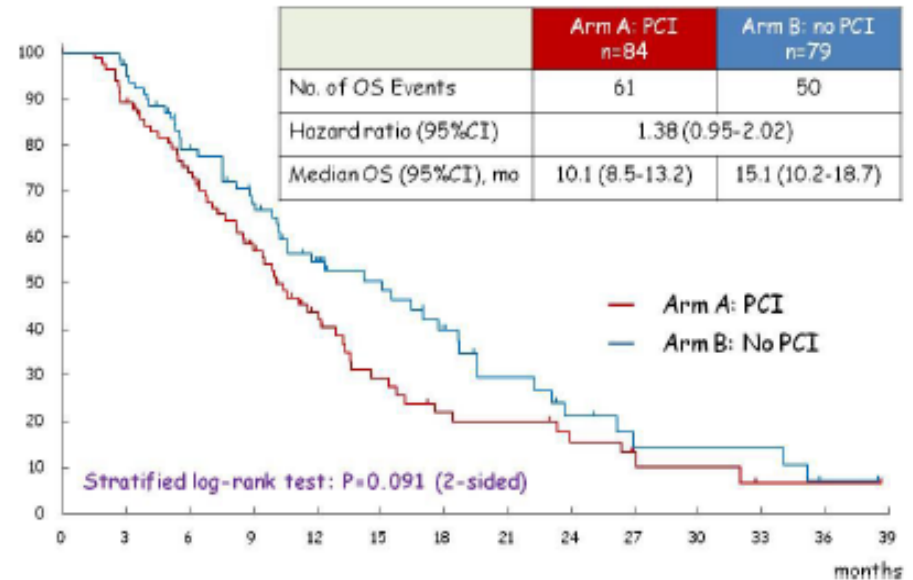
Slotman et al.  
NEJM 357:664, 2007.



Seto et al. ASCO 2015.



Overall Survival



**Case 4**  
**43 y.o.**  
**Woman**

**Uterus Cervix Small-cell carcinoma**  
**I B1, Stage IA, Class IV**  
**Gd allergy**

Dec/201X

Total removal of Uterus/Adnx

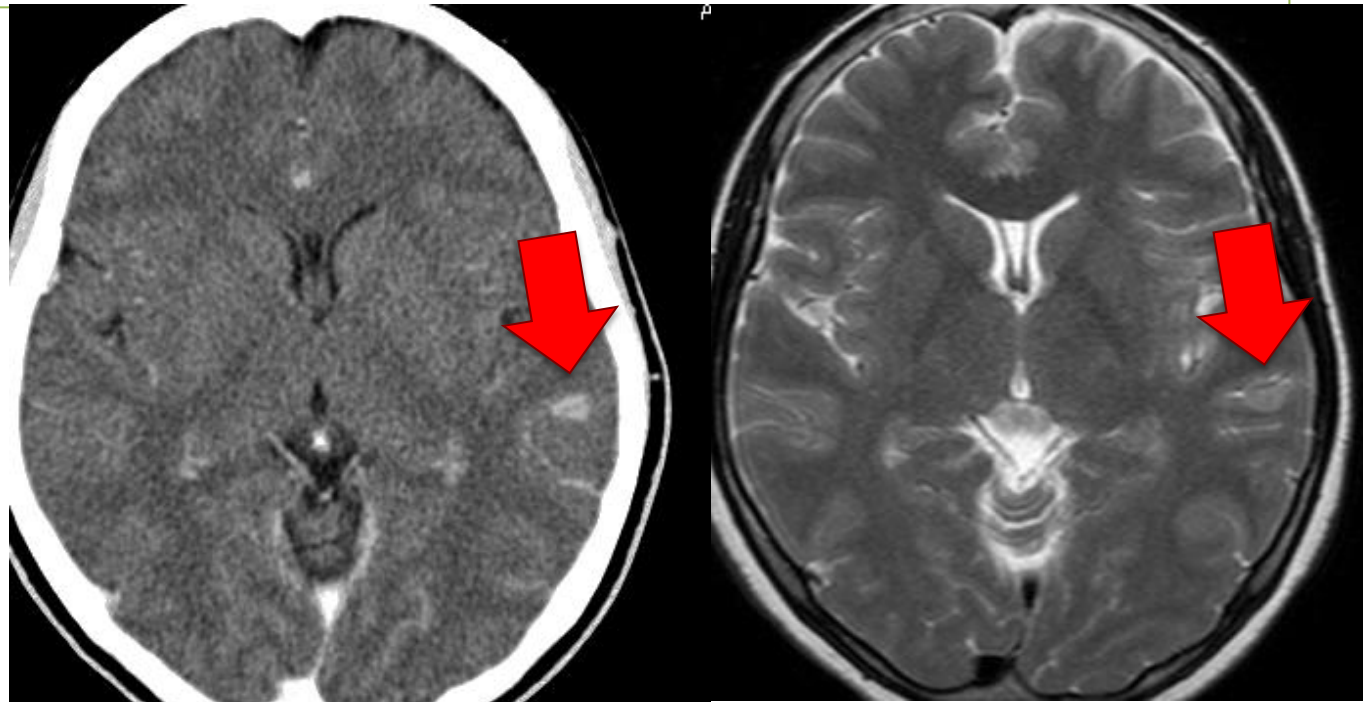
Jan~Jun/201Y

**EP**

Aug/201Z

Systemic=CR  
CNS=PD? headache

How to examine?



Case 4  
43 y.o.  
Woman

Uterus Cervix Small-cell carcinoma  
I B1, Stage IA, Class IV  
Gd allergy

Dec/201X

Total removal of uterus/adnx

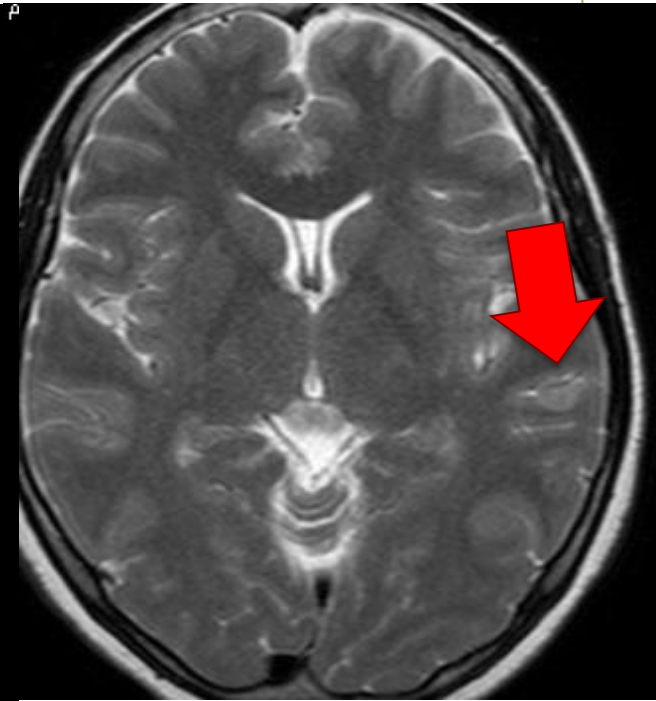
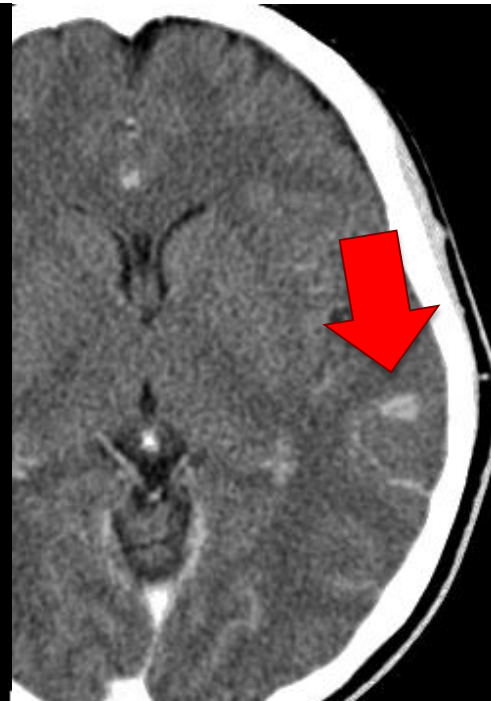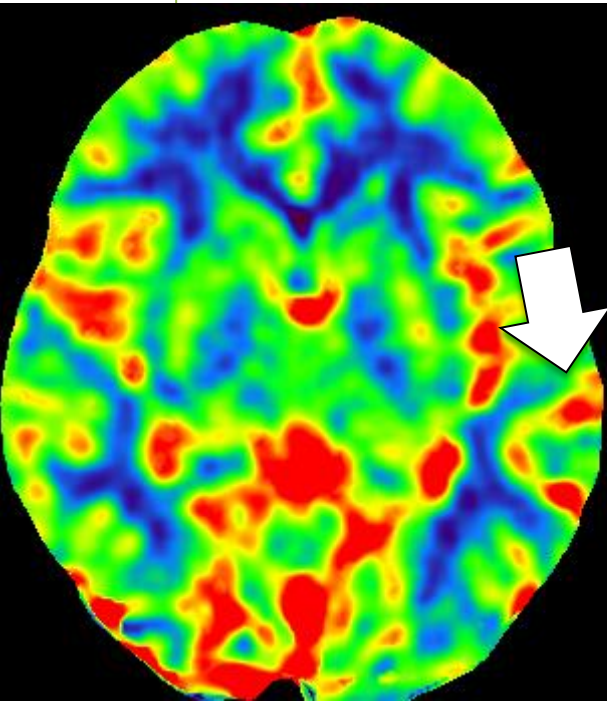
Jan~Jun/201Y

EP

Aug/201Z

Systemic=CR  
CNS=PD? headache

**pCT=CBV**



Case 4  
43 y.o.  
Woman

Uterus Cervix Small-cell carcinoma  
I B1, Stage IA, Class IV  
Gd allergy

Dec/201X

Total removal of Uterus/Adnx

Jan~Jun/201Y

EP

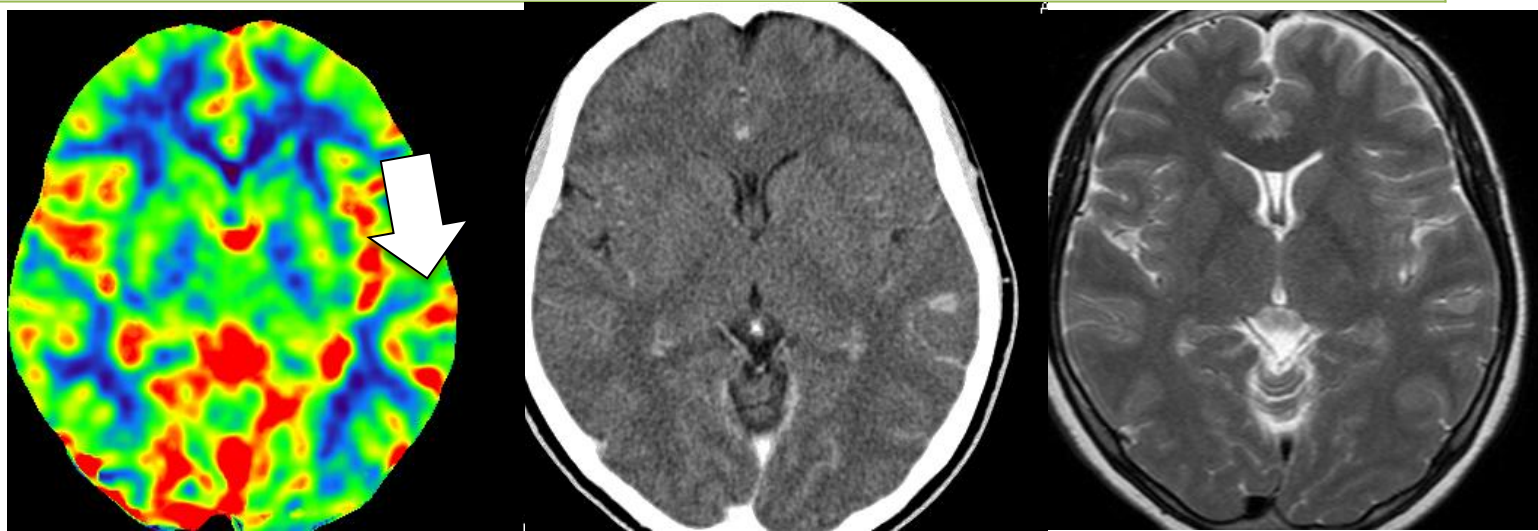Aug/201Z

Systemic=CR

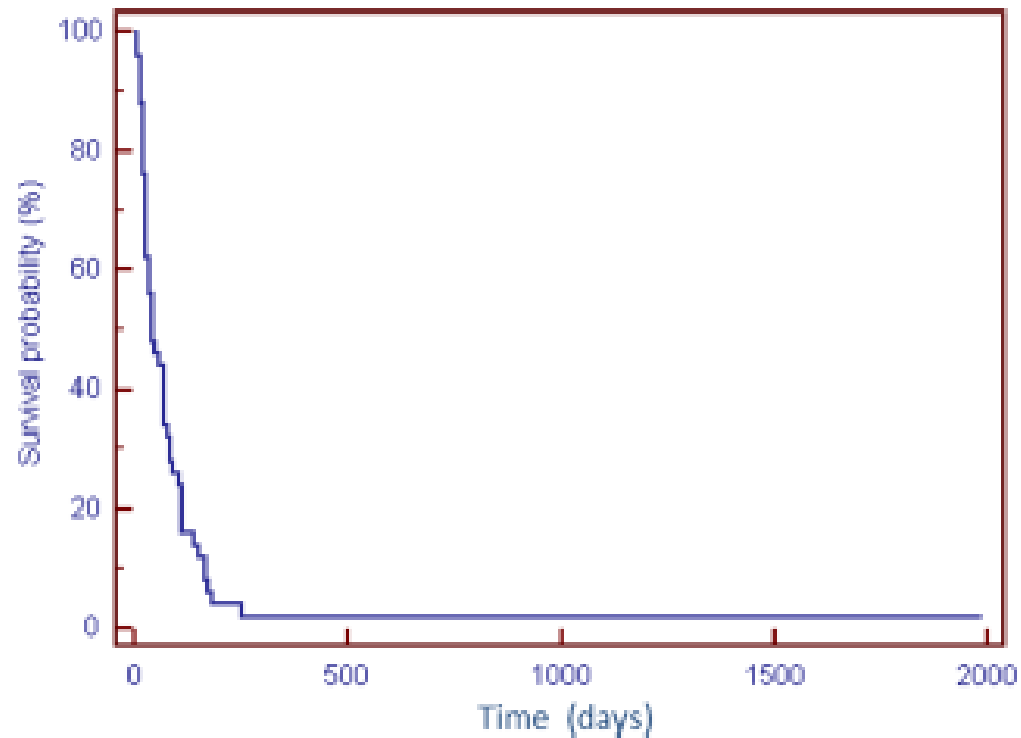
CNS=PD? headache

**pCT=CBV increase**

(How) to treat?







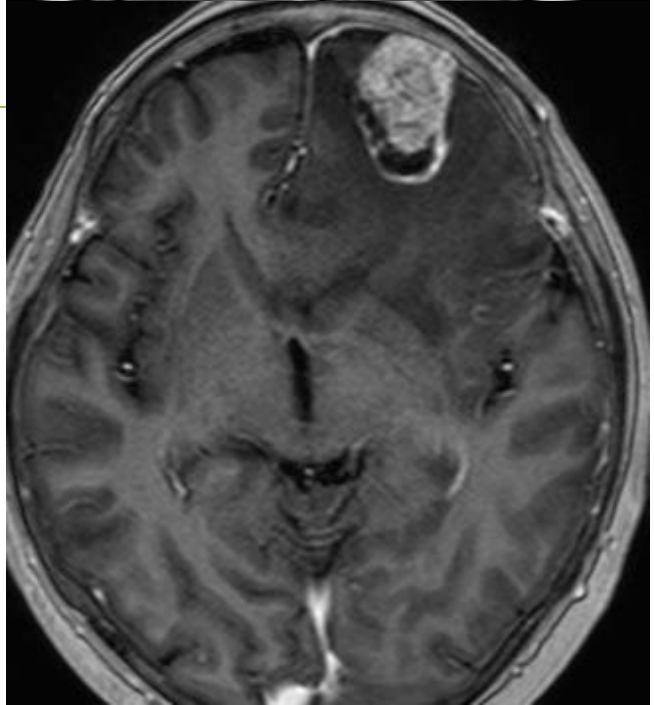
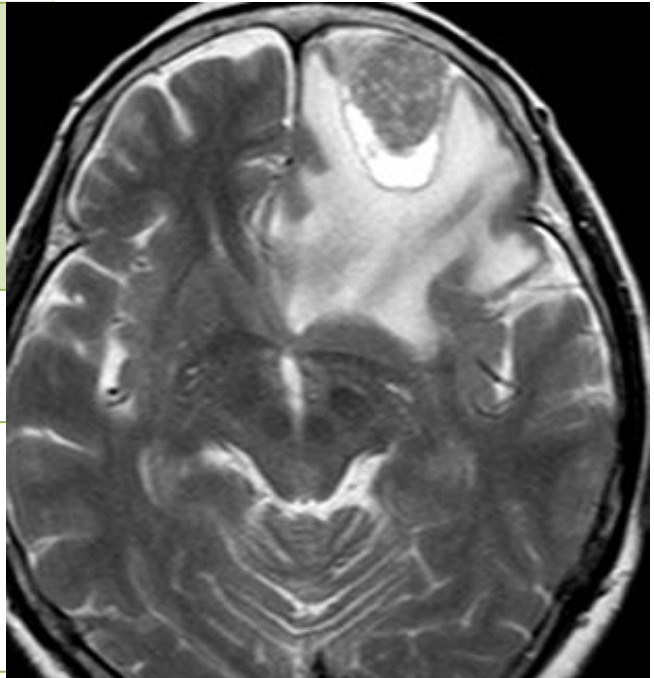
Neurol Sci (2015) 36:117–123  
DOI 10.1007/s10072-014-1881-7

ORIGINAL ARTICLE

## Leptomeningeal metastasis from solid tumors: a diagnostic and therapeutic challenge

Maria Grazia Passarin · Teodoro Sava · Jenny Furlanetto · Annamaria Molino · Rolando Nortilli · Anna Maria Musso · Marta Zaninelli · Tiziano Franceschi · Daniele Orrico · Sabrina Marangoni · Cristina Dealis · Claudio Graiff · Rodella Filippo · Salvatore Grisanti · Edda Simoncini · Lucia Vassalli · Alfredo Berruti · Rebecca Pedersini

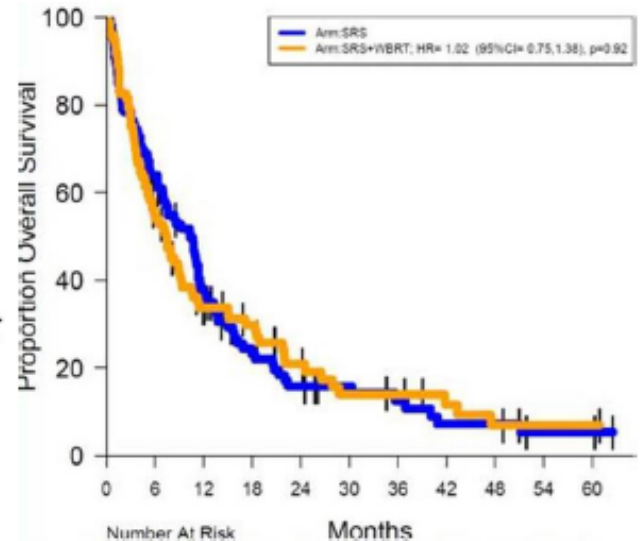
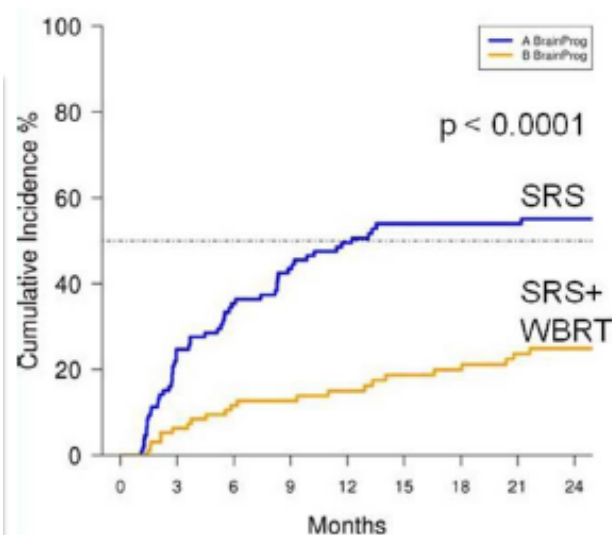
<b>Case 5</b> <b>68 y.o.</b> <b>Woman</b>	<b>NSCLC Adc</b> <b>T2aN2M0, Stage IIIa</b> <b>No complication</b>
Oct/200X	Lung lobectomy
5 years later Oct/201Y	Systemic=CR CNS=PD (single, 35mm) Asymptomatic
<b>(How) to treat?</b>	



# ASCO 2015

## NCCTG N0574: A phase III RCT of WBRT in addition to SRS in patients with 1 to 3 metastases

	No (Lung ca)	PS 0-1	3M-worse cognition	6M-CNS PD	OS(M)
<b>SRS</b>	<b>111 (72%)</b>	<b>91%</b>	<b>63.5%</b>	<b>35.4%</b>	<b>10.4</b>
<b>SRS + WBRT</b>	<b>102 (65%)</b>	<b>92%</b>	<b>91.7%</b>	<b>11.6%</b>	<b>7.4</b>
			<i><b>p=.0007</b></i>	<i><b>p&lt;.0001</b></i>	<i><b>p=.93</b></i>



By courtesy of Dr H. Okamoto, Yokohama Municipal Hosp, Japan

**Case 6**  
**79 y.o.**  
**Woman**

**NSCLC Adc**  
**pT1bN0M0, Stage IA**  
**EGFR mutation +**  
**Coronary artery bypass grafting**  
**Aspirin**

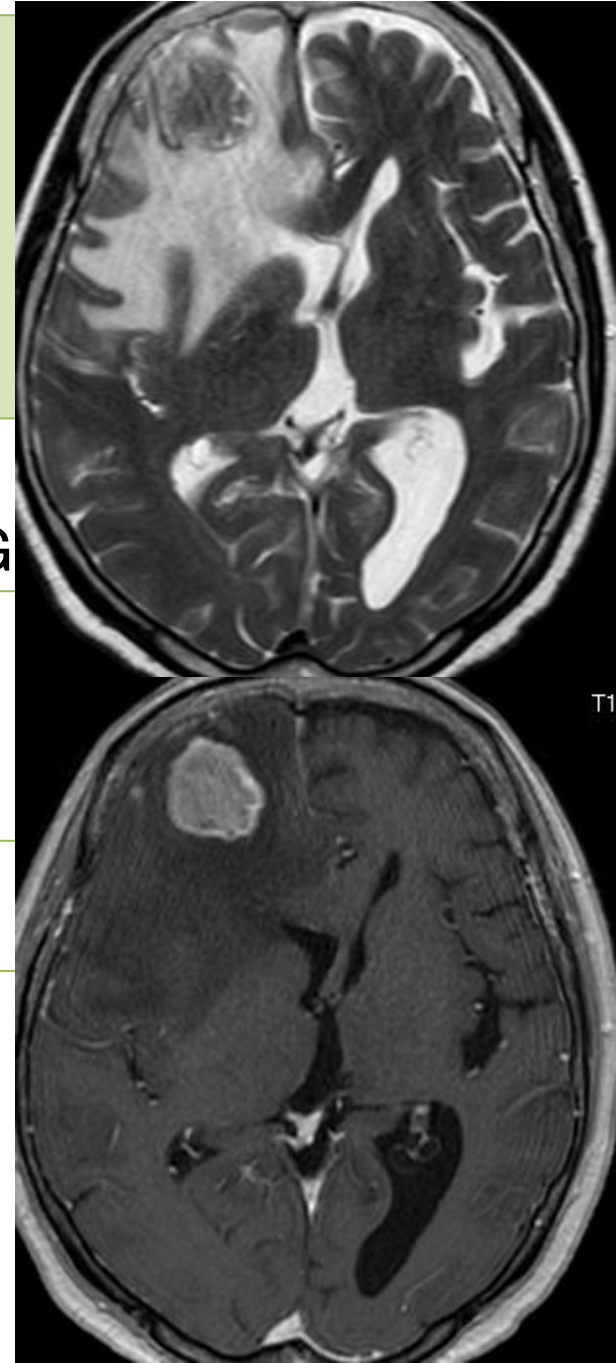Dec/201X

Lung lobectomy  
No adjuvant due to planned CABG

5 years later  
Dec/201Y

Systemic=CR  
CNS=PD met (single, 34mm)  
Dementia, Lt U/E palsy

(How) to treat?



- Isolated CNS failure in elderly with complication