Early-onset renal cell cancer

Fred H. Menko, MD, PhD
clinical geneticist
Netherlands Cancer Institute
Amsterdam, the Netherlands

ESMO Madrid 2014

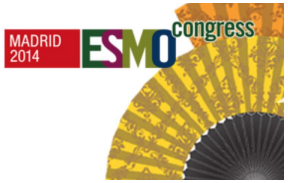

Early-onset renal cell cancer

Fred H. Menko, MD, PhD
clinical geneticist
Netherlands Cancer Institute
Amsterdam, the Netherlands

I have no conflicts of interest to declare

ESMO Madrid 2014

Age distribution of renal cell cancer

The Netherlands Cancer Registry 2012

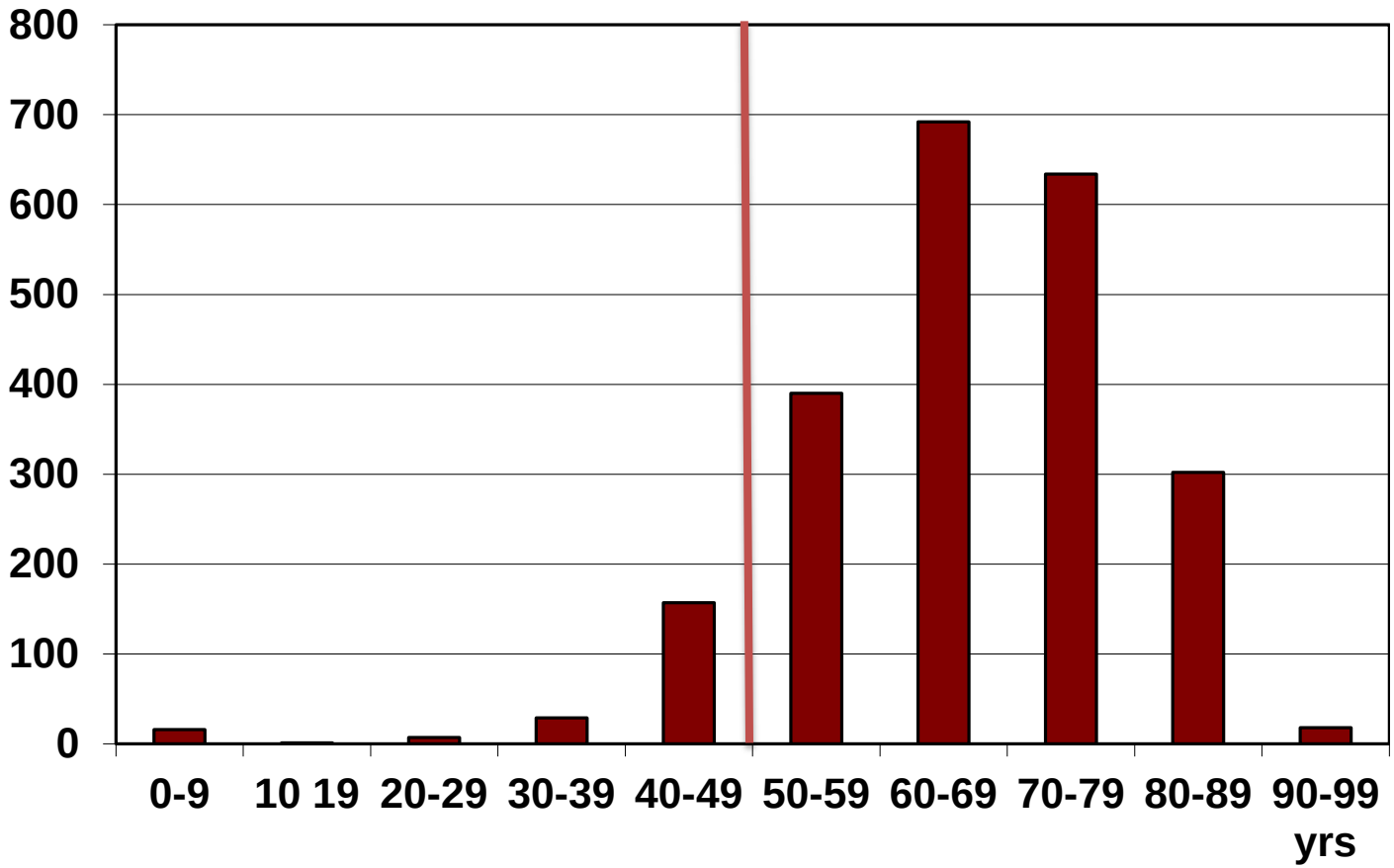

210/ 2236 = 9% below age 50 years

Contents

- Hereditary renal cell cancer
- Clinical recognition
- Diagnostic procedures
- Clinical relevance

Contents

- Hereditary renal cell cancer
- Clinical recognition
- Diagnostic procedures
- Clinical relevance

Hereditary renal cell cancer: 2-4% of all renal cell cancers

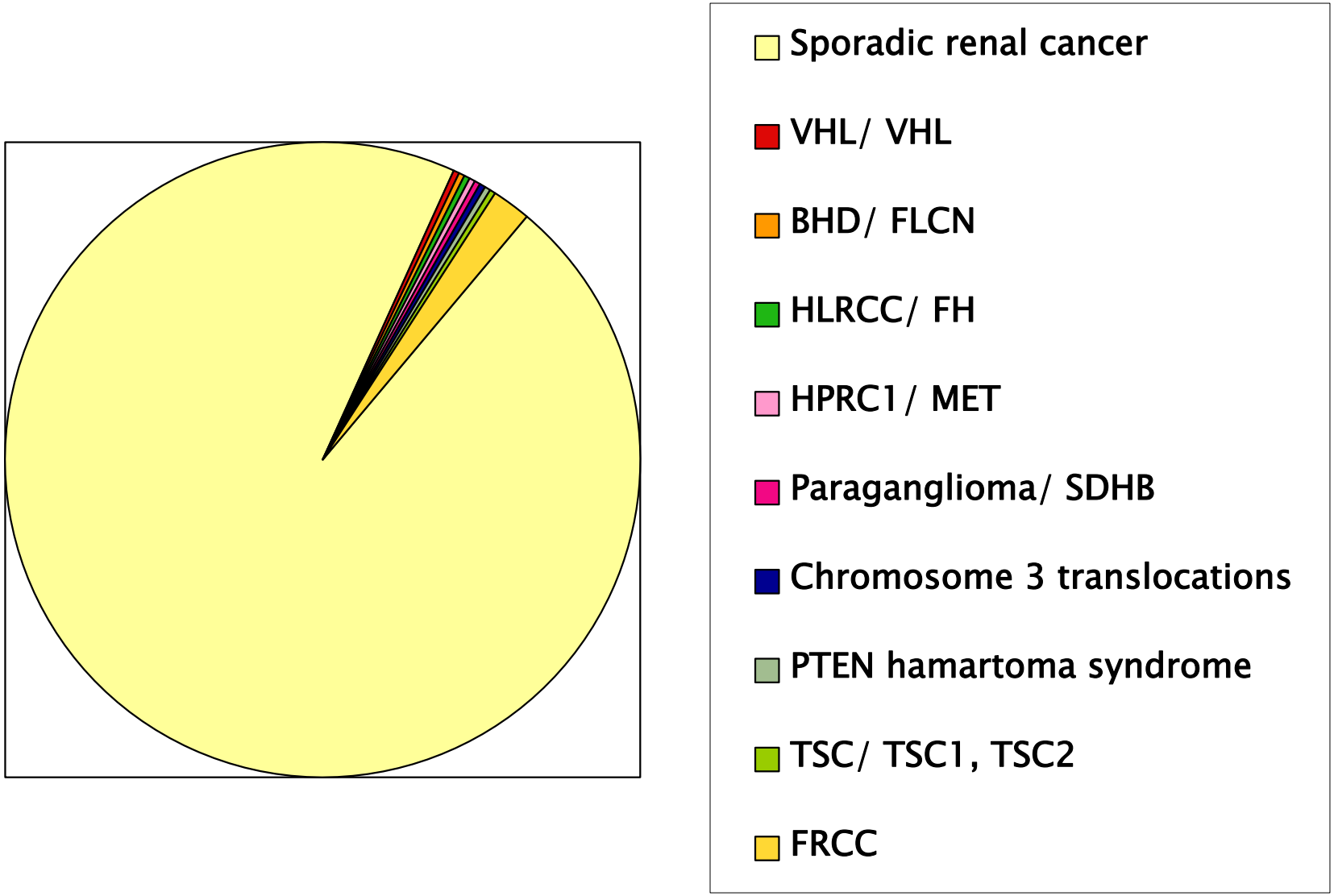

Autosomal dominant inheritance

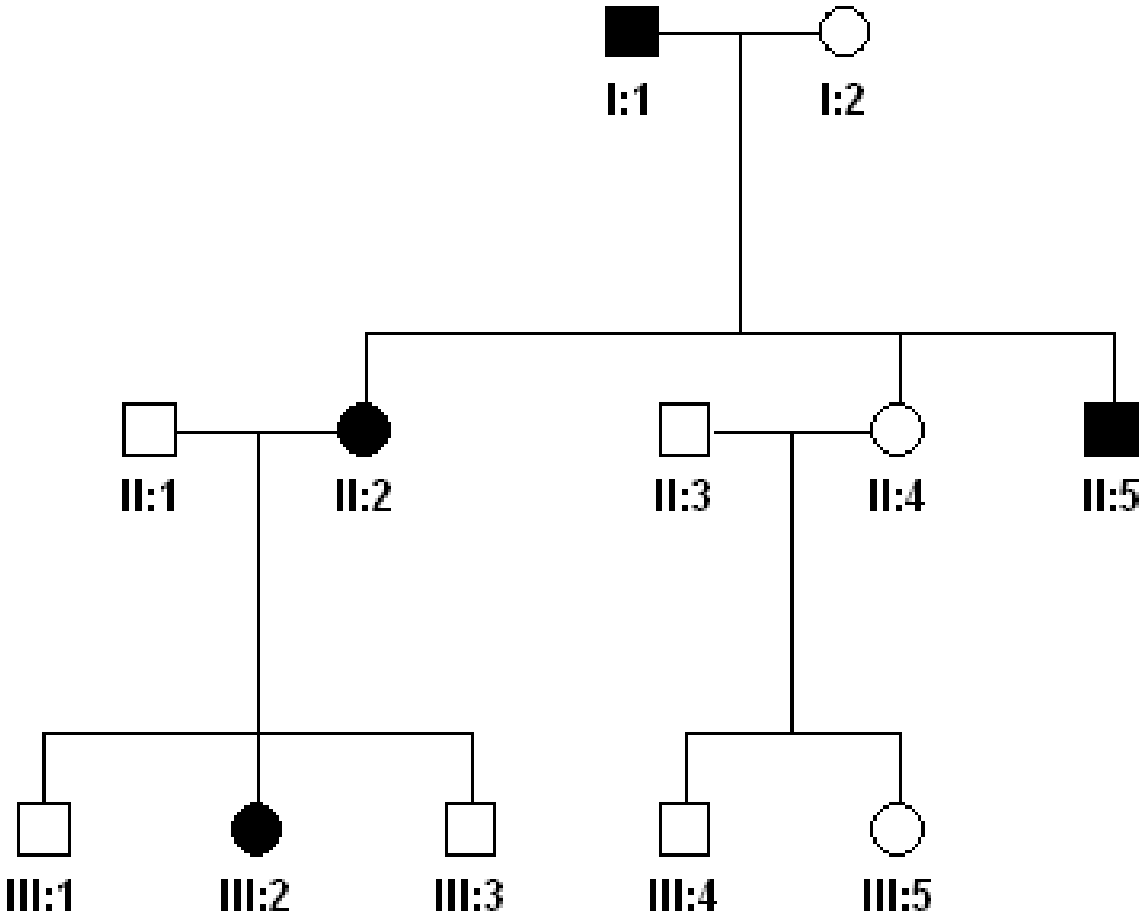

Contents

- Hereditary renal cell cancer
- Clinical recognition
- Diagnostic procedures
- Clinical relevance

Clinical recognition of hereditary renal cell cancer

- Patient:
  - Early age at diagnosis
  - Multifocal or bilateral disease
  - Typical histology
  - Other syndromic manifestations
- Family
  - Positive family history

Age distribution of RCC in Birt-Hogg-Dubé syndrome

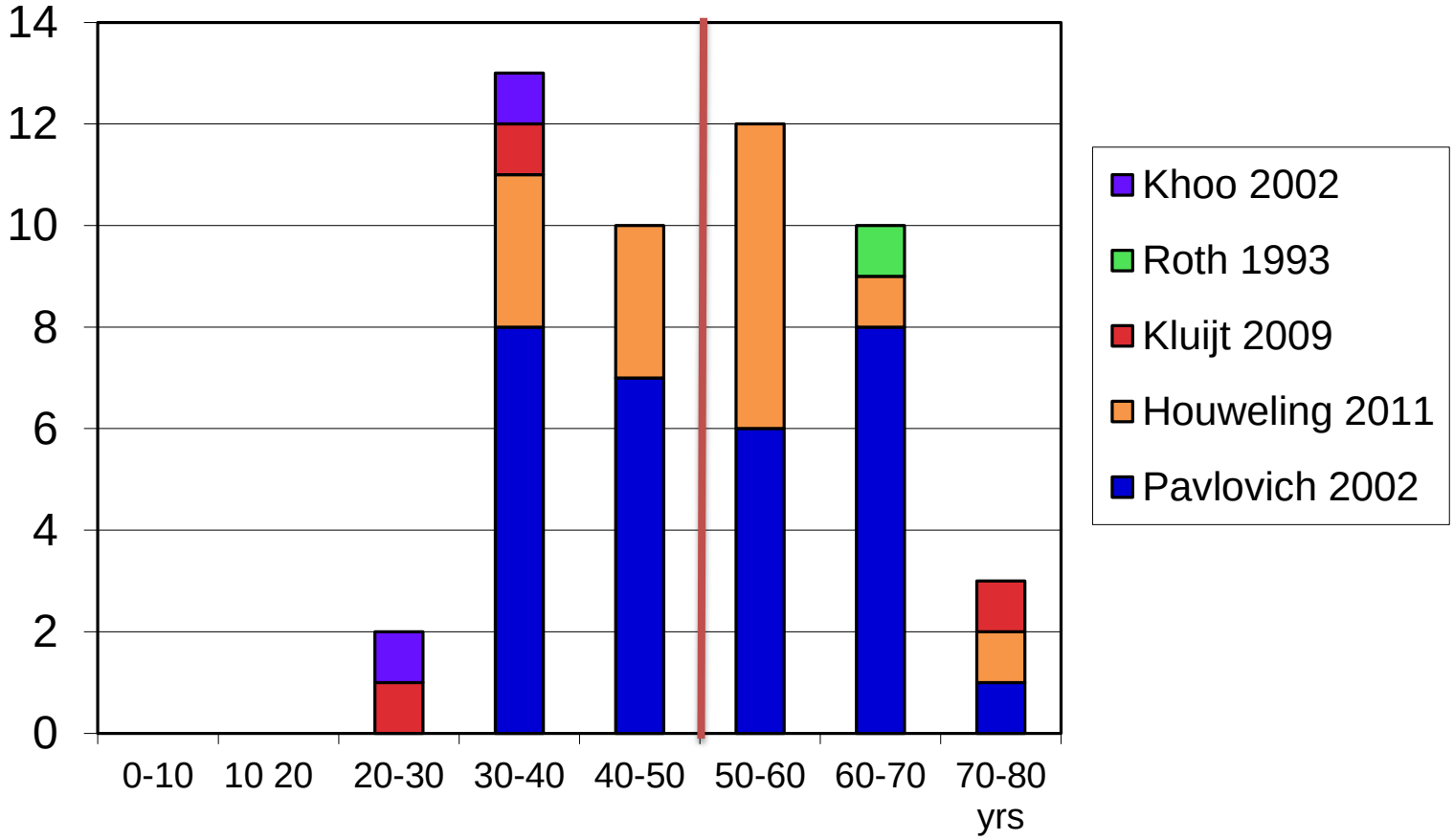

Early age at diagnosis

Table 1. Age of Onset by Hereditary Syndrome of NCI Urologic Oncology Branch Patients With Kidney Cancer

	Hereditary Syndrome				
Age, Years	VHL (n = 387)	BHD (n = 127)	HLRCC (n = 56)	HPRC (n = 25)	SDHB (n = 14)
Median	35	50	37	41	30
Mean	35.39	50.29	40.95	42.12	33.00
Range	16-79	23-74	10-77	19-66	15-61
SD	11.42	11.46	14.99	12.09	14.91

Abbreviations: BHD, Birt-Hogg-Dubé syndrome; HLRCC, hereditary leiomyomatosis and renal cell carcinoma; HPRC, hereditary papillary renal cell carcinoma; NCI, National Cancer Institute; SD, standard deviation; SDHB, succinate dehydrogenase B renal cell carcinoma; VHL, von Hippel-Lindau syndrome.

Shuch, B. et al., J. Clin. Oncol. 2013

Early age at diagnosis: ≤ 46 years

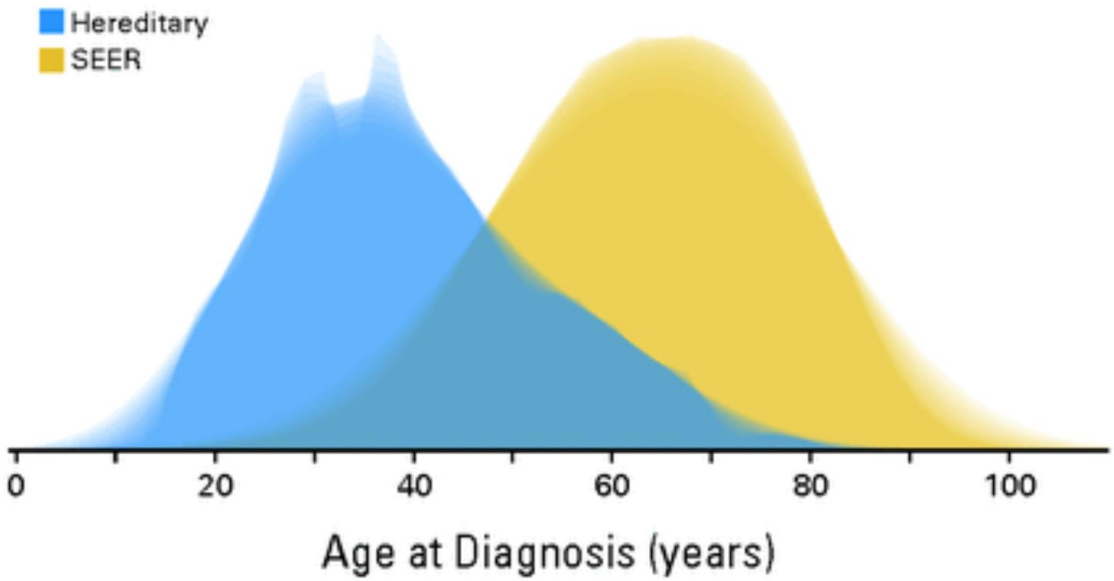

Shuch, B. et al., J. Clin. Oncol. 2013

Multifocal or bilateral disease

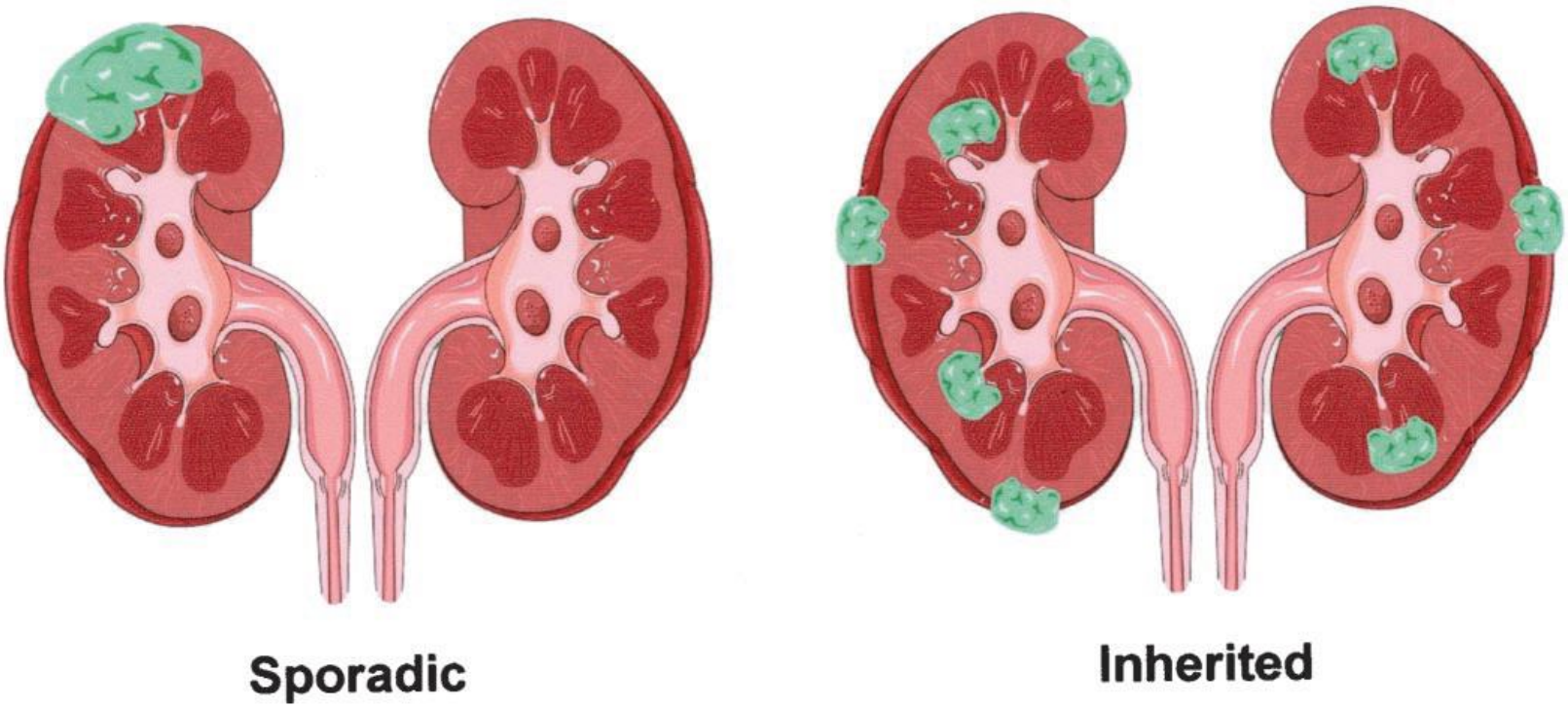

Linehan et al., J. Urol., 2003; 170: 2163-2172

Typical histology (1)

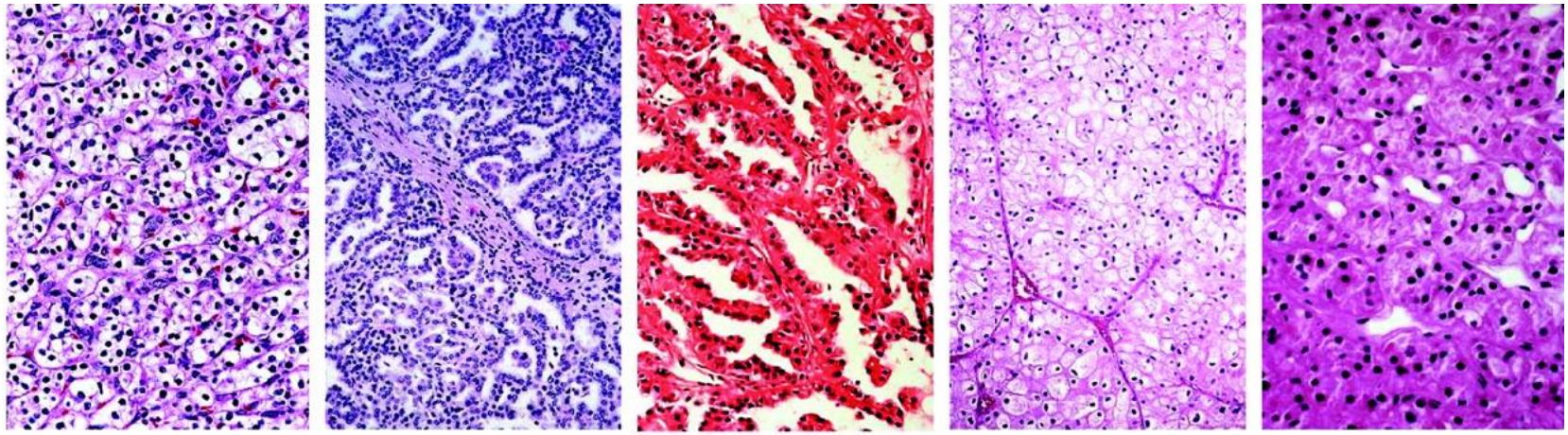

Type	Clear Cell	Papillary Type 1	Papillary Type 2	Chromophobe	Oncocytoma
	75%	5%	10%	5%	5%
Gene	VHL	Met	FH	BHD	

Linehan et al., Clin Cancer Res. 2004; 10: 6282s-6289s

Typical histology (2)

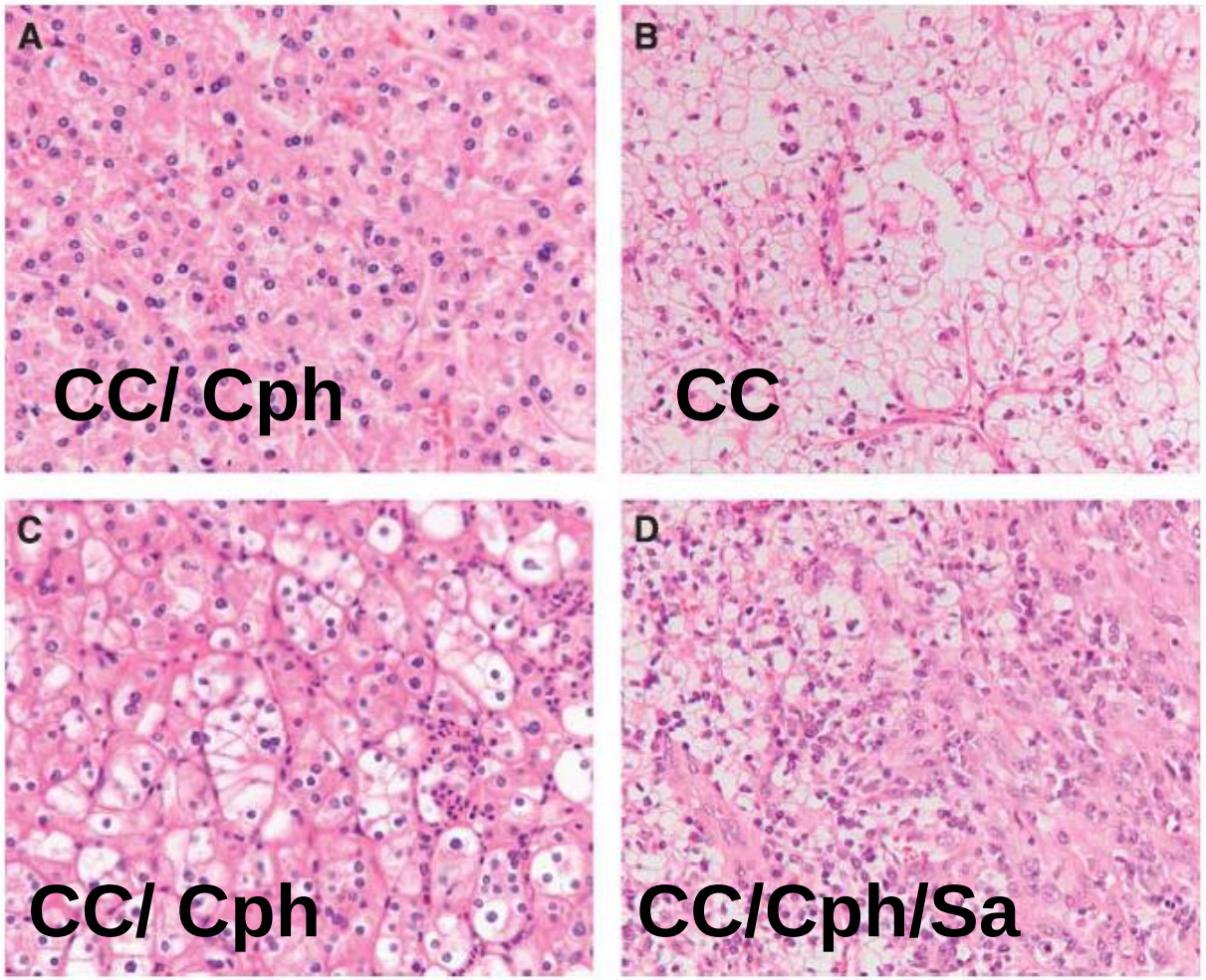

Houweling, A.C. et al., Br. J. Cancer 2011: 105: 1912-1919

Other syndromic manifestations (1): VHL as an example

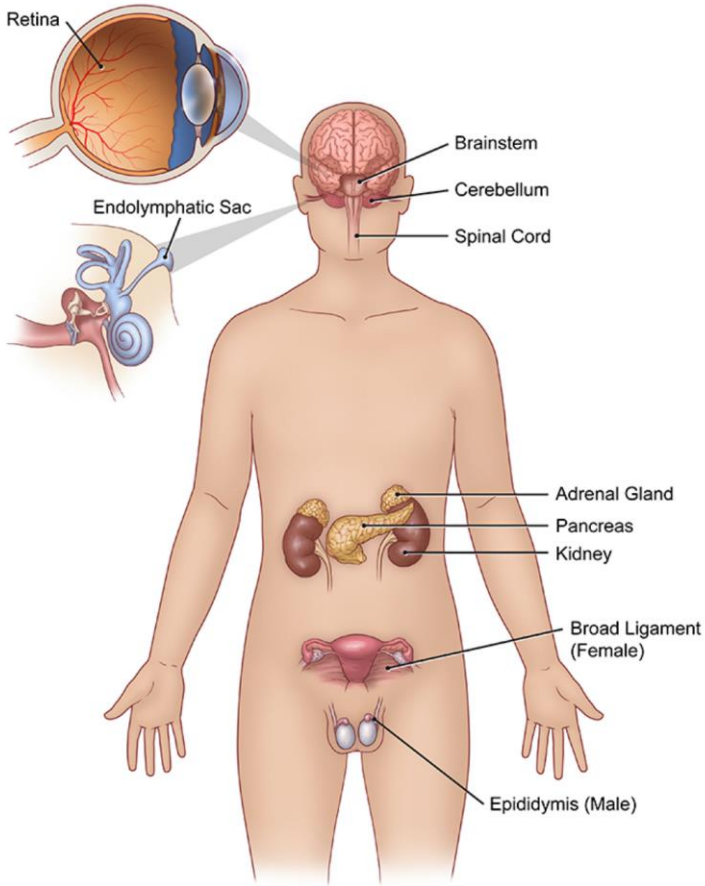

Other syndromic manifestations (2): the skin

Fibrofolliculomas in BHD

Leiomyomas in HLRCC

Contents

- Hereditary renal cell cancer
- Clinical recognition
- Diagnostic procedures
- Clinical relevance

Hereditary renal cell cancer: 2-4% of all renal cell cancers

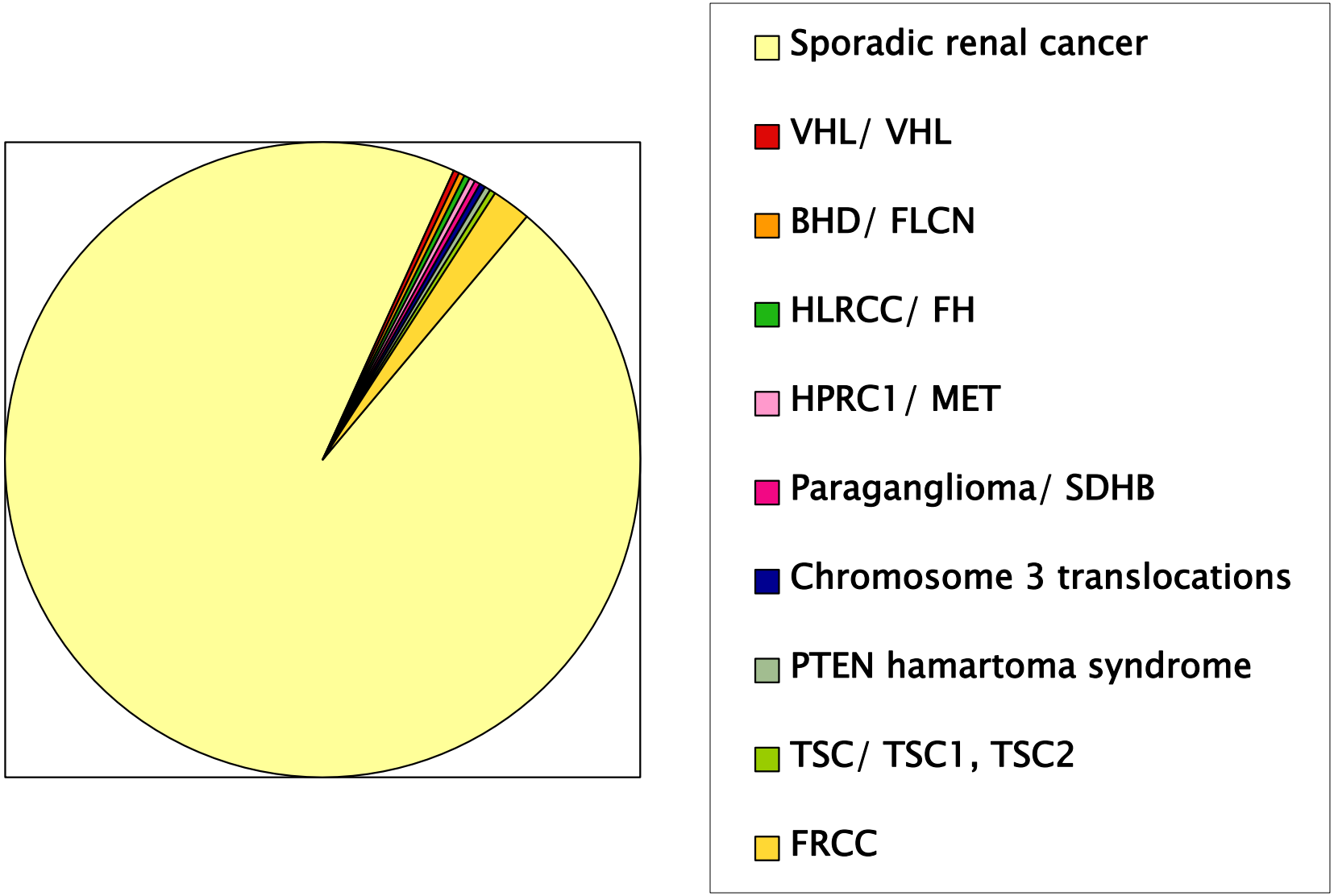

RenalNext® Ambry Genetics: 18 genes	
VHL	*VHL*
BHD	*FLCN*
HLRCC	*FH*
HPRC1	*MET*
Paraganglioma	*SDHA, SDHB, SDHC,SDHD*
Chromosome 3 translocations	Karyotyping
PTEN hamartoma syndrome	*PTEN*
TSC	*TSC1, TSC2*
Lynch syndrome	*MLH1, MSH2, EPCAM, MSH6, PMS2*
Li-Fraumeni syndrome	*TP53*
Melanoma and RCC	*MITF*

A Novel Germline Mutation in *BAP1* Predisposes to Familial Clear-Cell Renal Cell Carcinoma

Farley et al., Mol. Cancer Res. 2013; 11: 1061-1071

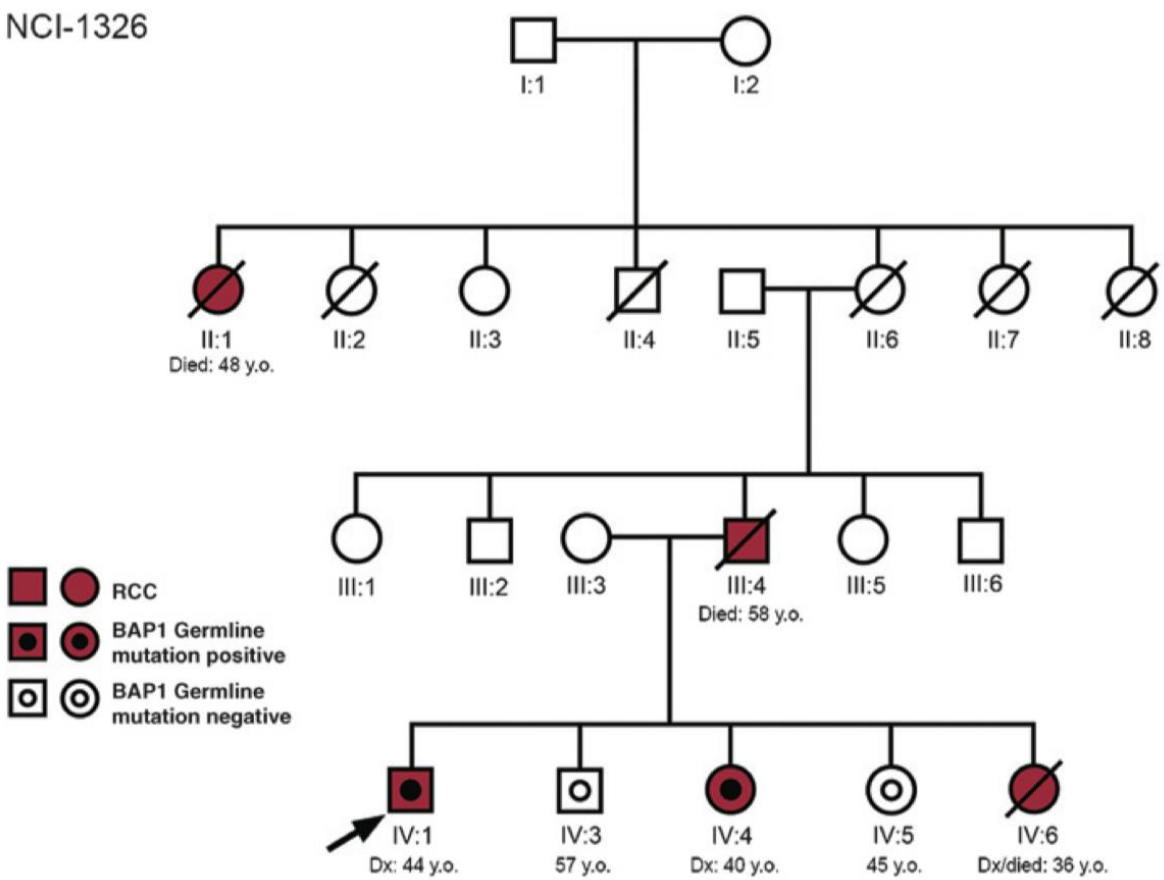

Hereditary renal cell cancer: 2-4% of all renal cell cancers

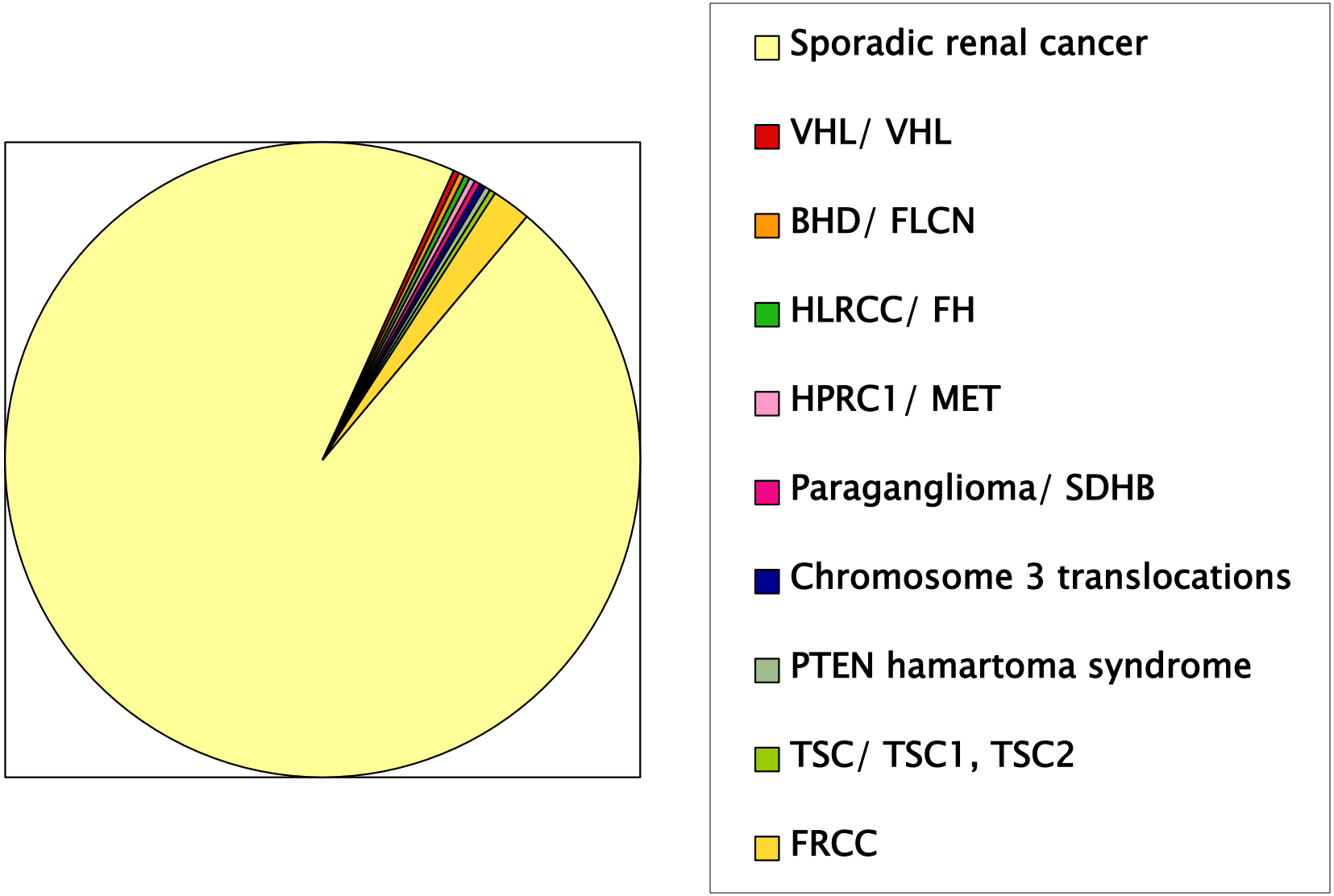

Contents

- Hereditary renal cell cancer
- Clinical recognition
- Diagnostic procedures
- Clinical relevance
  - Surveillance
  - Surgery
  - Systemic therapy

Surveillance in hereditary renal cell cancer: examples of proposed surveillance schemes

Syndrome	RCC risk	Starting age (yrs)	Method	Interval	Reference
VHL	70%	16 yrs	Ultrasound MRI	1 yr 2 yrs	Frantzen et al., GeneReviews 2012
BHD	15%	18 yrs	MRI	2 yrs	Toro GeneReviews 2014
HLRCC	15%	8-10 yrs	MRI	1 yr	Menko et al., Fam. Cancer 2014

Surgery: the “3-cm rule” and partial nephrectomy

- Hereditary RCC comprises 4% of all renal tumors, whereas multifocal renal tumors are found in 3–11% of patients clinically and up to 25% pathologically.
- The ‘3-cm rule’ developed for managing VHL patients can also safely be applied to patients with BHD, HPRC.
- The ‘3-cm rule’ is not appropriate for patients with suspected renal masses and known germline HLRCC or SDH mutations.
- Enucleation of tumors is appropriate for VHL, BHD and HPRC; wide margins are required for HLRCC and SDH-related kidney tumors.
- Long-term oncologic control and renal functional preservation are excellent at more than 10 years of follow-up using this approach.

Metwalli & Linehan, Curr. Opin. Urol. 2014; 24: 466-473

Systemic therapy: general

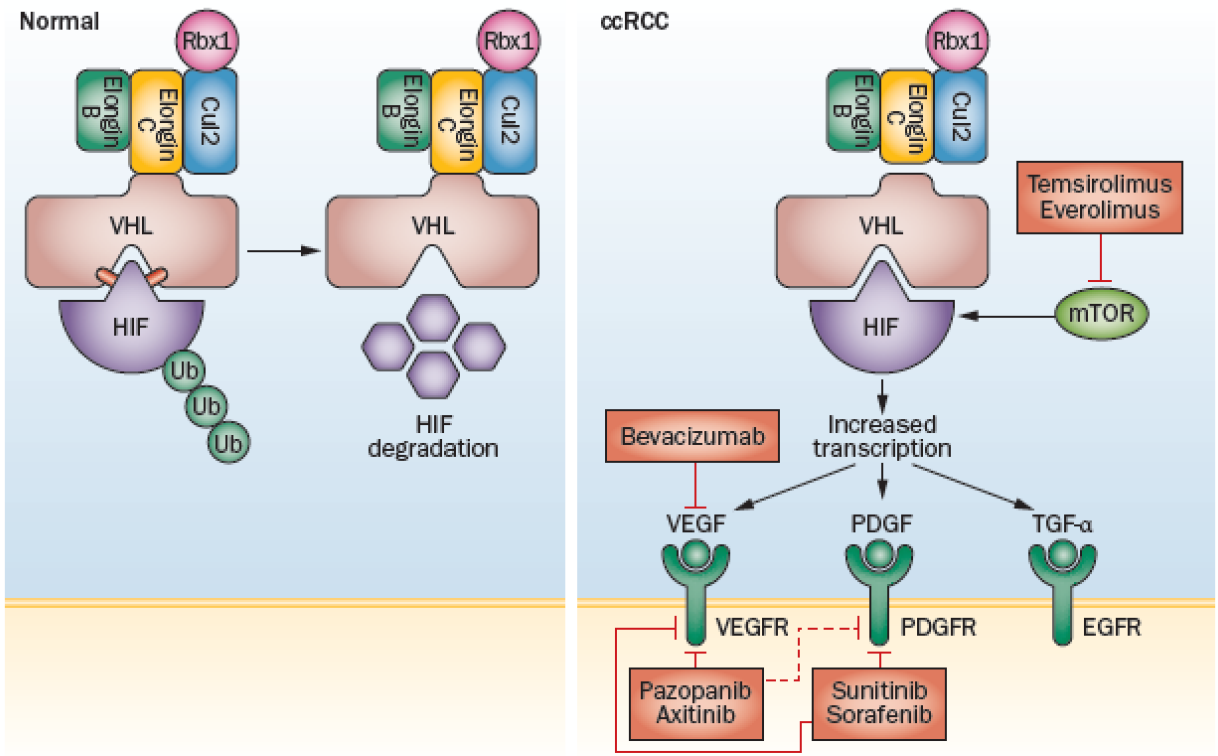

Figure 1 | The seven FDA-approved agents for the treatment of kidney cancer targeting the von Hippel–Lindau (VHL) tumour suppressor pathway.

Linehan & Srinivasan Nat. Rev. Clin. Oncol. 2013; 10: 614-615

Renal cell carcinoma: ESMO Clinical Practice Guidelines

Escudier, B. et al., Ann. Oncol. 2014; 25: 49-56

Histology and setting	Risk group	Standard	Option
Clear-cell first line	Good or intermediate risk	Sunitinib Bevacizumab + IFN-α Pazopanib	High-dose IL-2 Sorafenib Bevacizumab + low-dose IFN-α
	Poor risk	Temsirolimus	Sunitinib Sorafenib
Non-clear-cell histology			Temsirolimus Sunitinib Sorafenib

Systemic therapy: HLRCC as an example

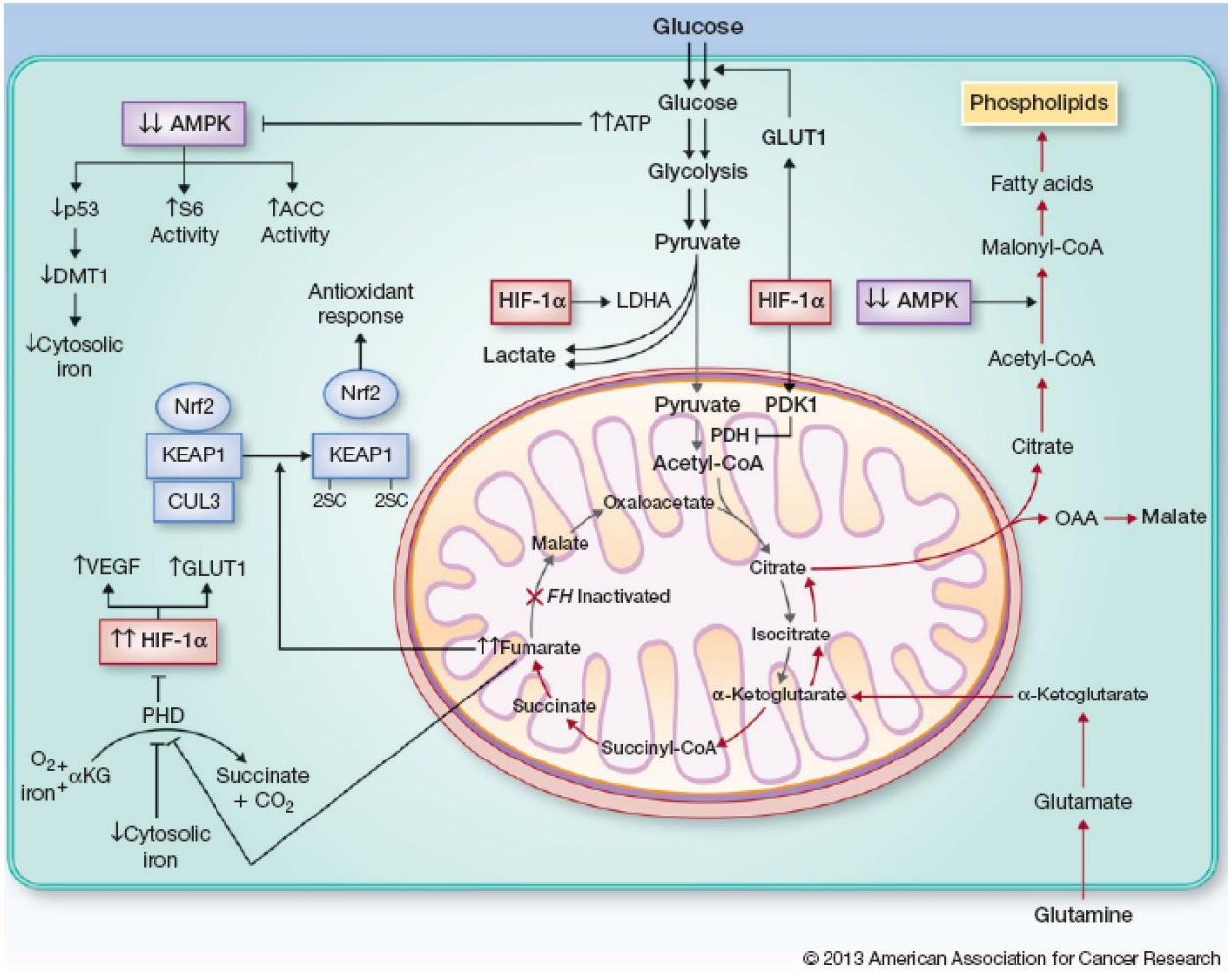

© 2013 American Association for Cancer Research

Linehan & Raoult, Clin. Cancer Res. 2013; 19: 3345-3352

Systemic therapy: HLRCC as an example

Nature Reviews Urology **8**, 165-171 (March 2011) |

Exploring a glycolytic inhibitor for the treatment of an *FH*-deficient type-2 papillary RCC

Toshinari Yamasaki, Tram Anh T. Tran, Orhan K. Oz, Ganesh V. Raj, Roderich E. Schwarz, Ralph J. DeBerardinis, Xuewu Zhang & James Brugarolas

Conclusions

- Recognition of hereditary RCC is important for the patients and at-risk family members
- Research of hereditary RCC is important also for sporadic RCC
- Early onset RCC is defined by age at diagnosis < 45 years
- Application of NGS diagnostics will need careful consideration and evaluation

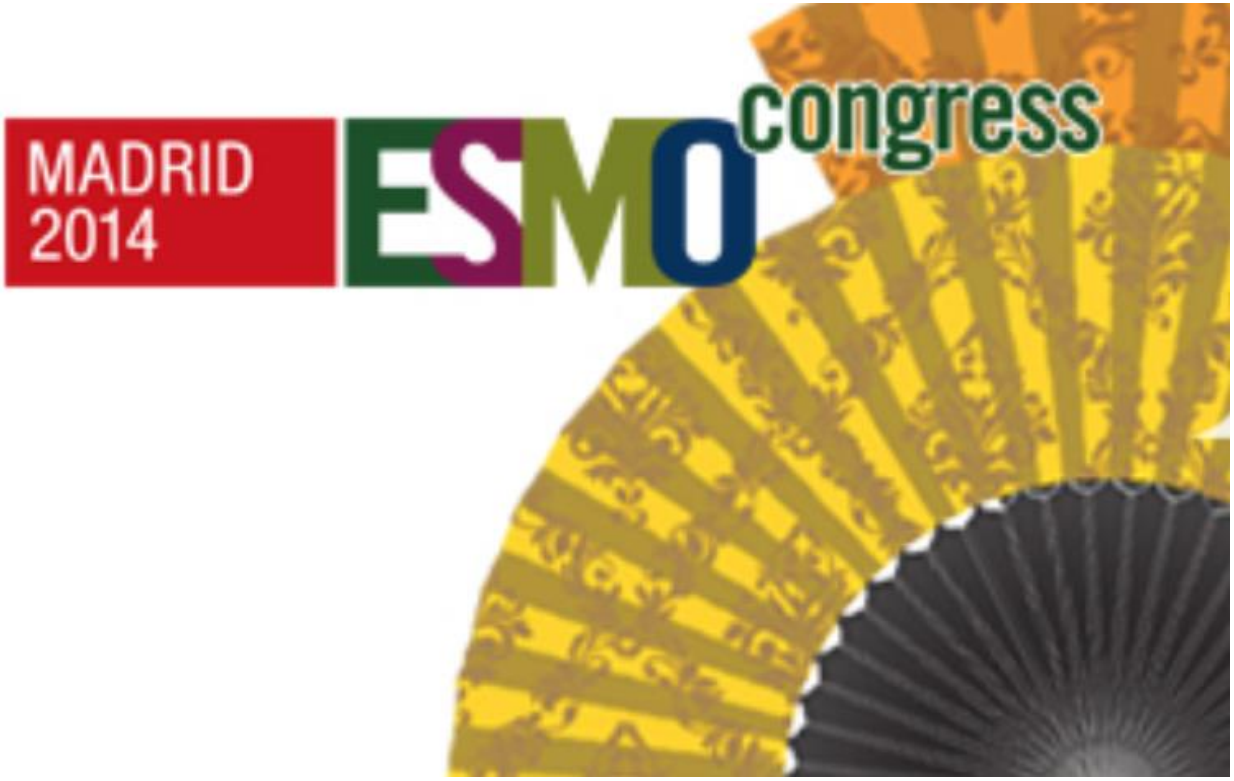
MADRID
2014
ESMO
congress

Patient cases

Case: a 30-year-old male with recurrent spontaneous pneumothorax

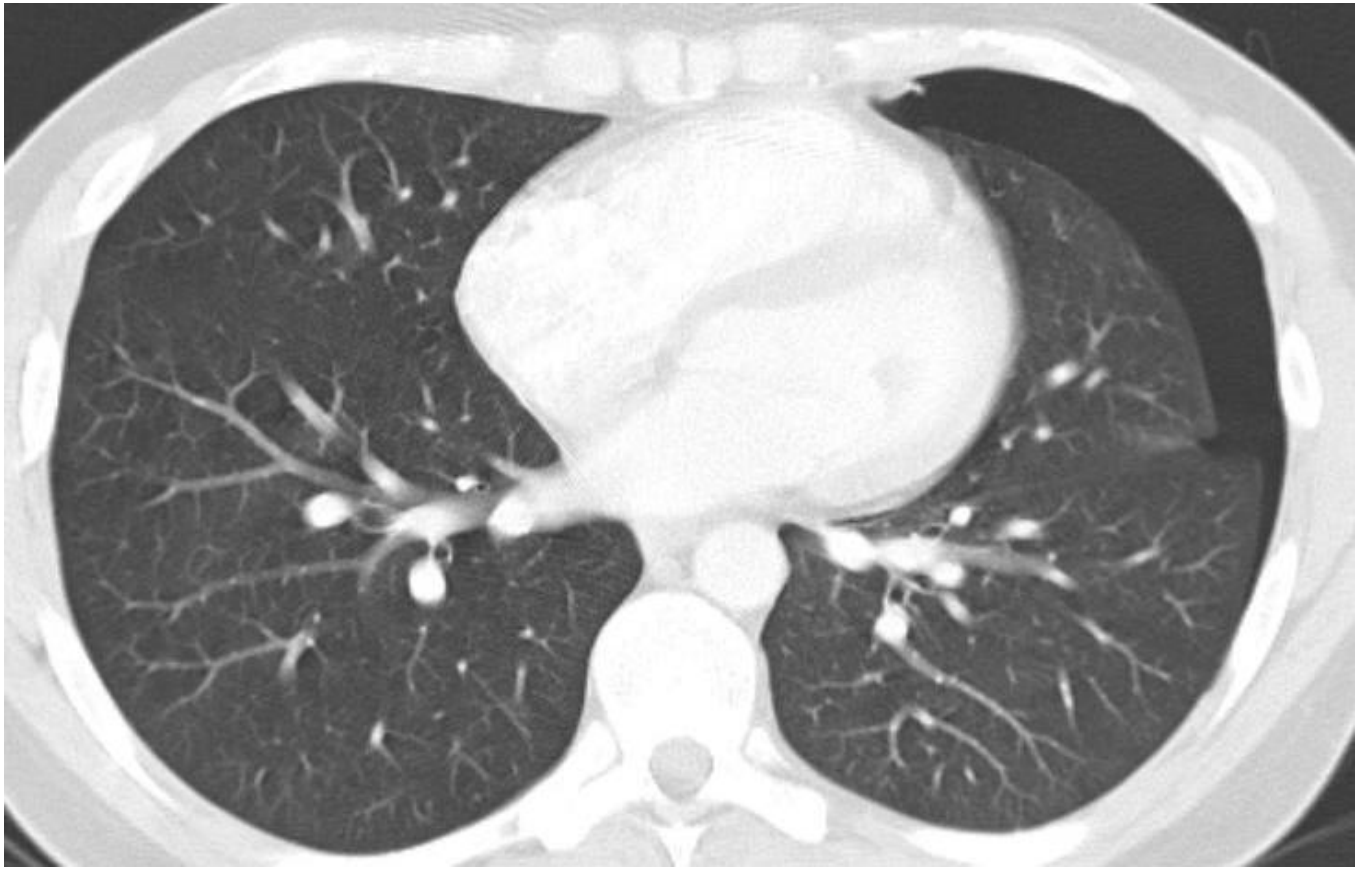

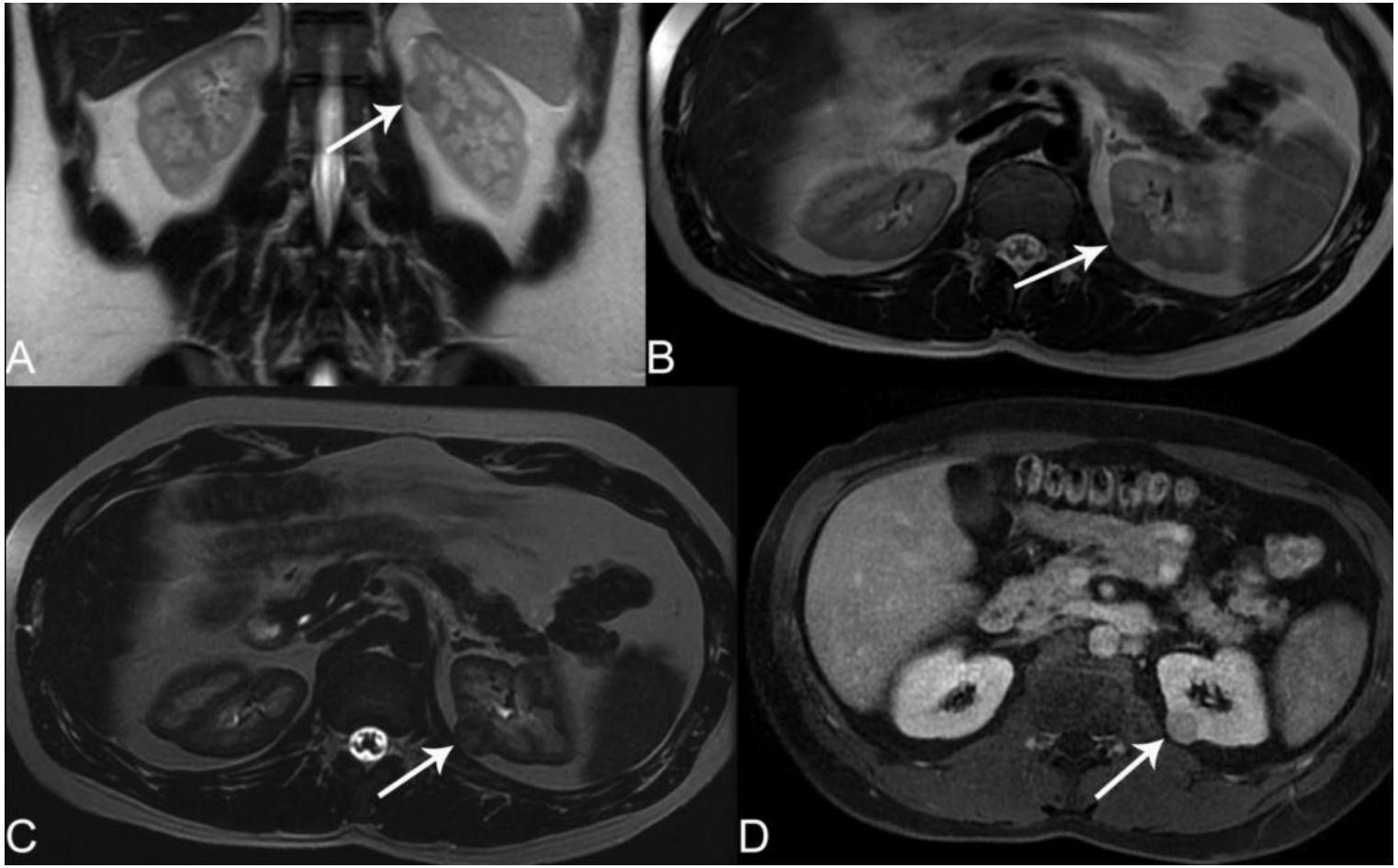

J.H- van Waesberghe, radiologist, R.J.A. van Moorselaar, urologist, Vumc, Amsterdam

Renal imaging: small renal tumour
Treatment: partial nephrectomy
Histology: chromophobe carcinoma

Case: a 51-year-old man with a large symptomatic chromophobe renal cell cancer

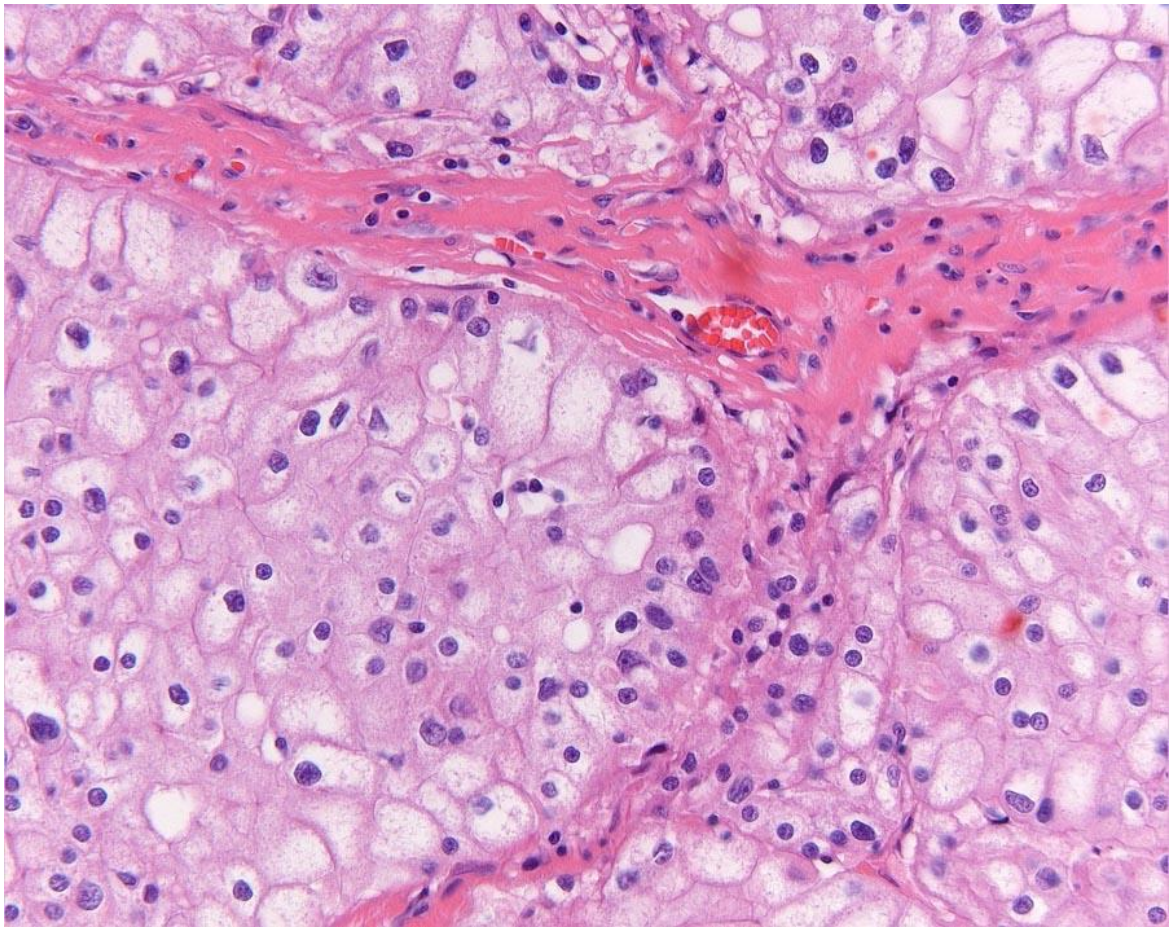

Familial occurrence of Birt-Hogg-Dubé syndrome

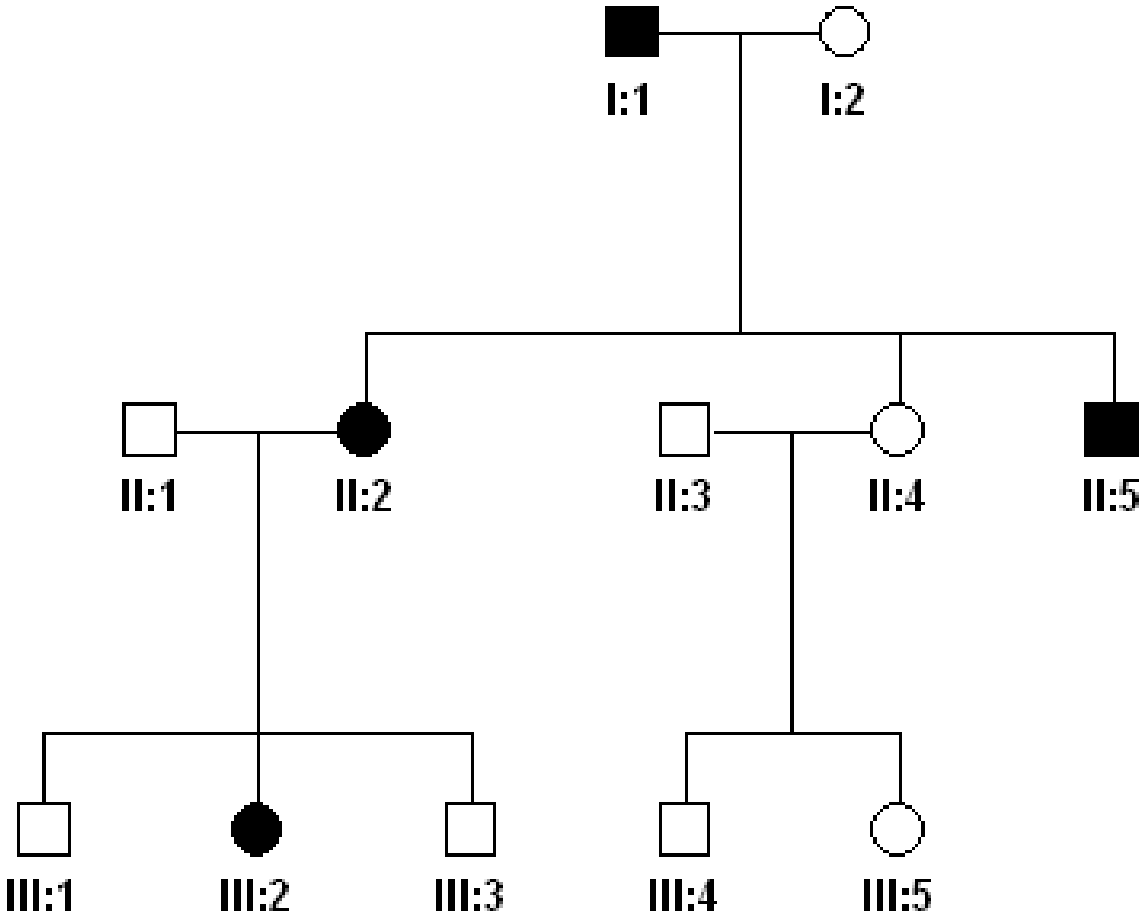

Case: a 18-year-old woman with metastatic renal cell cancer

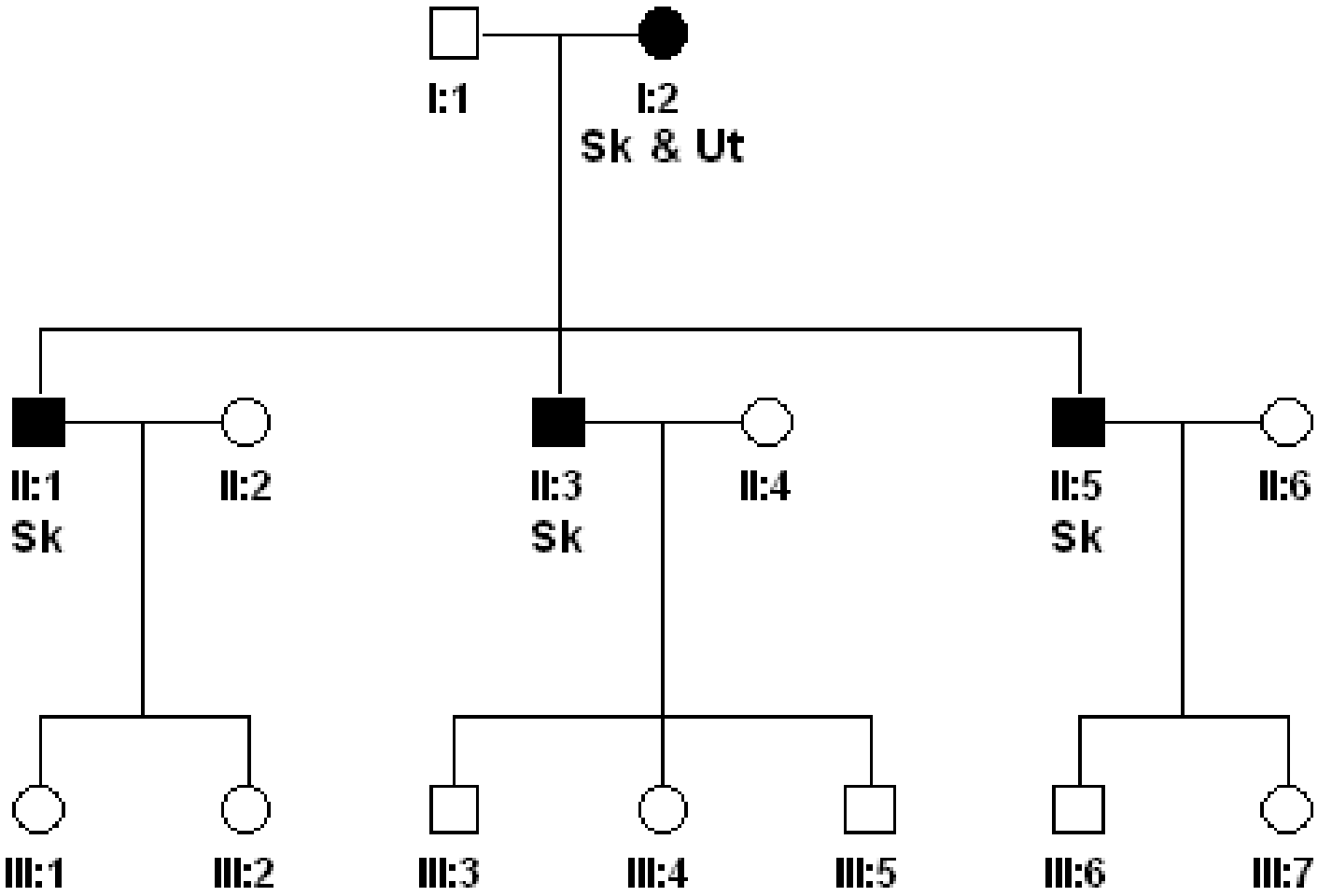

FH mutation c.1002T>G, p.Ser334Arg

Badeloe, S. et al., J. Dermatol. Sci. 2008; 51: 139-143

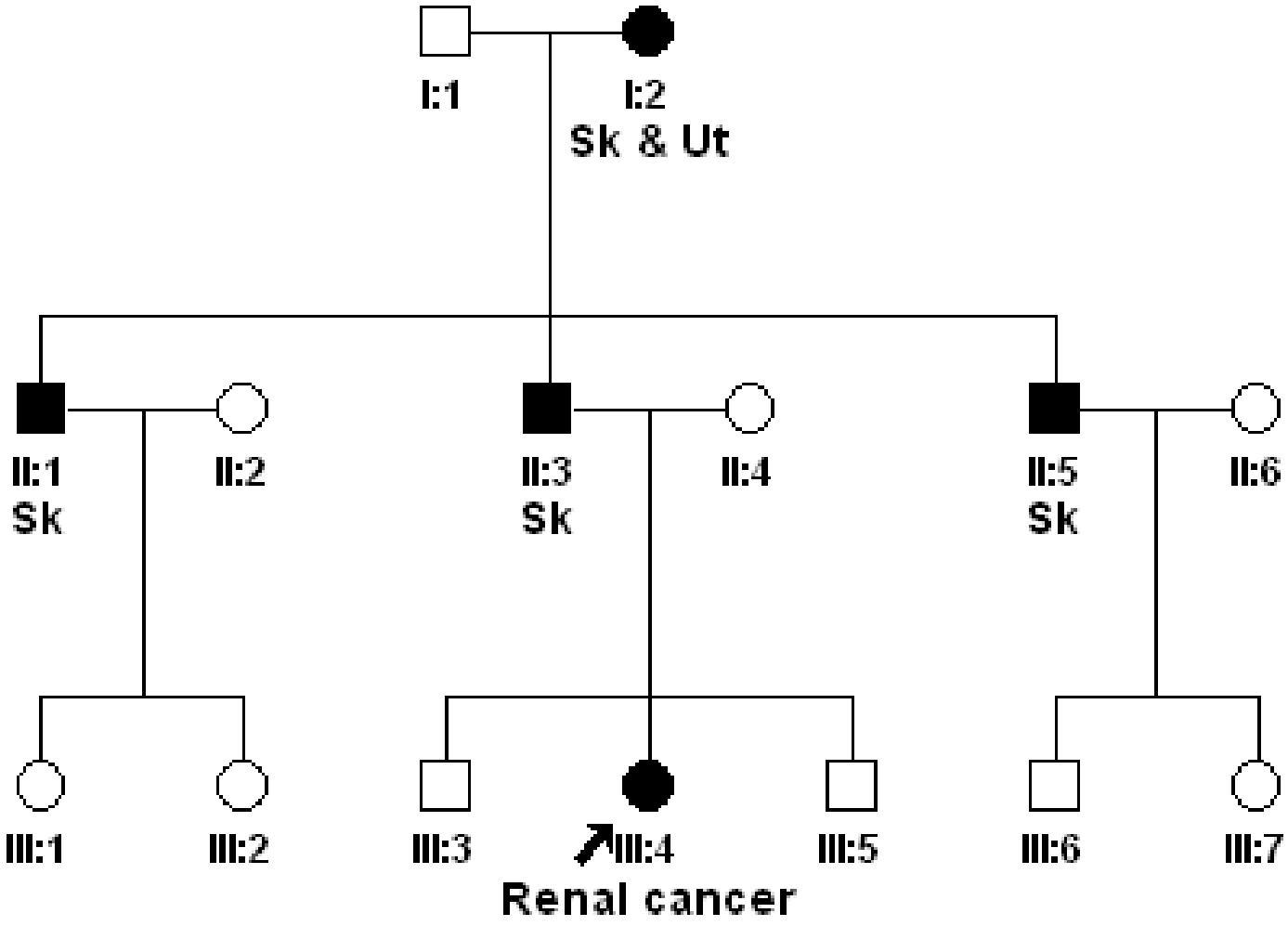
I:1
I:2
Sk & Ut
II:1
Sk
II:2
II:3
Sk
II:4
II:5
Sk
II:6
III:1
III:2
III:3
III:4
III:5
III:6
III:7
Renal cancer

Summary of clinical data:

At age 18 yrs (august 2010)

Tiredness, cough, loss of weight

Metastatic renal cell cancer

Papillary type 2 tumour

Died May 2011

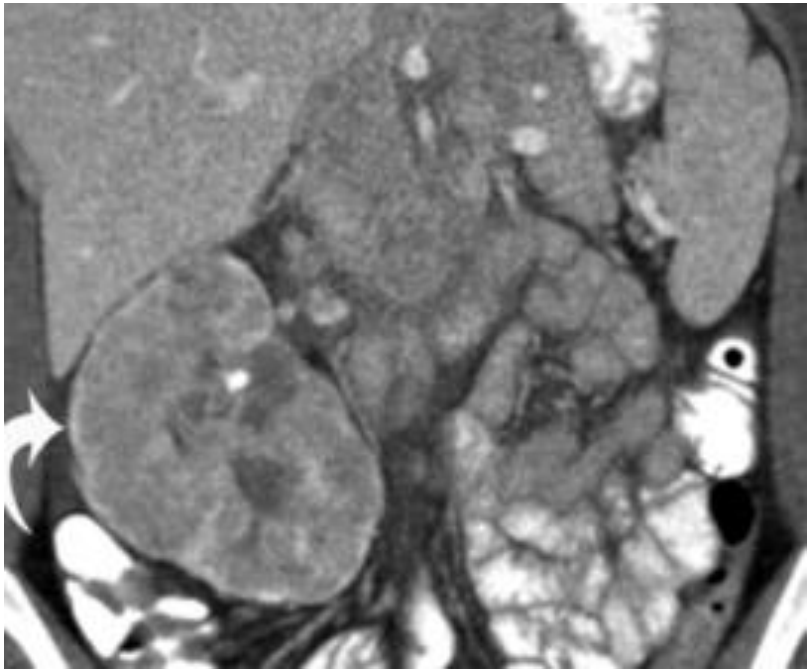

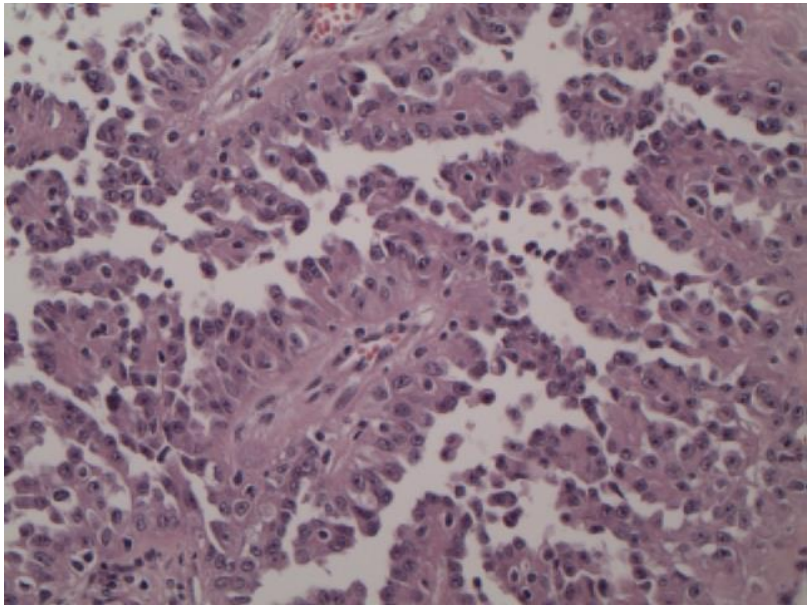

Cutaneous piloleiomyomas

Cutaneous piloleiomyomas

Cutaneous piloleiomyomas