SURGERY FOR SYNCHRONOUS LUNG TUMORS

Giulia Veronesi

Humanitas Research Hospital- Milan

European Institute of Oncology- Milan

Definition and implication for treatment

Sinchronous Primary Lung Cancers

Aggressive local treatment

Primary lung cancer with Lung metastasis

Palliative systemic therapy

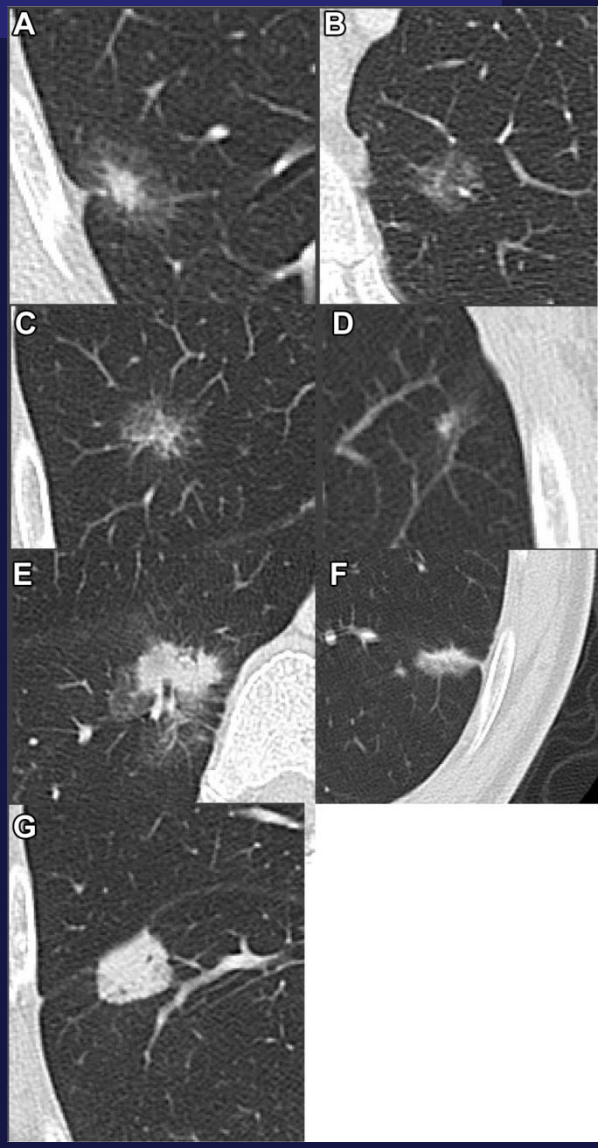

Epidemiology MPLC

- 6% of all tumors
- rate of operability 44-76% in surgical series
- 20-40% are sinchronous (rate increase if review of previous CT scan is performed)
- About halph has same hystology

Riquet et al ANN Thor Surg 2008

Martini et Melamed - Antakli

Table 1
Criteria for diagnosis of second primary lung cancer.

Martini and Melamed criteria
Synchronous MPLC
- A. Tumors physically distinct and separate
- B. Histological type
  - 1. Different
  - 2. Same, but in different segments, lobes, or lungs, if
    - a. Origin from carcinoma in situ
    - b. No carcinoma in common lymphatics
    - c. No extrapulmonary metastases at the time of diagnosis

Metachronous MPLC
- A. Histologically different
- B. Histologically identical, if
  - 1. Free interval between cancers > = 2 years, or
  - 2. Origin from carcinoma in situ
  - 3. Second cancer in different lobe or lung, but:
    - a. No carcinoma in common lymphatics
    - b. No extrapulmonary metastases at time of diagnosis

Antakli et al. modifications
- A. Different histological conditions
- B. Same histological condition with two or more of the following
  - 1. Anatomically distinct
  - 2. Associated premalignant lesion
  - 3. No systemic metastases
  - 4. No mediastinal spread
  - 5. Different DNA ploidy

Martini et Melamed 1975 J Thor Card Surg; Antakli 1995 Ann Thorac Surg

Special Treatment Issues in Lung Cancer*

ACCP Evidence-Based Clinical Practice Guidelines (2nd Edition)

Chest 2007

K. Robert Shen, MD; Bryan F. Meyers, MD, FCCP; James M. Larner, MD; and David R. Jones, MD, FCCP

Table 2—*Definition of Satellite Nodules, MPLCs, and Pulmonary Metastases*

Satellite nodules from primary tumor	Satellite nodules
Same histology	
And same lobe as primary cancer	
And no systemic metastases	
MPLCs	MPLC
Same histology, anatomically separated	
Cancers in different lobes	
And no N2,3 involvement	
And no systemic metastases	
Same histology, temporally separated	
≥ 4-yr interval between cancers	
And no systemic metastases from either cancer	
Different histology	
Different histologic type	
Or different molecular genetic characteristics	
Or arising separately from foci of carcinoma *in situ*	
Hematogenously spread pulmonary metastases	Metastasis
Same histology and multiple systemic metastases	
Same histology, in different lobes	
And presence of N2,3 involvement	
Or < 2-yr interval	

Special Treatment Issues in Lung Cancer*

ACCP Evidence-Based Clinical Practice Guidelines (2nd Edition)

K. Robert Shen, MD; Bryan F. Meyers, MD, FCCP; James M. Larner, MD; and David R. Jones, MD, FCCP

Satellite no

10% of pat ected

preoperati

A patient s approach

on the bas le

13. In patients with suspected or proven lung cancer and a satellite nodule within the same lobe, it is recommend that no further diagnostic workup of a satellite nodule be undertaken. Grade of recommendation, 1B

14. In patients with a satellite lesion within the same lobe as a suspected or proven primary lung cancer, evaluation of extrathoracic metastases and confirmation of the mediastinal node status should be performed as dictated by the primary lung cancer alone and not modified because of the presence of the satellite lesion. Grade of recommendation, 1C

15. In patients with NSCLC and a satellite focus of cancer within the same lobe (and no mediastinal or distant metastases), resection via a lobectomy is the recommended treatment. Grade of recommendation, 1B

Synchronous primaries

A syn
defin
histo

Canc
gene
distin
sepa

One
prima
no si
histol

16. In patients who have two synchronous primary NSCLCs and are being considered for curative surgical resection, invasive mediastinal staging and extrathoracic imaging (head CT/MRI plus either whole-body PET or abdominal CT plus bone scan) are recommended. Involvement of mediastinal nodes and/or metastatic disease represents a contraindication to resection. Grade of recommendation, 1C

18. In patients (not suspected of having a second focus of cancer) who are found intraoperatively to have a second cancer in a different lobe, resection of each lesion is recommended, provided that the patient has adequate pulmonary reserve and there is no N2 nodal involvement. Grade of recommendation, 1C

19. In patients who have a metachronous NSCLC and are being considered for curative surgical resection, invasive mediastinal staging and extrathoracic imaging (head CT/MRI plus either whole-body PET or abdominal CT plus bone scan) are recommended. Involvement of mediastinal nodes and/or metastatic disease represents a contraindication to resection. Grade of recommendation, 1C

Invasive med staging and extrathoracic imaging is recommended as N2 is considered a contraindication to surgery

molecular analysis, it is difficult to
are of the same histologic type as

on as synchronous second
ediastinal node involvement and
wo cancers are of the same

Shen et al Chest 2007

No consensus on staging

Whether staging should be based on a combination of all tumors with one TMN designation, or each tumor separately is ambiguous

- IASLC: “multiple synchronous primary tumors should be staged separately” “The highest T category and stage of disease should be assigned ” “Pts should be treated according to the stage of the highest one” including both same or different hystology
- American Joint Committee On Cancer (AJCC): ”The IASLC guideline implies that the TNM classification can be applied to both same and different histology between primary and secondary tumors”, but the AJCC guideline only fits for tumors with the same histological subtype.
- The 2012 manual of UICC (Union for International Cancer Control) suggests, “A tumor in the same organ with a different histologic type is counted as a new tumor”.

Detterbeck FC. How many names for a rose: inconsistent classi-fication of multiple foci of lung cancer due to ambiguous rules. Lung Cancer 2014



7° TNM Edition and SMPLC

Multiple tumor nodules in the same lobe reclassified from T4 to T3

Multiple tumor nodules in the same lung but different lobe reclassified from M1 to T4

Multiple tumors in contralateral lung as M1a

Category	6th Edition	7th Edition	Reason for Revision*
Tumor			
Size	T1: ≤3 cm	T1a: ≤2 cm	5-year survival rate = 77%
		T1b: >2 cm but ≤3 cm	5-year survival rate = 71%
	T2: >3 cm	T2a: >3 cm but ≤5 cm	5-year survival rate = 58%
	. . .	T2b: >5 cm but ≤7 cm	5-year survival rate = 49%
	. . .	T3: >7 cm	5-year survival rate = 35%
Tumor nodule(s) separate from primary mass			
Same lung and lobe as primary mass	T4 →	T3	5-year survival rate = 28% (similar to that for T3 and better than that for T4)
Same lung but not same lobe as primary mass	M1 →	T4	5-year survival rate = 22% (similar to that for T4)
Contralateral lung	M1 →	M1a	5-year survival rate = 3% (consistent with that for other intrathoracic metastatic disease)
Node			
Lymph node map	Lymph node staging primarily from the MD-ATS (Mountain-Dresler–American Thoracic Society) map	New IASLC lymph node map published (Fig 7)	New IASLC map reconciles differences between earlier lymph node maps and provides new descriptions of the nodal anatomy with respect to anatomic borders to ensure accurate localization of lymph nodes (cf Table 3)
Malignant pleural or pericardial effusion	T4	M1a	5-year survival rate = 2% (similar to that for tumors in the intrathoracic metastatic category, compared with a 5-year survival rate of 15% in other patients with T4 tumors
Metastasis			
Metastatic disease	M0: absent	M0: absent	. . .
	M1: present	M1a: local thoracic metastatic disease	Additional nodules in the contralateral lung (M1a) result in a median survival time of 10 months and a 1-year survival rate of 45%
			stases result in a
			time of 6 months
			vival rate of 22%

Stage of most patients remains too elevated

7th TNM examples

T3: same lobe

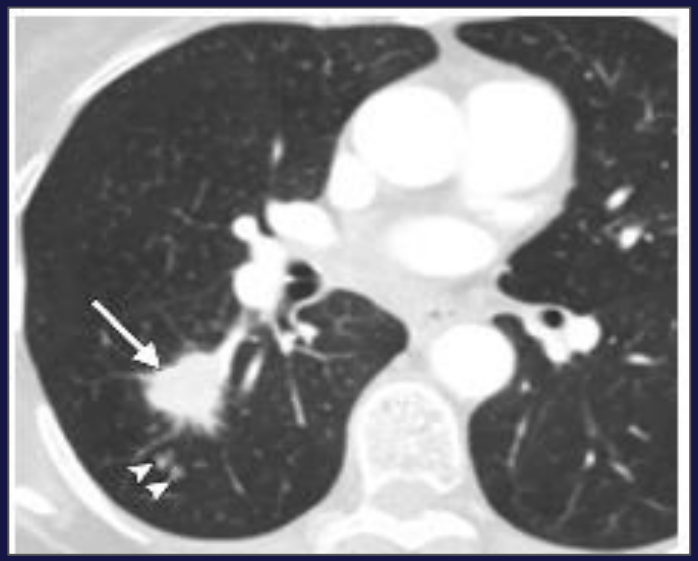

T 4: different lobes

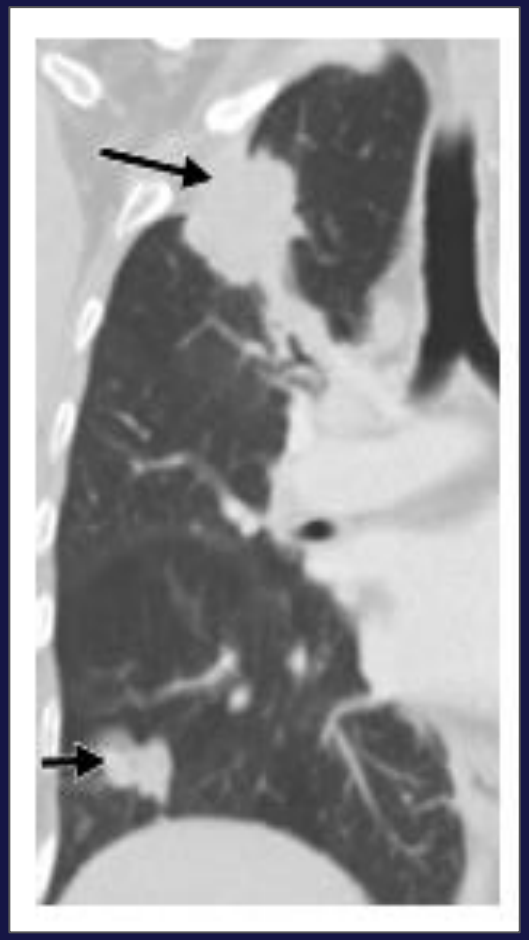

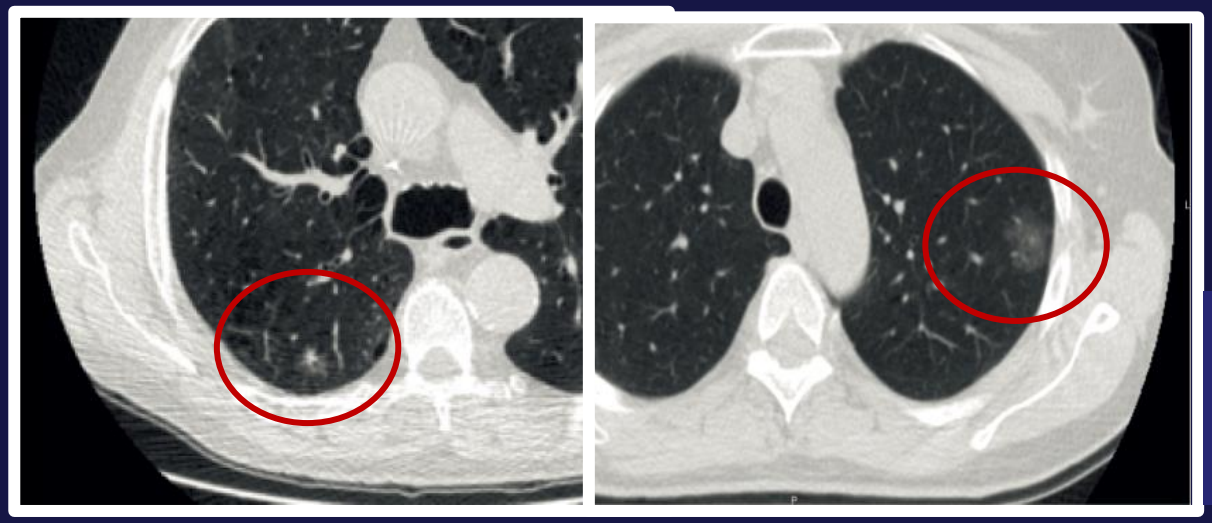

M1: different lung

Prognosis of synchronous and metachronous multiple primary lung cancers: Systematic review and meta-analysis

Long Jiang[a,b], Jiaxi He[a,b], Xiaoshun Shi[c], Jianfei Shen[a,b], Wenhua Liang[a,b], Chenglin Yang[a,b], Jianxing He[a,b,*]

Lung cancer 2014

- MPLC better OS than intrapulmonary metastasis
- No difference in OS whether same or different histology
- No difference in OS between unilateral and bilateral MPLT
- S-MPLC have shorter OS than M-MPLC patients from the diagnosis of first tumor, but same OS when started from the diagnosis of the second tumor

Conclusions MPLC metanalysis

Need of a MPLC staging system

Surgical approach is an option for pts with a new primary tumor

Still ambiguity in diagnosing the second primary cancer

ACCP: second primary tumor should be defined by an experienced multidisciplinary team

Jiang, Lung cancer 2014

Prognosis of SMLC : Unilateral versus Bilateral
Voltolini Let al. Eur J Cardiothorac Surg 2010

- 467 pts with resection of multifocal lung cancer in multiple lobes > poor prognostic factors: advanced age, male gender and unilateral tumour location

- bilateral cancers = more favourable prognosis > patients more likely to be those with true multiple cancers, and benefitting most from surgery because of non-metastatic disease.

Multiple Lung Cancers Prognosis: What About Histology?

Ann Thorac Surg 2008;

Marc Riquet, MD, PhD, Aurélie Cazes, MD, PhD, Karel Pfeuty, MD,

Table 1. Type of Resection of Multiple Lung Cancers According to the Location of the Tumors and N Status

	Major Resection[a]		Lesser Resection[a]		
Variable	n (%)	5-Year Survival[b] (months)	n (%)	5-Year Survival[b] (months)	*p* Value
MMLC	36 (46.8)	41 (39)	80 (54.4)	41 (39)	0.45
N0	24 (66.6)	46.8 (40)	65 (81.3)	44.2 (44)	0.82
N1	6 (16.7)	29.2 (6)	9 (11.3)	34.3 (20)	0.55
N2	6 (16.7)		6 (7.4)		
SMLC	41 (53.2)	21.2 (11)	67 (45.6)	25 (30)	0.067
N0	9 (22)	55.6/	36 (53.7)	34.2 (42)	0.83
N1	9 (22)	22.2 (12)	7 (10.5)	42.9 (27)	0.28
N2	23 (56)	9.2 (9)	24 (35.8)	8.3 (17)	0.51
Same lobe	15 (36.6)	20 (14)	42 (62.7)	33.4 (38)	0.13
Other lobe	26 (63.4)	6.6 (22)	25 (37.3)	24.3 (10)	0.57

Survival was similar for major or minor resection, same or different hystology , 2 or more than 2 nodules.
SMLC with more than 2 nodules were 13% of the cases and showed 5 yy srv of 40%
Conclusions: effort should be done to understand the nature of multiple nodules however surgery actually should be seriously considered for the treatment of Multiple lung nodules whatever metastatic or not

Deschamps J Thor Cardiovasc Surg 1990
Trousse J Thor Cardiovasc Surg 2007; Okumura J Thor Cardiovasc Surg 2001

Riquet 2008

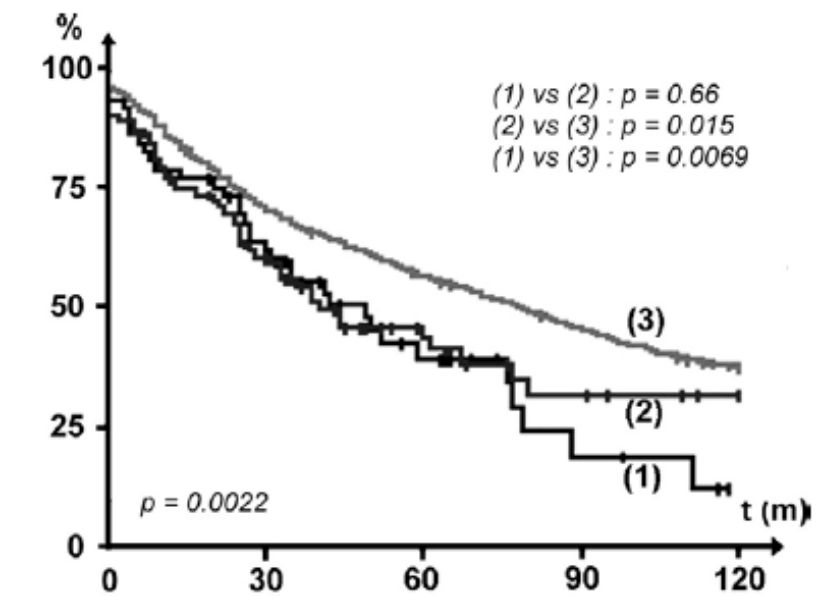

n	0	30	60	90	120
(3)	1495	984	660	417	221
(2)	89	44	20	11	5
(1)	55	33	15	5	1

Fig 3. Survival of lung cancer patients without lymph node involvement (N0) with either no prior malignancy (curve 3), multiple metachronous tumors (curve 2), or multiple synchronous tumors (curve 1).

N0 tumors

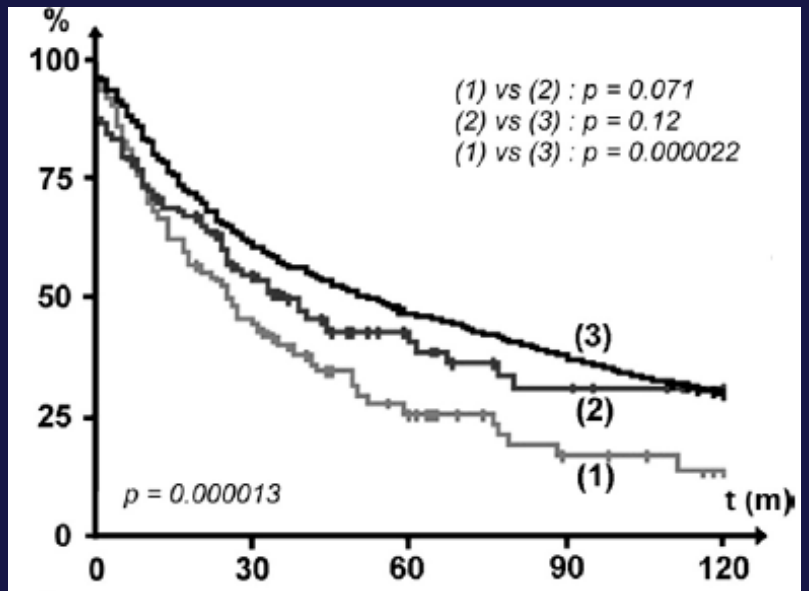

n	0	30	60	90	120
(3)	2696	1525	985	624	120
(2)	116	48	22	13	7
(1)	118	51	21	8	2

Fig 2. Survival of lung cancer patients without prior malignancy (curve 3), lung cancer patients with multiple metachronous tumors (curve 2), and lung cancer patients with multiple synchronous tumors (curve 1).

All tumors

3: LC
2: M-MPLC
1: S-MPLC

Riquet Ann Thorac Surg 2008

What is the optimal management of multifocal lung cancer?
2nd ESMO Consensus Conference: Ann Onc 2015

- Surgical data from retrospective analyses. Current evidence supports surgery as up-front approach for patients with SMLC in multiple lobes, either ipsilateral or contralateral.
- Recent studies of patients undergoing resection of multiple nodules – two synchronous tumours in most of cases – and without evidence of lymph nod**e** involvement have demonstrated 5-year survival rates greater than 50%
- No consensus exists on the optimal type of surgery for patients with multifocal lung cancer, although lobectomy for the main tumour plus sublobar resection of the smaller nodule(s) seems a reasonable approach
- If surgery is not feasible, other approaches such as local ablative (SABR) and/or systemic therapy should be considered. All treatment decisions should be taken within the context of a multidisciplinary tumour board.

- **What is the optimal management of multifocal lung cancer?** Complete resection is recommended whenever possible.

Does the extent of resection affect survival in patients with synchronous multiple primary lung cancers undergoing curative surgery?

Levon Toufektzian*, Rizwan Attia and Lukacs Veres

8 of 14 studies > no significant difference in OS and PFS when at least one sublobar resection (wedge resection or segmentectomy) was performed (613)

2 studies > absence of anatomical resection (in the form of lobectomy or bilobectomy) had a negative impact on survival (n = 210)

Single-Stage Surgical Treatment of Synchronous Bilateral Multiple Lung Cancers

Mingyon Mun, MD, and Tadasu Kohno, MD

Department of Thoracic Surgery, Toranomon Hospital, Tokyo, Japan

Ann Thor Surg 2007

Extesion of resection	
Lobectomy and wedge	13
Segmentectomy and wedge	1
Bilateral wedge	5
Approach	
Sternotomy	5
Vats bilateral	13
Tumor type	
ADK	84
SCC	3

In conclusion, for a selected number of patients with SBMLC whose diagnosis was based on HRCT, single-stage bilateral surgical treatment may be associated with favorable outcomes in cases where complete resection of lesions is determined to be feasible. Patients with SBMLC also need careful follow-up after resection, however, owing to the possibility of development of new primary lesions or recurrences.

FDG PET and multiple tumors

PET with FDG reflects the metabolic activity and proliferative potential of malignant tumors, enable the selection of an appropriate extent of resection for each lesion in cases of multifocal lung denocarcinoma

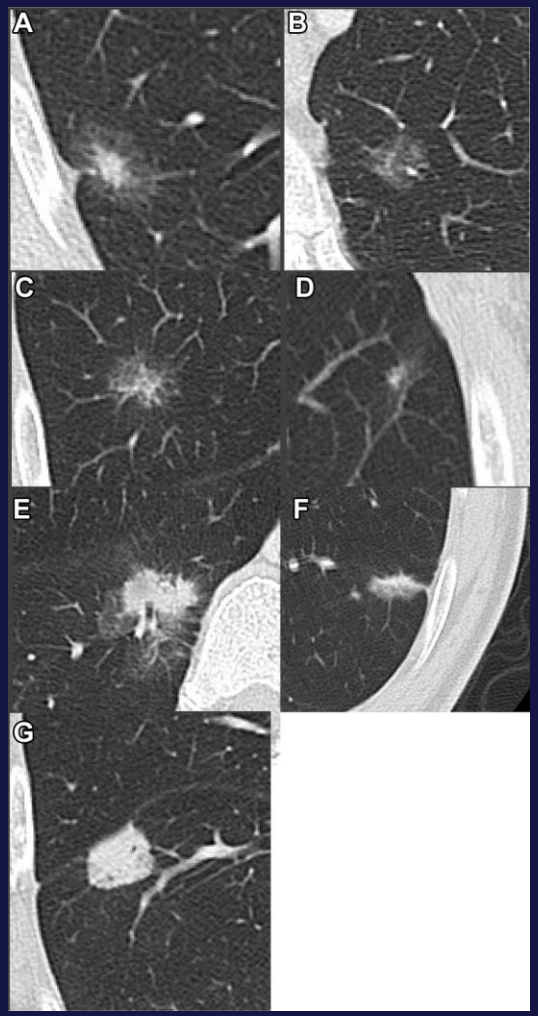

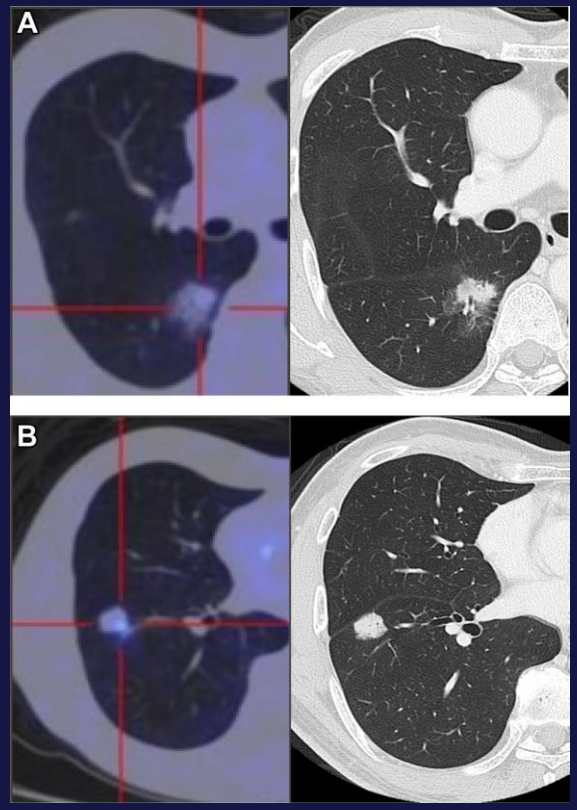

Yasuda M et al Ann Thor Surg 2014

NEXT GENERATION SEQUENCING

Next-generation sequencing of several cancers has revealed that solid tumors harbor tens to hundreds of somatic chromosomal rearrangements and thousands of single-nucleotide variations (SNVs).

Both of these types of alterations have been used to investigate lineage relationships in tumors from the same individual

Clinical use is still limited

CT SCREENING AND MPLC

10% of patients with a screen detected tumor had multifocal sinchronous disease at diagnosis

6% has developed a new primary tumor of the lung during 5 years.

These subjects, already having lung surgery, can badly tolerate a second surgery> limited resection or SABR for metachronous tumors

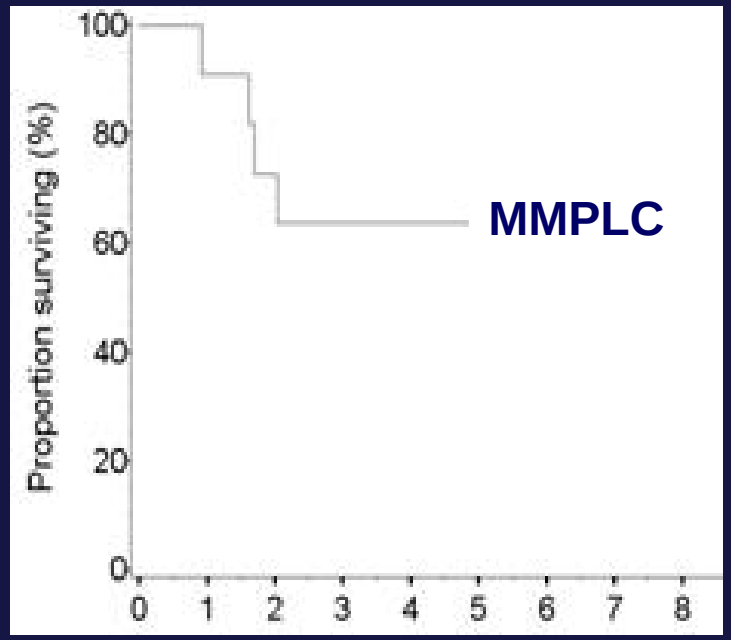

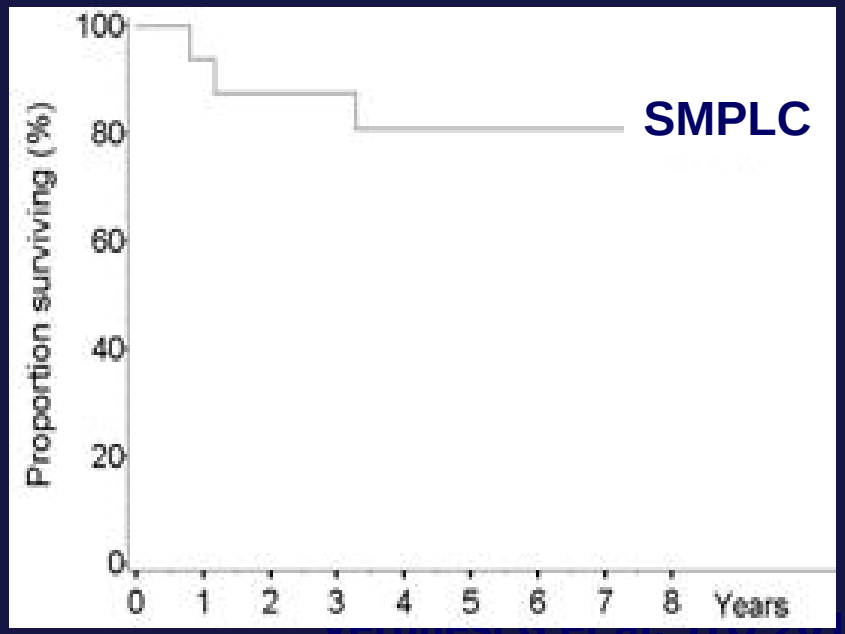

Veronesi et al JTO 2014

Clinical Statement on the Role of the Surgeon and Surgical Issues Relating to Computed Tomography Screening Programs for Lung Cancer*

Gaetano Rocco, MD (Chair), Mark S. Allen, MD, Nasser K. Altorki, MD,

Multiple, bilateral pure GGOs that are technically not completely resectable or in patients at high risk for surgical resection can be managed by radiologic surveillance, particularly when follow-up imaging has established stability or very slow growth.

Sometimes, one of these lesions shows an increase in size or in the solid component of the GGO while the other lesions remain stable. In this setting, the enlarging lesion should be treated independently as a presumed lung cancer.

Same-lobe malignant lesions are usually best managed by lobectomy.

When bilateral synchronous malignant lesions are present, the amount of cardiopulmonary reserve of each patient will determine the extent of lung resection

Annals Thoracic Surg 2013

Stereotactic Ablative Radiotherapy

Cancer 2013

A Potentially Curable Approach to Early Stage Multiple Primary Lung Cancer

Joe Y. Chang, MD, PhD[1]; Yung-Hsien Liu, MD[1†]; Zhengfei Zhu, MD, PhD[1†]; James W. Welsh, MD[1];

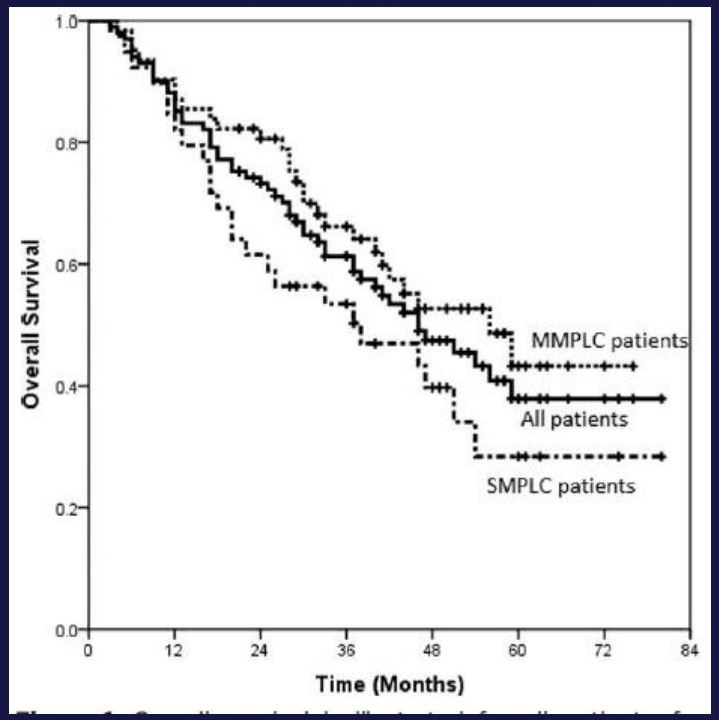

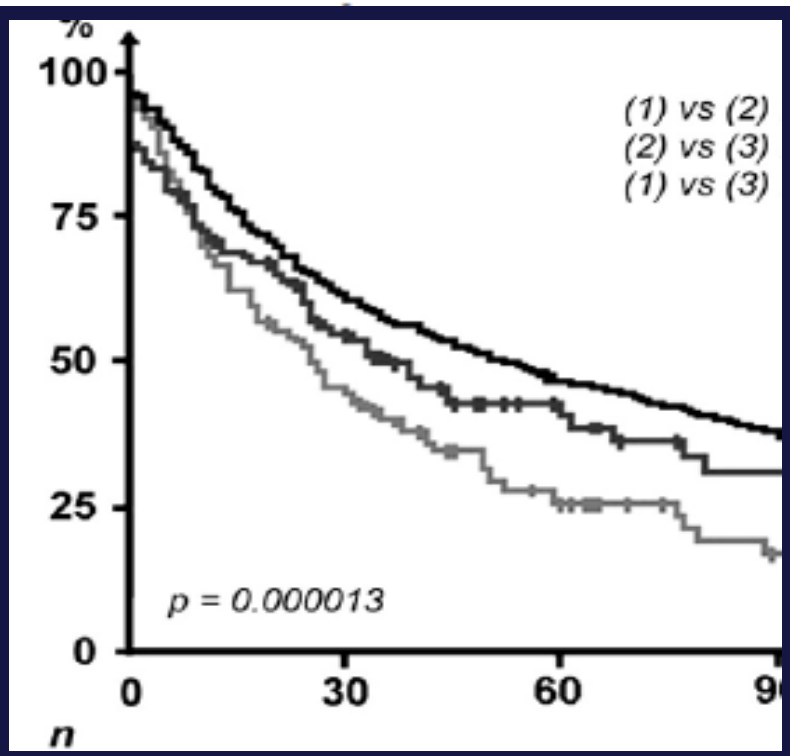

SABR

101 pts who received
for second primary

SURGERY **RIQUET ET AL**

SUMMARY

- Need of a MPLC staging system
- Ambiguity in diagnosing the second primary cancer
- Surgical resection is the primary treatment
- 5 years OS about 30%-50% pre screening era 65 to 80% among screen cancers
- Lobectomy plus sublobar resections seems a reasonable approach
- No difference according to number of lesions, whether histology is the same or different, if unilateral or bilateral MPLT
- PET of help to define the treatment strategy
- Sabr is a potentially curable alternative approach to surgery