superior sulcus tumours
the case for multidisciplinary approach

Dominique H. Grunenwald, MD, PhD

University of Paris VI. France



elcc

15-18 April 2015, Geneva, Switzerland

Organisers IASLC International Association for the Study of Lung Cancer; ESMO GOOD SCIENCE BETTER MEDICINE BEST PRACTICE European Society for Medical Oncology

Partners ESTRO European Society for RADIOTHERAPY & ONCOLOGY; European Society of Thoracic Surgeons 1993; etop Information | Research

conflict of interest

none

superior sulcus tumor

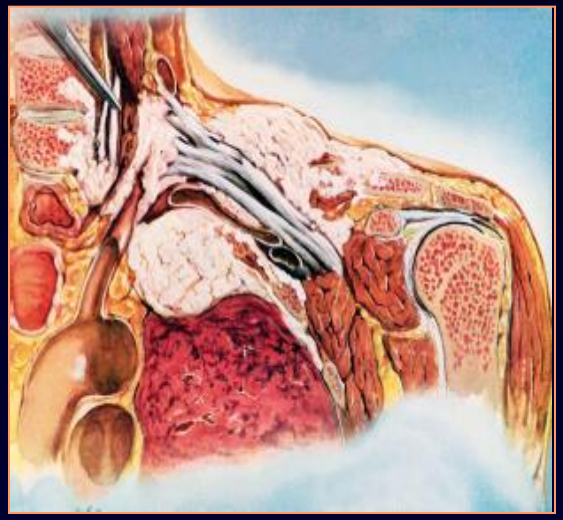

complex disease
poor incidence
absence of randomized studies
clinical model for multimodal strategies

multiple challenges

- <u>local control</u>
  - muscles (sternomastoid, scalenes),
  - ribs,
  - vertebral body,
  - subclavian vessels, phrenic nerve, brachial plexus
- <u>multidisciplinary surgery</u>
  - thoracic surgeon
  - neurosurgeon, or spine surgeon
  - head and neck surgeon
- <u>limits for adjuvant rt</u>
  - chord
  - esophagus
  - brachial plexus
- <u>systemic control</u>
  - incidence of distant relapses (brain)

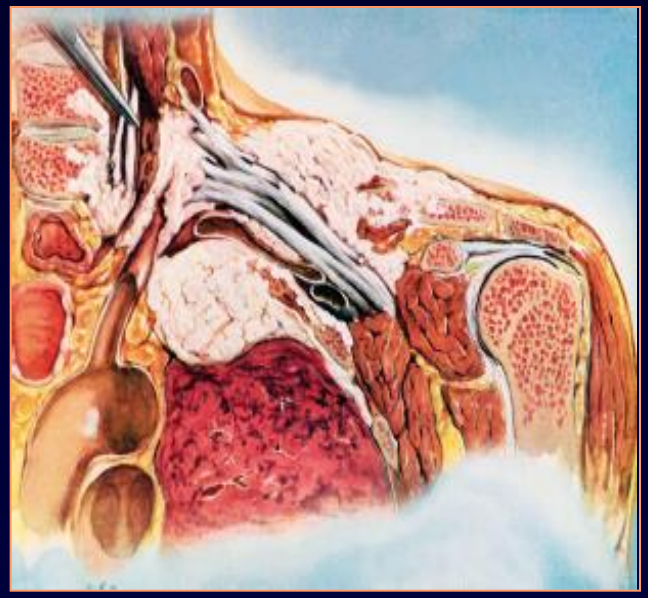

surgical history

1. 1932-1956 : non curable, inoperable
2. 1956-1990 : rt + surgery (posterolateral thoracotomy)
3. 1990-2000 : progress in surgical technique
4. from 2000 : induction rt-ct followed by surgery

Treatment of the Superior Sulcus Tumor by Irradiation Followed by Resection *

ROBERT R. SHAW, M.D., DONALD L. PAULSON, M.D.,
JOHN L. KEE, JR., M.D.

From the Thoracic Surgery Section, Baylor University Medical Center and Department of Surgery, Southwestern Medical School, Dallas, Texas

BRONCHOGENIC carcinomas that develop peripherally and invade the chest wall produce a painful syndrome that has been therapeutically difficult to control. The parietal pleura rather than being a barrier

from embryonal epithelial rests of the last branchial cleft. He suggested that they be called superior sulcus tumors although he admitted that better knowledge of the histopathology of the growth "may change

Ann Surg 1961;154:29-40

1961

Dr. Robert R. Shaw (1905-1992)

carcinomas in the superior pulmonary sulcus

preoperative irradiation and extended resection

eligible patients	**46**
surviving over 5 years	**34%**

Dr. Donald L. Paulson (1912-1999)

prognostic factors:

- **nodal involvement**
- **extent of the tumor**
- **pathological effects of preoperative irradiation in the resected specimens**

1975

DL Paulson J Thorac Cardiovasc Surg 1975;70:1095-104

"carcinomas of the superior pulmonary sulcus can be treated with extensive and intensive external irradiation with results equivalent to those of resection with or without preoperative irradiation" R. Komaki 1981

(Milwaukee, Wisconsin)

1981

5-yr survival = 23%

CANCERS PULMONAIRES DE L'APEX ENVAHISSANT LA PAROI

1984

D. GRUNENWALD, L. TOTY

GRUNENWALD D., TOTY L. — Cancers pulmonaires de l'apex envahissant la paroi. Résultats d'une enquête menée auprès des membres de la Société de Chirurgie Thoracique et Cardiovasculaire de Langue Fran-

dio-vasc., 1984, 38, n° 2, 85-87.

GRUNENWALD D., TOTY L. — Apical lung cancers invading the chest wall. The results of a survey of the members of the Society of French Speaking Thoracic and Cardiovascular Surgeons. *(In French).*

Ann. Chir. : Chir. thorac. cardio-vasc., 1984, 38, n° 2, 85-87.

Surgery upfront!

RESULTATS DE LA CHIRURGIE DES CANCERS PULMONAIRES AVEC SYNDROME DE PANCOAST ET TOBIAS

Une série homogène de 76 opérés

L. TOTY[1,2], D. GRUNENWALD[1], H. BAKDACH[1], A. COLCHEN[1], M. LEF C. PERSONNE[1], P. HERTZOG[2]

TOTY L., GRUNENWALD D., BAKDACH H., COLCHEN A., LEROY M., PERSONNE C., HERTZOG P. — Résultats de la chirurgie des cancers pulmonaires avec syndrome de Pancoast et Tobias. Une série homogène de 76 opérés.
Ann. Chir. : Chir. thorac. cardio-vasc., 1984, 38, n° 2, 96-100.

TOTY L., GRUNENWALD D., BAKDACH H., COLCHEN A., L PERSONNE C., HERTZOG P. — Results of the managem cancers with Pancoast syndrome. A homogeneous series of *(In French).*
Ann. Chir. : Chir. thorac. cardio-vasc., 1984, 38, n° 2, 96-

76 patients

CANCERS PULMONAIRES DE L'APEX ENVAHISSANT LA PAROI

1984

D. GRUNENWALD, L. TOTY

GRUNENWALD D., TOTY L. — Cancers pulmonaires de l'apex envahissant la paroi. Résultats d'une enquête menée auprès des membres de la Société de Chirurgie Thoracique et Cardiovasculaire de Langue Fran-

dio-vasc., 1984, 38, n° 2, 85-87.

GRUNENWALD D., TOTY L. — Apical lung cancers invading the chest wall. The results of a survey of the members of the Society of French Speaking Thoracic and Cardiovascular Surgeons. *(In French).*

Ann. Chir. : Chir. thorac. cardio-vasc., 1984, 38, n° 2, 85-87.

Surgery upfront!

RESULTATS DE LA CHIRURGIE DES CANCERS PULMONAIRES AVEC SYNDROME DE PANCOAST ET TOBIAS

Une série homogène de 76 opérés

L. TOTY[1,2], D. GRUNENWALD[1], H. BAKDACH[1], A. COLCHEN[1], M. LEF C. PERSONNE[1], P. HERTZOG[2]

TOTY L., GRUNENWALD D., BAKDACH H., COLCHEN A., LEROY M., PERSONNE C., HERTZOG P. — Résultats de la chirurgie des cancers pulmonaires avec syndrome de Pancoast et Tobias. Une série homogène de 76 opérés.
Ann. Chir. : Chir. thorac. cardio-vasc., 1984, 38, n° 2, 96-100.

TOTY L., GRUNENWALD D., BAKDACH H., COLCHEN A., L PERSONNE C., HERTZOG P. — Results of the managem cancers with Pancoast syndrome. A homogeneous series of *(In French).*
Ann. Chir. : Chir. thorac. cardio-vasc., 1984, 38, n° 2, 96-1

76 patients

5-yr survival → **4,2%**

classical posterior "Paulson's approach"

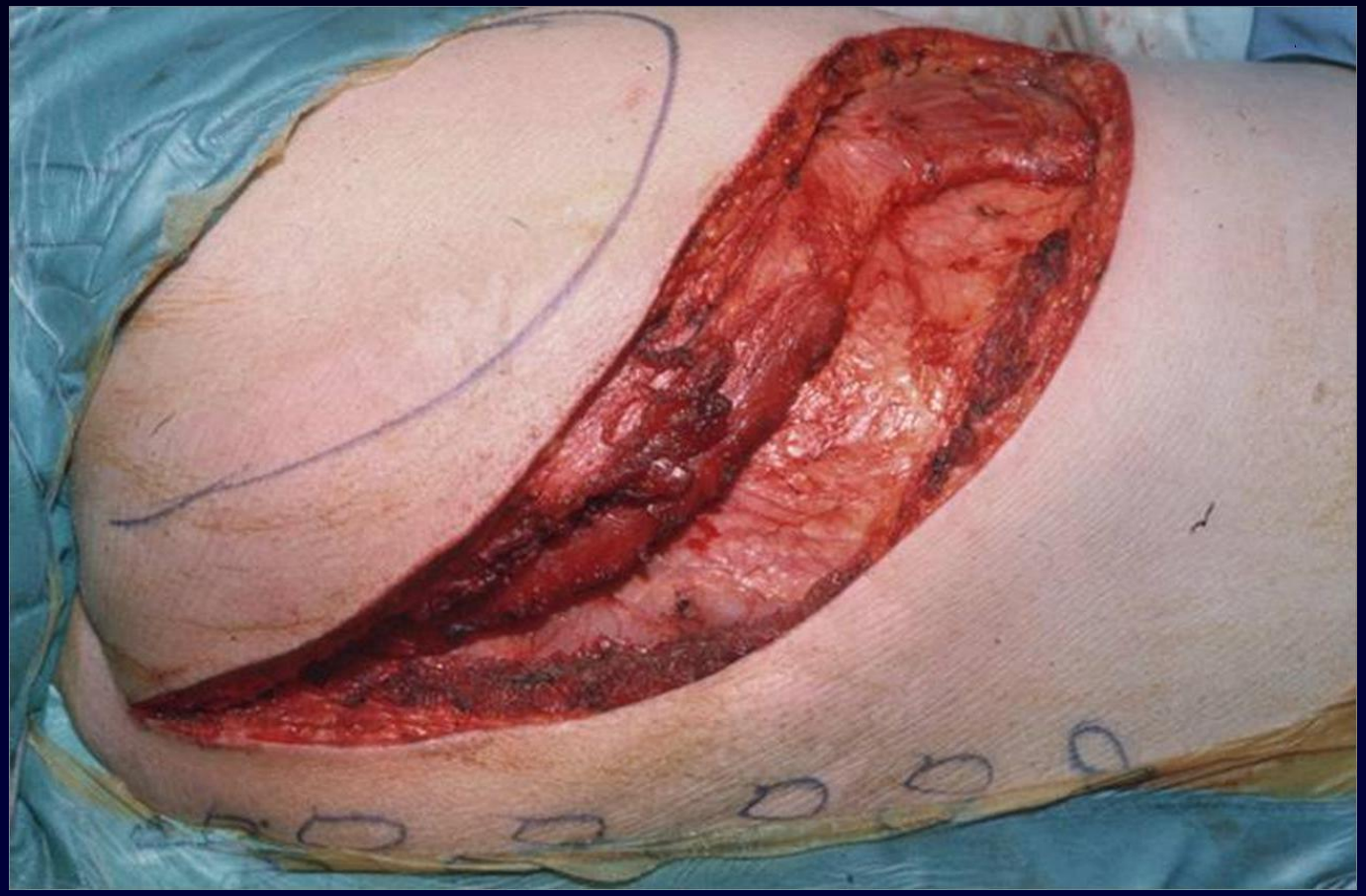

the thoracotomy incision is extended posteriorly and superiorly
division of the trapezius and rhomboid muscles

elevation of the scapula
exposure of the apical chest wall

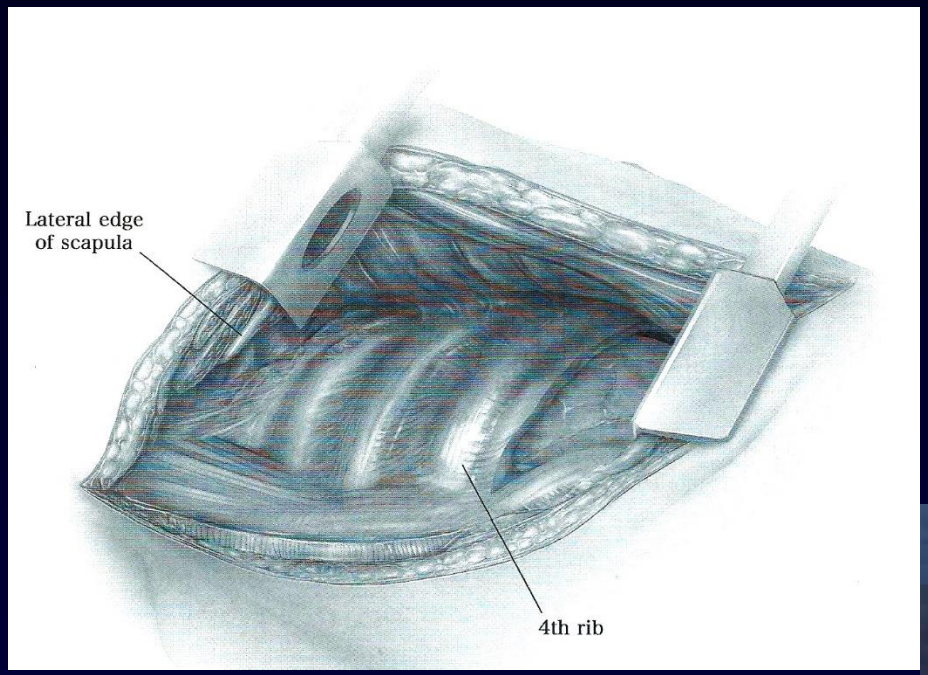

Operative techniques in thoracic and cardiovascular surgery 2011;16154-66

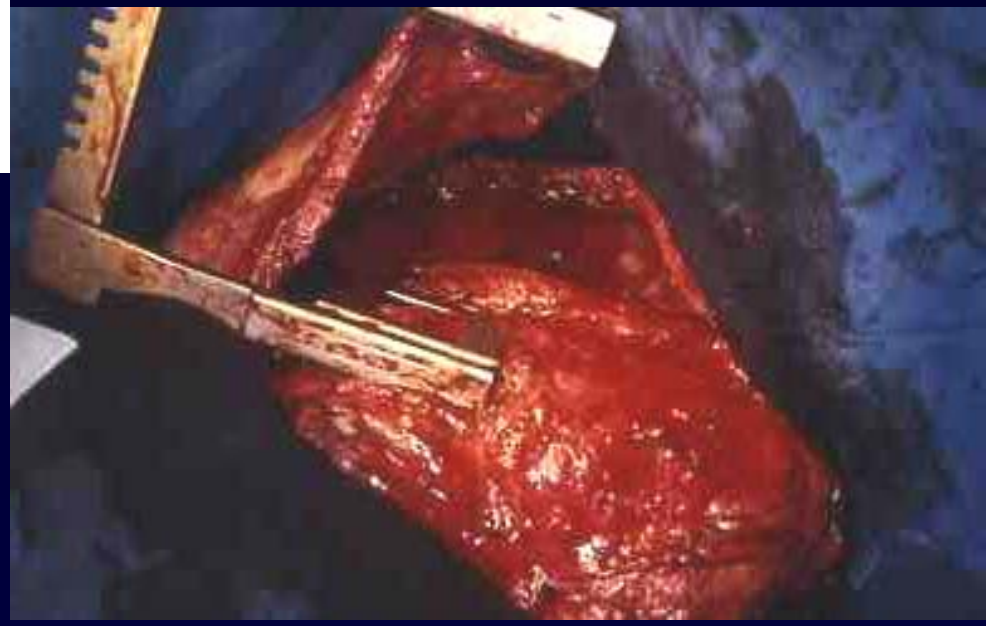

surgical absolute contraindications

supraclavicular vascular involvement

vertebral involvement

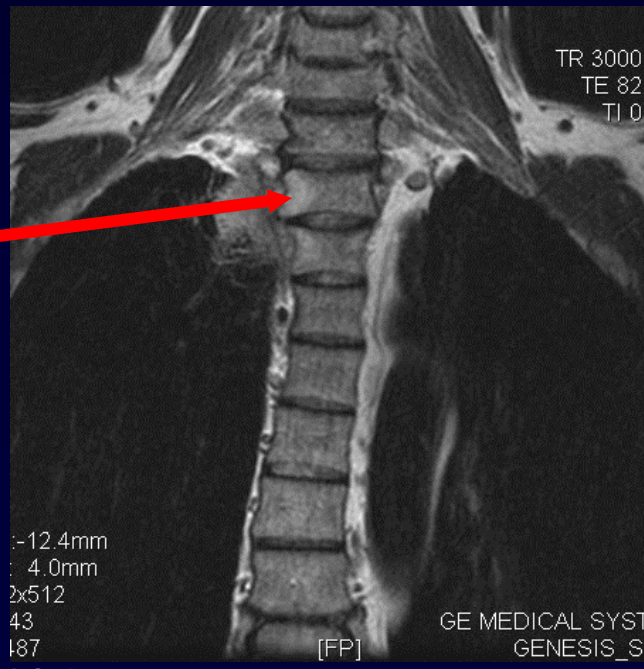

DL Paulson J Thorac Cardiovasc Surg 1975;70:1095-104

"control of locoregional disease remains the major challenge in treating lung cancers of the superior sulcus"

vw rusch, et al. 2000

surgical history

1. 1932-1956 : non curable, inoperable
2. 1956-1990 : rt + surgery (posterolateral thoracotomy)
3. **1990-2000 : progress in surgical technique**
4. from 2000 : induction rt-ct followed by surgery

anterior approaches

vertebral resections

anterior approaches allow vascular resections and reconstructions

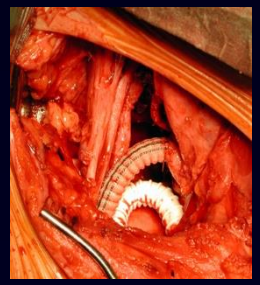

transcervical approach (clavicle resection) 1993

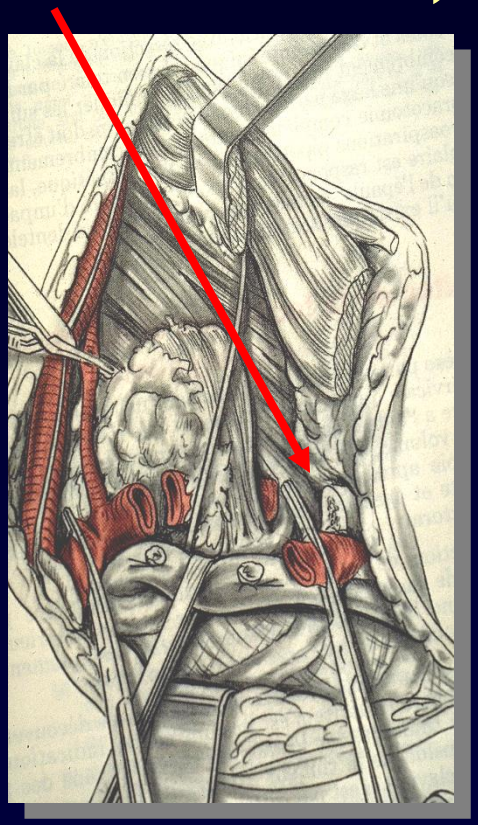

transmanubrial approach (sparing clavicle) 1997

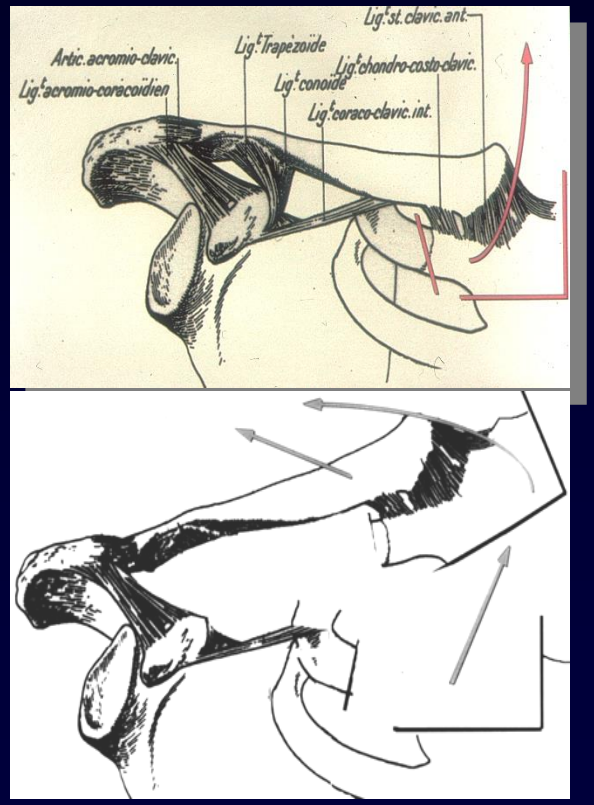

Dartevelle PG, et al. JTCS 1993;105:1025-34

Grunenwald D, et al. JTCS 1997;113:958-61

Ann Thorac Surg
1996;61:723–6

vertebral resections 1996

Total Vertebrectomy for En Bloc Resection of Lung Cancer Invading the Spine

Dominique Grunenwald, MD, Christian Mazel, MD,

the section of the chest wall in tumor-free margins, together with a wedge resection in the left upper lobe. The "resected" lung was left attached to the chest wall and spine in the pleural cavity. A complementary dissection to free the posterior mediastinum from the spine was also performed, and the thoracotomy was closed.

The last step to a complete en bloc resection was vertebrectomy through an enlarged posterior approach (6) (Fig 1). Briefly, the first stage is a laminectomy at the

no effraction of the tumor block

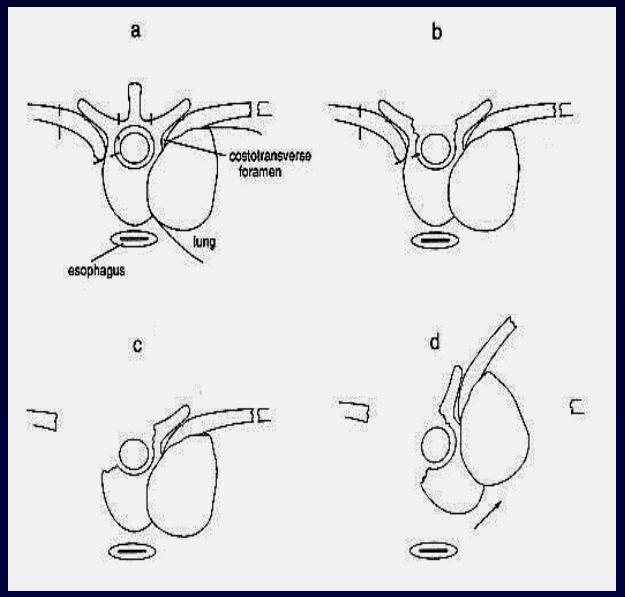

Grunenwald D, et al.
Ann Thorac Surg 1996;61:723-6

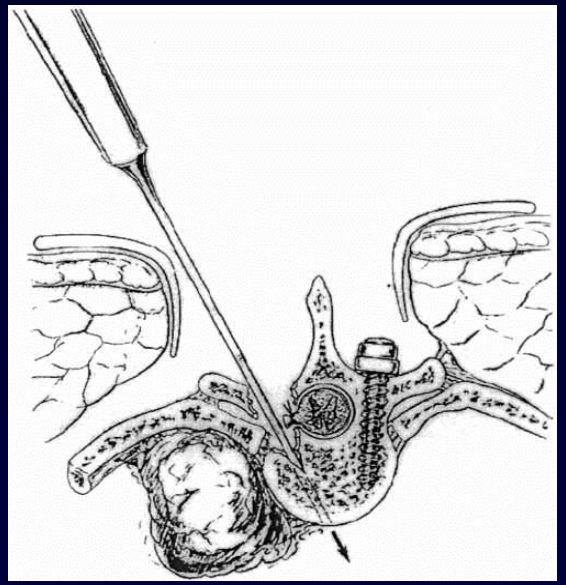

Grunenwald DH, et al.
JTCS 2002;123:271-9

superior sulcus tumor

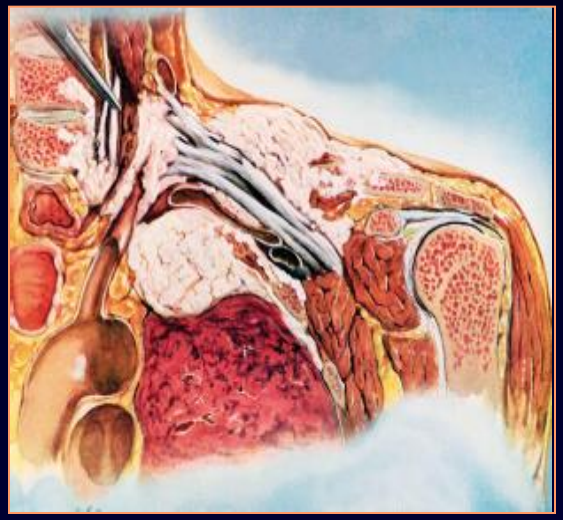

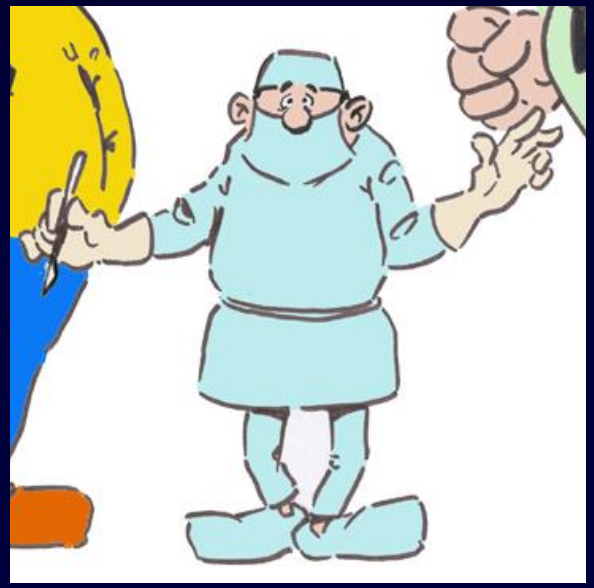

outcomes from surgery ?

results of induction therapy (predominantly rt) and surgical resection for nsclc of the superior sulcus

Author (y)	No.	Preop. tt	Compl. res. (%)	Loc.rec. (%)	5-yr surv. (%)
Paulson (1975)	61	RT	NS	NS	26
Attar (1979)	73	RT	48	NS	NS
Ginsberg (1994)	124	RT	56	72	26
Maggi (1994)	60	RT	60	15	17
Komaki (2000)	62	RT,RT-CT	53	NS	38
Hagan (1999)	34	RT	NS	20	33
Rusch (2000)	225	RT,RT-CT	56	40	29
Martinod (2003)	139	None, RT	81	31	35

Kent MS et al. Thorac Surg Clin 2004;14:217-28

resection of T3 and T4 lung cancers of the superior sulcus

retrospective review of 225 patients (24 yr)

preoperative RT	55%	
actuarial 5-year survival	IIB	46%
	IIIA	0
	IIIB	13%

2000

Rusch VW, et al. *JTCS 2000*

resection of T3 and T4 lung cancers of the superior sulcus

retrospective review of 225 patients (24 yr)

preoperative RT 55%

actuarial 5-year survival

IIB	46%
IIIA	0
IIIB	13%

carcinomas in the superior pulmonary sulcus

preoperative irradiation and extended resection

eligible patients	46
surviving over 5 years	34%

prognostic factors:
- nodal involvement
- extent of the tumor
- pathological effects of preoperative irradiation in the resected specimens

DL Paulson J Thorac Cardiovasc Surg 1975;70:1095-104

Rusch VW, et al. *JTCS 2000*

prognostic factors influencing survival

prognostic factor	*p value*
limited res. / lobectomy	.08
T4 / T3	.05
IR / CR	< .01
N1-2 / N0	< .01

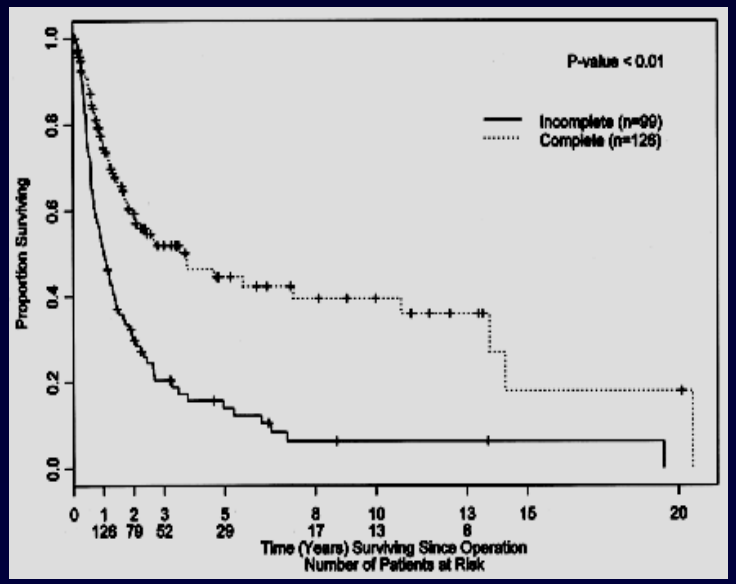

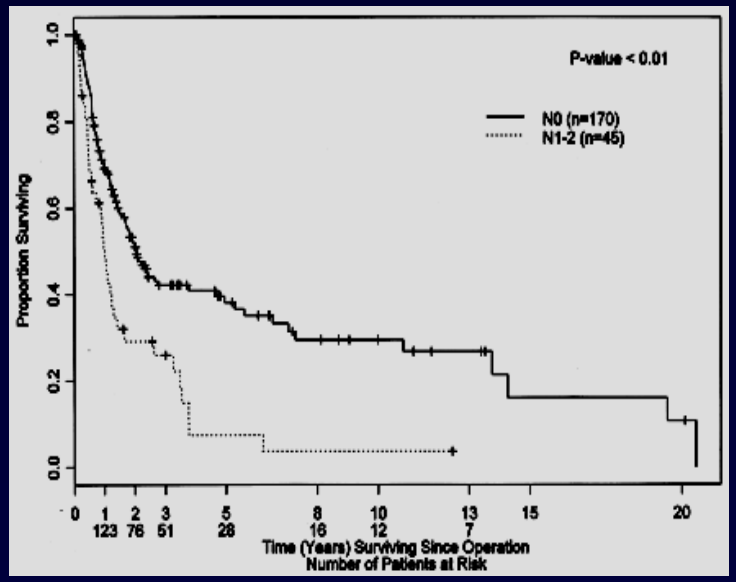

Rusch VW, et al. *JTCS 2000*

induction ct-rt and surgical resection for superior sulcus nsclc: long-term results of SWOG 9416 (Intergroup Trial 0160)

2007

T3-4, N0-1 SS nsclc
cis-eto x 2 and concurrent 45 Gy radiation
stable or responding disease → thoracotomy

thoracotomy		80%	(n=88)
complete resection		76%	(n=83)
path. CR or min. micr. d.		56%	(n=61)
5-yr surv.	all patients	44%	
	compl. resection	54%	

Rusch VW, et al. J Clin Oncol 2007; 25:313-8

induction chemotherapy, concurrent chemoradiation and surgery for Pancoast tumour

induction ct followed by concurrent ct-rt (45 Gy hfa)
surgery 4-6 weeks post-radiation
31 consecutive patients

grade 3-4 toxicity	32%
eligible for surgery	94% (n=29)
complete resection	**94%**
post-operative mortality	6.4%
major complications	20.6%
median survival	**54 months**
5-yr survival	46%

2007

Marra A, et al. Eur Respir J 2007;29:117-26 (Essen)

2 cycles of ct (mitomycin, vindesine, cisplatin)
concomittant radiotherapy (45 Gy)
thoracotomy 2 to 4 weeks after completion

(JCOG trial 9806)

surgical resection	57
pathol. compl. resection	51
pathol. compl. response	12
major postop. morbidity	8
treatment-related deaths	3
overall 5-yr survival	56%

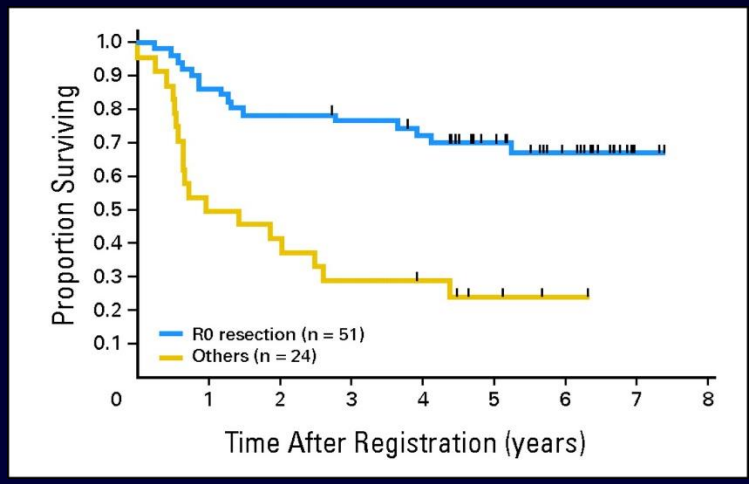

2008

Kunitoh H, et al. J Clin Oncol 2008;26,644-649

induction concurrent crt compared with induction rt for superior sulcus nsclc: a retrospective study

39 pts (induction followed by surgery)

2010

two groups

induction rt (1993-1999)
induction crt (since 1999)

	rt	crt	*p*
complete resection (%)	65	91	0.024
pCR from induction (%)	12	45	0.032
5-yr survival (%)	12	36	0.007
tumor-free surv. (mo.)	17	40	0.007

Li J, et al. Asia Pac J Clin Oncol 2010;6:57-65

induction concurrent crt compared with induction rt for superior sulcus nsclc: a retrospective study

39 pts (induction followed by surgery)

2010

two groups

induction rt (1993-1999)
induction crt (since 1999)

	rt	crt	*p*
complete resection (%)	65	91	0.024
pCR from induction (%)	12	45	0.032
5-yr survival (%)	12	36	0.007
tumor-free surv. (mo.)	17	40	0.007

Li J, et al. Asia Pac J Clin Oncol 2010;6:57-65

complete pathological response is predictive for clinical outcome after tri-modality therapy for carcinomas of the superior pulmonary sulcus

5-yr overall survival

pCR		**70%**	***p=0.001***
residual tumour		**20%**	
vital tumour cells	< 10%	65%	***p<0.001***
	>10 %	18 %	

a modification of the pathological staging system after radiotherapy, incorporating the percentage of vital tumour cells, is proposed

Blaauwgeers JL, et al. Virchows Arch 2013;462:547-56

carcinomas in the superior pulmonary sulcus

preoperative irradiation and extended resection

eligible patients	**46**
surviving over 5 years	**34%**

Dr. Donald L. Paulson (1912-1999)

prognostic factors:

- **nodal involvement**
- **extent of the tumor**
- **pathological effects of preoperative irradiation in the resected specimens**

1975

DL Paulson J Thorac Cardiovasc Surg 1975;70:1095-104

Pancoast tumor: a modern perspective on an old problem

Glassman LR, Hyman K. Curr Opin Pulm Med 2013;19:340-3

"with a multidisciplinary approach and the use of trimodality therapy this entity has evolved from a universally fatal disease to one that is treatable with outcomes similar to those of other stage-matched nsclc"

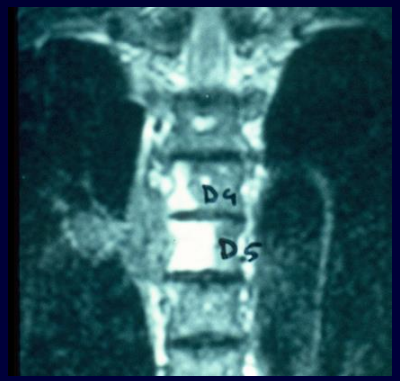

en bloc vertebrectomy / intralesional approach upfront surgery / induction rt-ct

	pers.	MDA	Toronto
yr	2006*	2009	2013
induction	none, ct	none	**ct-rt**
surg. technique	en bloc	intralesional	en bloc
pts	34	31	48
partial vert.	28	16	38
total vertebr.	6	15	10
R0 res. (%)	**88**	**56**	**88**
mortality (%)	3	5	6
5-yr surv. (%)	24	27	**61**

** unpublished*

special treatment issues in nsclc: diagnosis and management of lung cancer, 3rd ed: American College of Chest Physicians evidence-based clinical practice guidelines

in patients with a Pancoast tumor, a multimodality approach appears to be optimal, involving chemoradiotherapy and surgical resection, provided that appropriate staging has been carried out

Kozower BD1, Larner JM, Detterbeck FC, Jones DR. Chest 2013;143(5 Suppl):e369S-99S

trimodality therapy in Pancoast tumours unresolved questions :

1) role of PET-CT in restaging tumors

2) significance and implications of ipsilateral supraclavicular lymph node disease: N3 or "N1"?

3) downstaged N2 disease (trimodality treatment)

4) role of prophylactic cranial irradiation

5) role of high dose of RT (up to 60 Gy)

6) role of adjuvant postoperative chemotherapy

Parissis H, Young V. J Cardiothorac Surg 2010;5:102

"carcinomas of the superior pulmonary sulcus can be treated with extensive and intensive external irradiation with results equivalent to those of resection with or without preoperative irradiation" R. Komaki 1981

(Milwaukee, Wisconsin)

1981

5-yr survival = 23%

rior
e tre
exte
equi
r without
"

R. Komaki 1981

1990

"surgical resection should be used whenever possible for superior sulcus tumor"

R. Komaki 1990

(Houston, Tx)

CHAIRMAN'S ADDRESS

HENRY K. PANCOAST, M.D.

PHILADELPHIA

Medicine is not and cannot be an exact science because of the complexity of the human element involved. Roentgenology is the youngest branch of the specialties and is a study of living pathology. Even pathology is subject to many changes through experience, more progress in investigation and study. This is one