



Gastric Cancer



ESMO Preceptorship on Gastric Cancer

Michelle Silva

Hospital Prof. Dr. Fernando Fonseca, Portugal

11-10-2013

Case Study



- ❧ LAA
- ❧ 56 y old man, caucasian
- ❧ Personal history of mild hypertension and mild hyperlipidemia
- ❧ Family history of Gastric Cancer
 - ❧ Father died at 75 y old
 - ❧ Brother died at 61 y old
 - ❧ No other history of cancer

Case Study



∞ Asymptomatic, PS ECOG = 0

∞ **Physical examination:** normal

∞ Due to family history, underwent an

Esophagogastroduodenoscopy (09-03-2012):

Ulcerated lesion located on the lesser curve, 10 mm

∞ Biopsy: adenocarcinoma of stomach, diffuse type

Case Study

Work Up



❧ **CT scan of chest, abdomen and pelvis:**

- ❧ No evidence of regional lymph nodes
- ❧ No evidence of distant spread of disease

❧ **EUS:**

- ❧ uT2 N1

❧ **Laparoscopy with peritoneal washing:**

- ❧ Without macroscopic evidence of peritoneal carcinomatosis
- ❧ Peritoneal washing: cytology negative for malignant cells

Case Study



Diffuse Gastric ADC, stage IIA

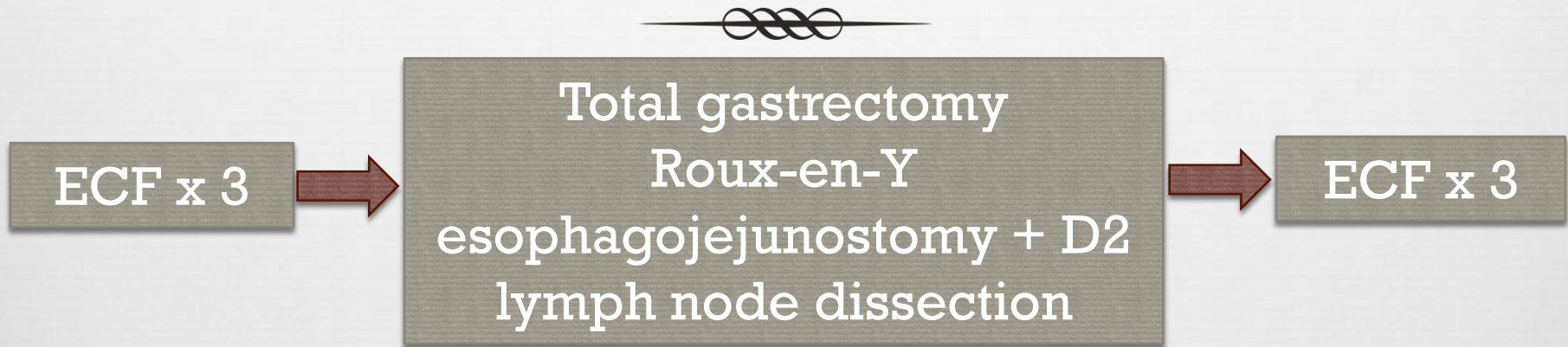
∞ Multidisciplinary evaluation:

PERIOPERATIVE CHEMOTHERAPY

→ MAGIC trial, *NEJM* 2006;355:11-20

Case Study:

Treatment



24-09-2013

- Undifferentiated adenocarcinoma
- Diffuse type
- No vascular or perineural invasion
- Surgical resection margins negative
- **ypT1a pN0**
- ***Chronic atrophic gastritis and complete metaplasia***

Case Study: Follow Up



- ❧ **Family referred to genetic counseling**

- ❧ 1 year later
 - ❧ Mild early satiety only
 - ❧ Weight loss ~15% after gastrectomy
 - ❧ Under vitamin B12 supplementation

- ❧ **No evidence of endoscopic and TDM recurrence**

[illegible]