CT-COLONOGRAPHY: EMERGING ROLE IN THE MANAGEMENT OF PATIENTS WITH STENOTIC COLORECTAL CANCER

M.J. Martínez-Sapiña Llanas, D. Domínguez Conde, C. Crespo García, A. Vega Chaves, A. Prado Prado.

Hospital Universitario A Coruña
A Coruña/ESPAÑA

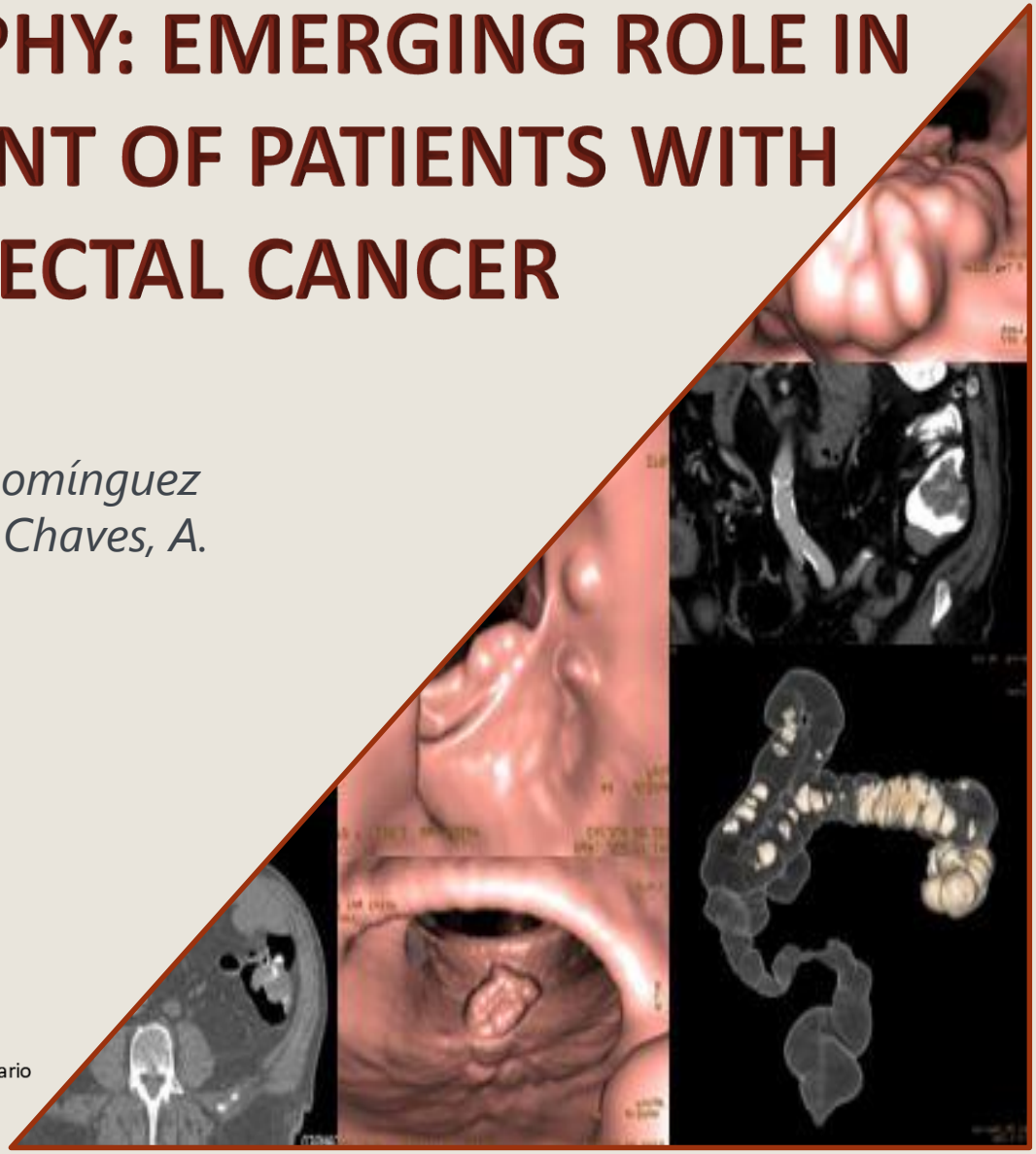

European Society ESGAR Gastrointestinal and Abdominal Radiology

SERVIZO GALEGO de SAÚDE | Complexo Hospitalario Universitario A Coruña

LEARNING OBJETIVES

Present the **indications and current utilities** of **CT-Colonography** in patients with **stenosing Colorectal Cancer** (CRC) and **incomplete Optical Colonoscopy** (OC) with its i**mplications** in the **surgical and post-surgical management of patients**.

BACKGROUND

.*Colorectal cancer **is the second most common cause of cancer related death** in the Western world. Prognosis and treatment depend on the disease stage at initial diagnosis.

.***An oncological resection** is the principal curative **treatment for colorectal cancer** and palliative surgery plays an important role in patients with incurable disease. 45% of patients with CRC have metastatic disease in their presentation.

.***Preoperative evaluation of the entire colon in patients with CRC is widely recommended** for a correct therapeutic plan. **A preoperative work-up** is aimed to exclude the presence of synchronous cancers, to evaluate local invasion and to detect nodal and distant metastasis. Moreover, **precise localization of the tumor is essential** for surgical treatment planning especially in the case of laparoscopic approach.

.*In patients with CRC, **a complete preoperative Optical Colonoscopy is a Standard part of patient evaluation prior to surgery.**

BACKGROUND

.* **Optical Colonoscopy (OC) is the study of choice for the evaluation of the entire colon in patients with CRC** but in **6 to 26% of cases it is incomplete**. **58.3%** of incomplete OC **are due to stenotic CCR.**

.* The most frequent cause of failure of a Preoperative Colonoscopy is luminal narrowing by a tumor. This particular scenario leaves the patient without adequate visualization and evaluation of the proximal colon to the stenotic CRC.

Stenosing CRC is defined as **Colorectal Cancer** diagnosed with OC and not able to be passed by the endoscopist due to stenosis of the lumen by the tumor, subsequently the colon proximal to the stenotic lesion is not evaluated.

BACKGROUND

.*Of all patients with CRC, **15 to 20 % present with stenosing lesion** and in more than 50% on the left side of the colon, increasing the length of the proximal colon not evaluated by OC. The recto-sigma is the most frequent location of the stenotic CRC.

.*Studies in the literature have reported rates of **synchronous carcinomas** ranging from **1,5 to 9 % and the presence of coexisting adenomatous polyps** in **27 to 55 % of patients with CRC.** Patients with synchronous cancers have a worse prognosis than patients with a single cancer (55% survival at 5 years), especially when the diagnosis and treatment of both tumors is not performed simultaneously.

.* **The diagnosis of a synchronous lesion may modify the extensiveness of the surgical procedure** and failure to diagnose may result in either a second surgery or the failure of curative treatment. If they are diagnosed before surgery, they can be treated during elective surgery, avoiding subsequent surgical procedures or they can be treated a posteriori with endoscopic resection. **Also it provides a better quality of life, as well as a cost-effective solution.**

BACKGROUND

.* **In the era of minimally invasive surgery**, accurate segmental localization of the CRC is important in determining the surgical technique.

.* **The segmental localization of the tumor with the Optical Colonoscopy is limited** since the anatomical marks may not be apparent and often the colonoscopists only provide the distance of the lesion from the anal margin and do not place it. **There are no marks between the sigma and the left colon or between the rectum and the sigma**. The colon can also be redundant, complicating the appropiate location. Lesions of the recto-sigmoid junction are often described in OC as rectal lesions, since the colonoscope can not pass beyond the stenosis.

BACKGROUND

.*Patients with CRC who undergo complete evaluation of the colon pre-operatively may **have less local recurrence**, **less chance of developing distant metastases** and a **longer disease-free survival** compared with patients who do not.

.***It is therefore necessary to evaluate the entire colon in patients with stenotic CRC and incomplete OC**. **A safe preoperative evaluation** allows planning the **Therapeutic Plan** which includes **Open or Laparoscopic Surgery**, **Radiotherapy** and **Chemotherapy.**

BACKGROUND

.* **CT-Colonography (CTC) is the imaging test recommended by most authors and scientific societies to exclude synchronous cancers in patients with incomplete OC** and stenotic cancers. It is an **emerging, relatively new, rapid, noninvasive** imaging technique developed for the screening of colorectal cancer and accepted for such use by the American Cancer Society (ACS) in 2008. **It is the best alternative to OC when it is incomplete or contraindicated**. The CTC is a well-tolerated, non-invasive, risk-free test (drilling risk 0.04%) and shows good results. In patients with CRC and incomplete OC, CTC is suitable for diagnosis with adequate distention of the colon in 83-100% of cases.

The increasing importance of CTC has been highlighted by its inclusion as a current CRC Screening Test Option in screening guidelines issued by several international organizations, including the American Cancer Society, A College of Radiology and US Multi-Society Task Force, The American College of Gastroenterology and Abdominal Radiology, USPreventive Services Task Force, European Society of Gastrointestinal Endoscopy, European Society of Gastrointestinal and Abdominal Radiology …

BACKGROUND

- **CT-Colonography represents a comprehensive examination for preoperative evaluation of patients with CRC**. In particular, it is accurate in the detection of significant colorectal lesions, enables evaluation of the entire colon, even in cases of obstructive lesions and allows segmental localization of the tumor. At the same time, **CTC permits staging of extra-colonic tumor spread**, both locoregional and distant.

- Studies in the literature have shown that in patients with CRC, **a CTC with complete colonic distension is achieved in 83 to 100% of the cases.**

BACKGROUND

Herein, we shall review the technique, benefits and limitations of CTC as a preoperative examination in patients with already diagnosed stenotic CRC and incomplete OC.

IMAGING FINDINGS AND PROCEDURE DETAILS

CTC Technique

REQUERIMENTS OF THE CTC

- A state-of-the-art examination requires **adequate bowel preparation**, **optimal colonic distension** and **proper scanning technique**. Moreover, in patients with diagnosed CRC, CTC must be performed with administration of intravenous-iodinated contrast media, as it allows extra-colonic organ evaluation, which is requested in search of distant metastases.

It is required :

- **MDCT of at least 8 rows** of detectors.
- **EXPERIMENTED radiologists** in CTC.
- **Specific COLONOGRAPHY software**.
- **Workstation DEDICATED**

IMAGING FINDINGS AND PROCEDURE DETAILS

Colonic Preparation for CTC

- ✓ It is obtained with a **three-day fiber-free diet.** The use of a cathartic agent (Magnesium Citrate, Sodium Picosulfate, Polyethylene glycol) is optional, but a non-cathartic preparation is preferable since it is better tolerated.
- ✓ It is advisable to drink **2 liters of water daily**, as a complement for the preparation.
- ✓ **Stool and fluid stainning is obtained with oral contrast**, iodinate or barium or both, from 2 days before the examination. Iodinated contrasts (diatrizoate) are the most frequently used; they mark the fluid and have a cathartic effect helping with fecal emulsion. Barium based contrasts also allow the staining of the stool.
- ✓ A local **microenema** is used early in the morning the day of exploration.
- ✓ Intramuscular or intravenous injection of an intestinal **relaxing drug** (Buscopan®) is optional. They are contraindication to it : glaucoma, prostatic hypertrophy, cardiac disease, myasthenia gravis and porphyria.
- ✓ Immediately before the test, patients are asked to **evacuate residual feces** and fluid that might remain in the rectum.

IMAGING FINDINGS AND PROCEDURE DETAILS

Acquirement parameters of CTC

Low dose protocols are followed

- ✓ Low dose technique (max 140 mAs, suggested under 50 mAs and 100 kV) with dose modulation and iterative reconstruction
- ✓ Thickness 1.25mm
- ✓ Standard reconstruction algorithm
- ✓ Rotation time : 0.5 s.

IMAGING FINDINGS AND PROCEDURE DETAILS

Colonic distension

- ✓ **A thin catheter** provided with a balloon is inserted in the rectum and moderately insufflated.
- ✓ **Automatic CO2** injector or manual injection of ambient air. Assesment of distension with supine and prone scout views. In patients with stenotic CRC, colonic insufflation must be gradually performed and carefully monitored using the topograms, since the risk of perforation exists, although it is extremely low (0,04%).
- ✓ **Acquisition of supine and prone series**. Optional lateral decubitus series when persistent underdistension is observed in supine and prono series
- ✓ If CRC staging is needed**, CTC can be performed with iv contrast** in the decubitus serie or perform a thoraco-abdomino-pelvic CT scan with contrast, immediately after CTC.

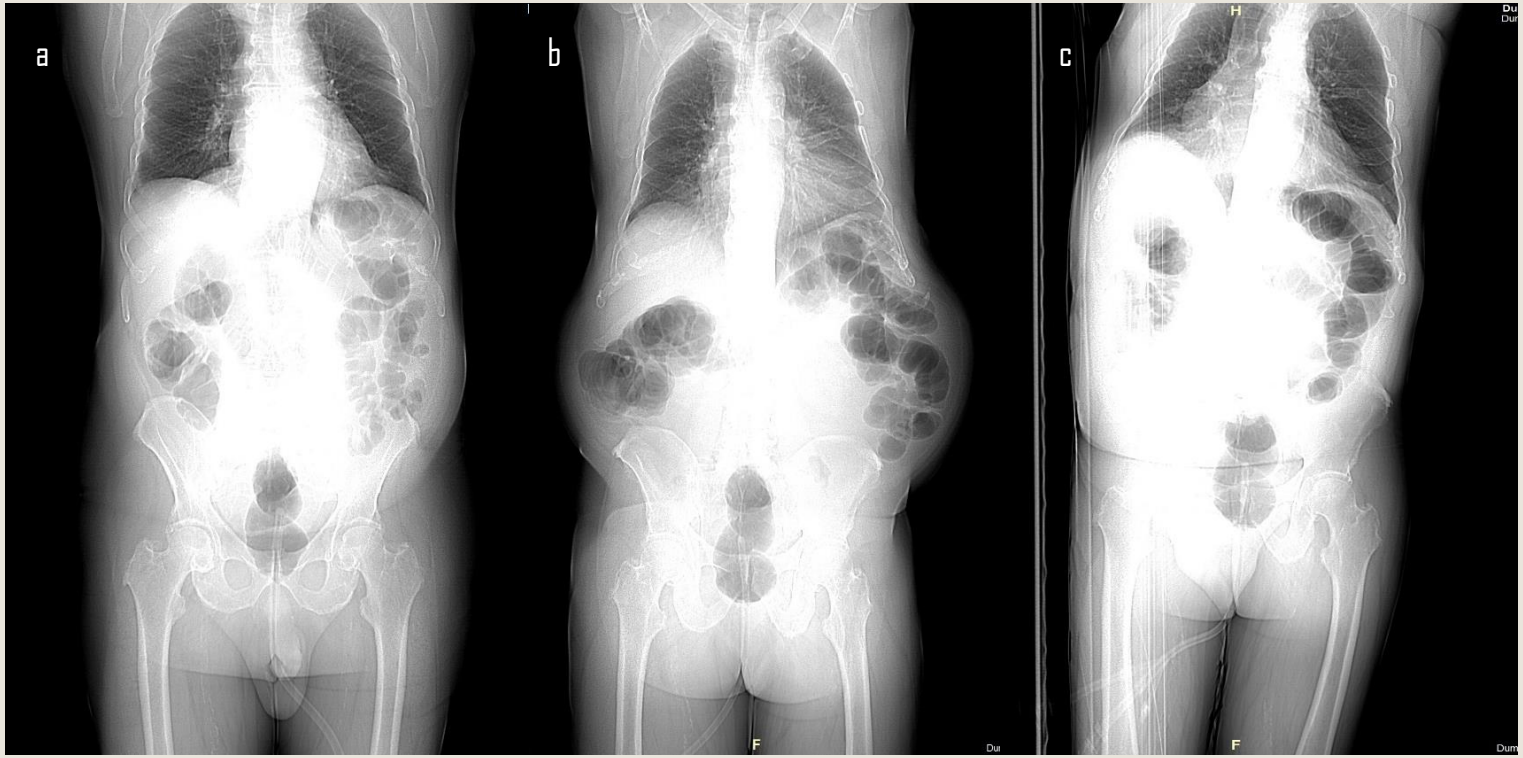

The image (a) shows a topogram in supine position with suboptimal distension. In (b) we can see a topogram in prono. In (c) the topogram is shown in the right lateral decubitus position. This topogram was performed to assess the underdistended areas in supine and prone position.

Technical considerations of the CTC

- ✓ All the images are transferred to a **Workstation with a specific Software**. 3D endoluminal navigation is performed in an antegrade and retrograde direction. 2D assessment of axial images and multiplanar reformatted (MPR) images is used.

- ✓ **The specific tools** that are used and help in diagnosis are: virtual dissection, virtual biopsy or translucency, second reading (CAD) and electronic cleaning of liquid and feces.

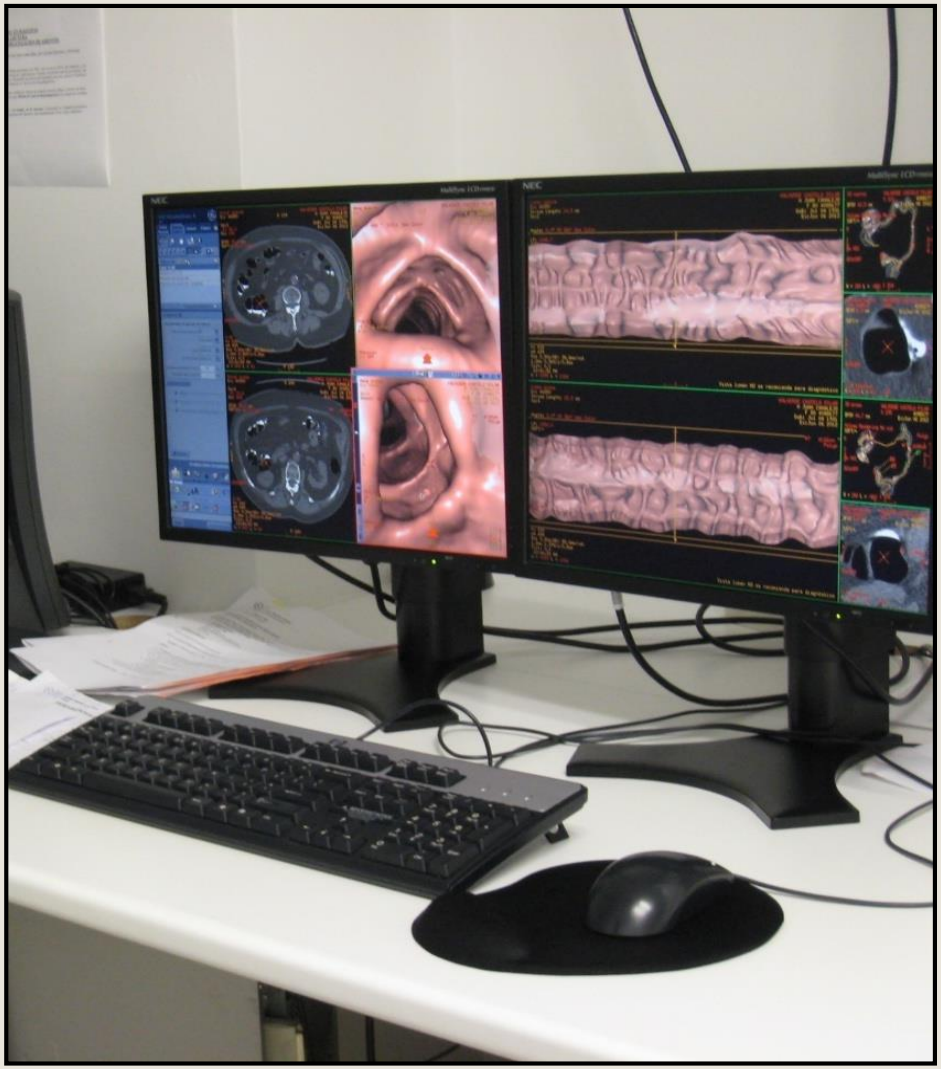

Workstation and specific software

IMAGING FINDINGS AND PROCEDURE DETAILS

CT-COLONOGRAPHY, in patients with CRC:

1.- Diagnoses the **presence or absence of synchronous lesions**.

2.- Allows **segmental localization of the primary tumor** and **synchronous lesions**.

3.- **Improves loco-regional staging** allowing to stage the disease and the extra-colonic tumor spread, both loco-regional and distant.

IMAGING FINDINGS AND PROCEDURE DETAILS

1.- CTC IN THE DIAGNOSIS OF SYNCHRONOUS LESIONS

- Synchronous lesions can be **cancers or polyps**. Studies in the literature have reported that **1.5 to 9 % of patients with CRC have synchronous carcinomas** and **27 to 55% have adenomatous polyps.**

- A search for Synchronous cancer is routinely performed during open surgery for CRC, but intra-operative palpation of the colon can miss up to 69% of Synchronous Cancer. Moreover, in case of the laparoscopic approach to CRC, the surgeon cannot explore the entire colon in a search for simultaneous lesions.

- **Missed diagnosis of synchronous cancer can lead to increased morbidity and progression of CRC to a more advanced stage.**

- In fact, **preoperative identification of synchronous cancer** implies a more **extended colonic resection** in 11 to 44% of cases, **avoids** the need for **second surgeries** and **prevents the growth of undiagnosed tumors** that would be in more advanced stages when they were later diagnosed. **Thus, for all these reasons, it is very important to perform preoperative CTC in patients with stenotic CRC and incomplete OC.**

IMAGING FINDINGS AND PROCEDURE DETAILS

1.- CTC IN THE DIAGNOSIS OF SYNCHRONOUS LESIONS

The morfological presentation of synchronous cancers in the CTC follows **three main patterns** (as the initial CRCs)**:**

1.-Broad-based intraluminal masses (the most frequent form of presentation).
2.-Polypoid or fungoid lesion.
3.-Annular lesion ("apple core sign"), which is the most frequent lesion associated with stenosis.

CTC has a high sensitivity to detect synchronous cancers, but limited ability to differentiate advanced adenomas from cancers. CTC is not able to differenciate between large adenomas and CRC. That is why some malignancy criteria are defined that will help us differentiate Cancer / Advanced Adenoma. **Considering that an advanced adenoma is a polypoid lesion** larger than 10mm with a villous component or high grade dysplasia.

Size is the main criterium to stratify the malignant potential of polypoid lesions.

IMAGING FINDINGS AND PROCEDURE DETAILS

1.- CTC IN THE DIAGNOSIS OF SYNCHRONOUS LESIONS

CTC Malignancy Criterium for Synchronous Lesions

- Lesion size >15 mm.
- Uneven lesion surface.
- Nodular margin.
- Pericolonic abnormality (infiltration, nodularity).
- Pericolonic lymph nodes.

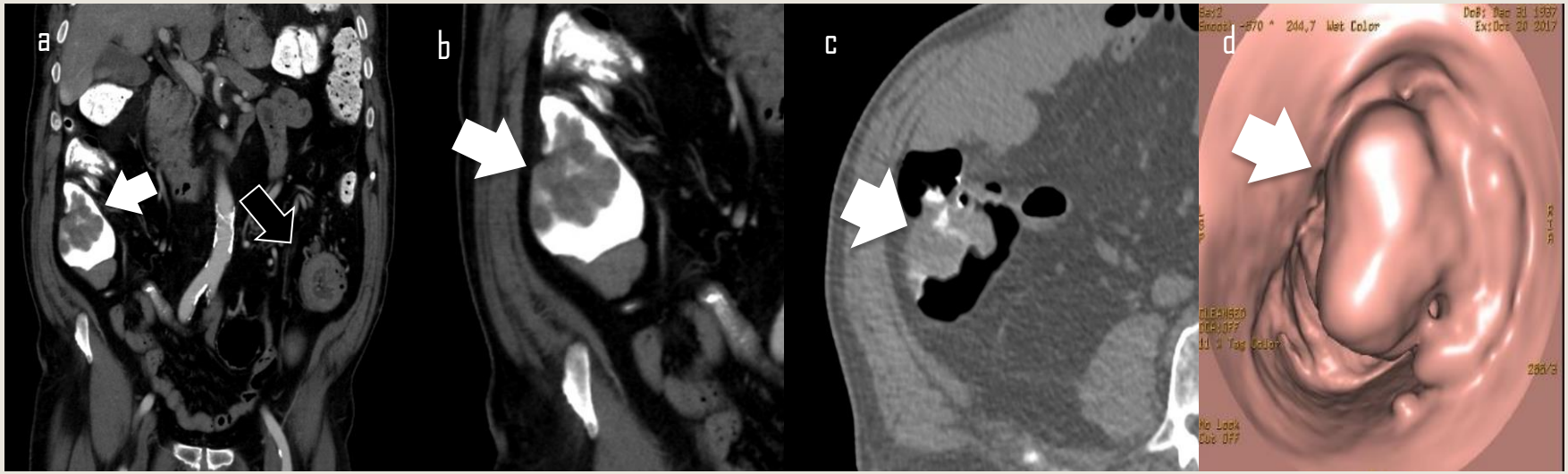

CRC and synchronous lesion. Stenotic CRC in the left colon diagnosed by incomplete OC. In the CTC, we can see a tumor in the left colon (black arrow in a) and a synchronous lesion of 4 cm in the cecum with smooth contours (white arrow in a, b, c and d). The lesion because of its size, could be classified as malignant, but the smooth contours and the “leafy appearance” suggest a villous type lesion. In the surgery it was demonstrated that the synchronous lesion was a tubulo-villous adenoma with low grade dysplasia and the stenotic left colon tumor was an adenocarcinoma.

Types of synchronous cancers

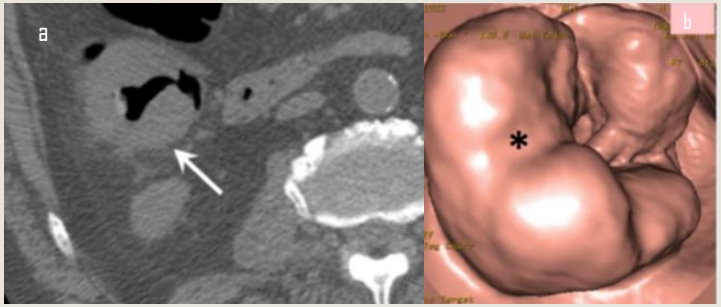

ENDOLUMINAL MASS OF BROAD-BASE.

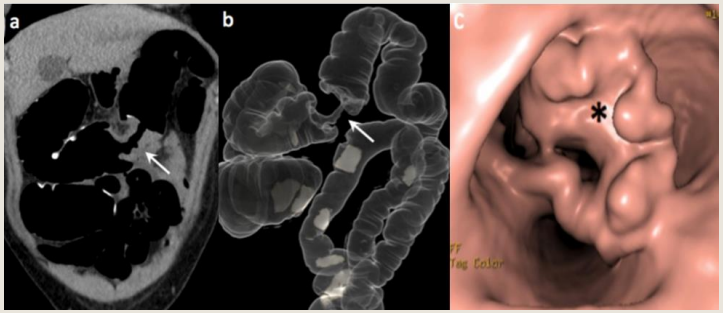

STENOSING CANCER

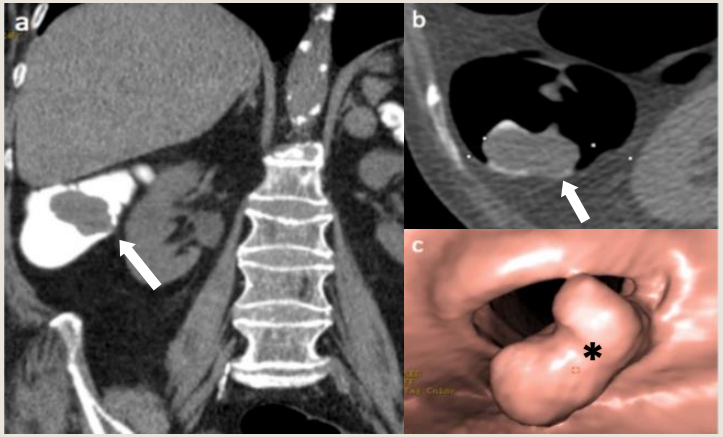

POLYPOID CANCER

IMAGING FINDINGS AND PROCEDURE DETAILS

1.- CTC IN THE DIAGNOSIS OF SYNCHRONOUS LESIONS

- **Studies in the literature has shown that CTC has high sensitivity for cancer and adenomas larger than 10 mm comparable to OC**: 96% for cancer; 84 to 92.2% for adenomas >10mm. With a **100% VPN for synchronous cancer**. The specificity is 69.8% for synchronous cancers and 78.8% for adenomas. The sensitivity of CTC for the detection of intermediate polyps (6-9mm) is 70%, lower than that of OC. The sensitivity for lesions <5mm is 48% also lower than the sensitivity of the OC (Park SH et al).

- **Synchronous cancers can be single or multiple** and can also present with polyps. In two thirds of the cases, the synchronous tumor is located in the same segment as the stenosing CRC. **The synchronous tumor** is usually **smaller** than the initial primary CRC **and** usually has a **lower staging.**

- **It is important to know that CTC can be performed in patients** with stenotic / obstructive lesions **treated with a metallic bowel stent.**

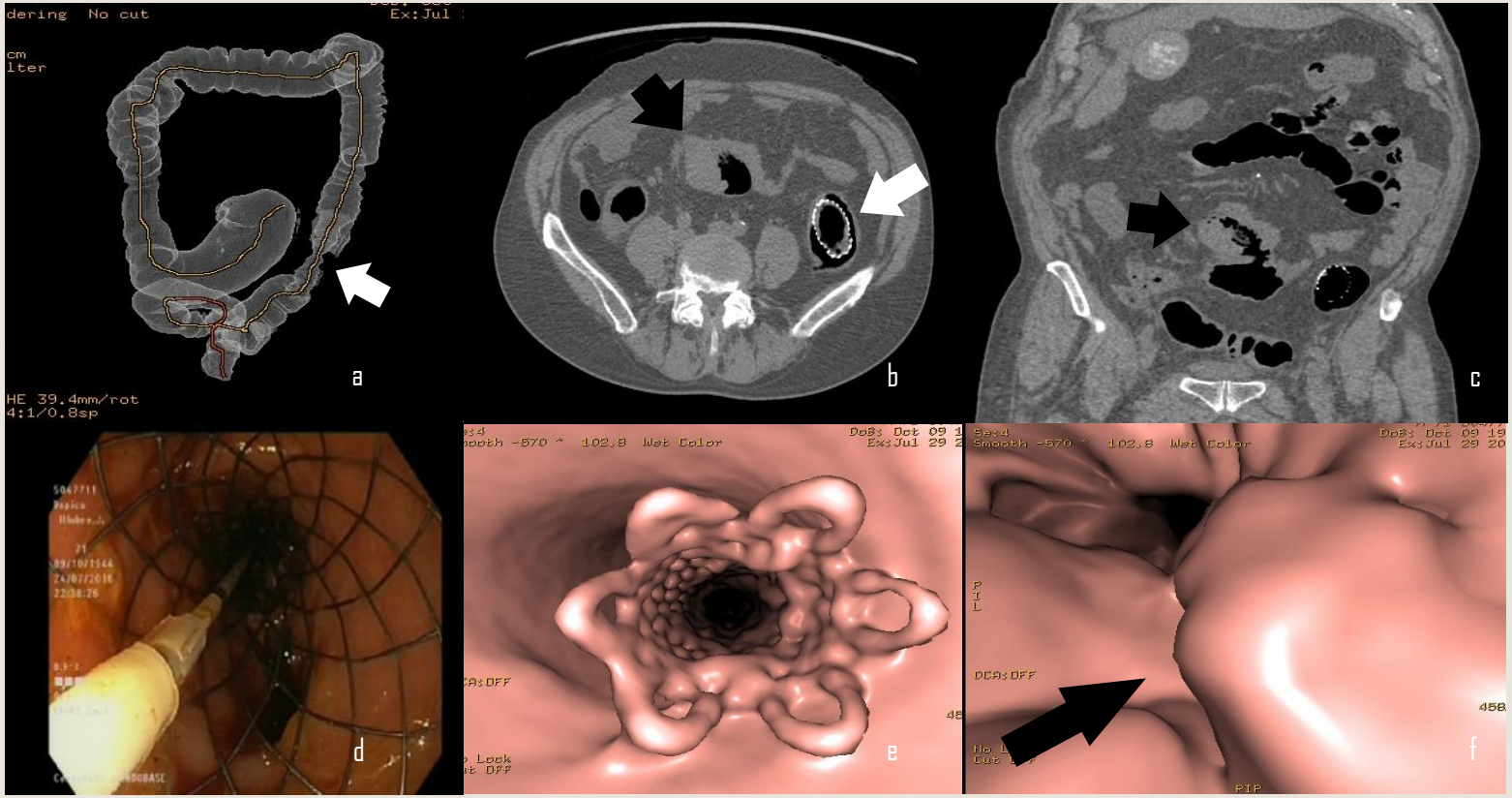

CRC with a metallic bowel stent and synchronous tumor. Patient with stenotic CRC in the left colon, treated the obstructive episode with the placement of a colonic stent, white arrows in the 3D luminogram (a), axial image (b), 3D endoluminal (e) and its correspondence with the OC (d). The patient had a second tumor in the cecum as can be seen in the axial image (b), coronal (c) marked with black arrows and in 3D endoluminal view (f).

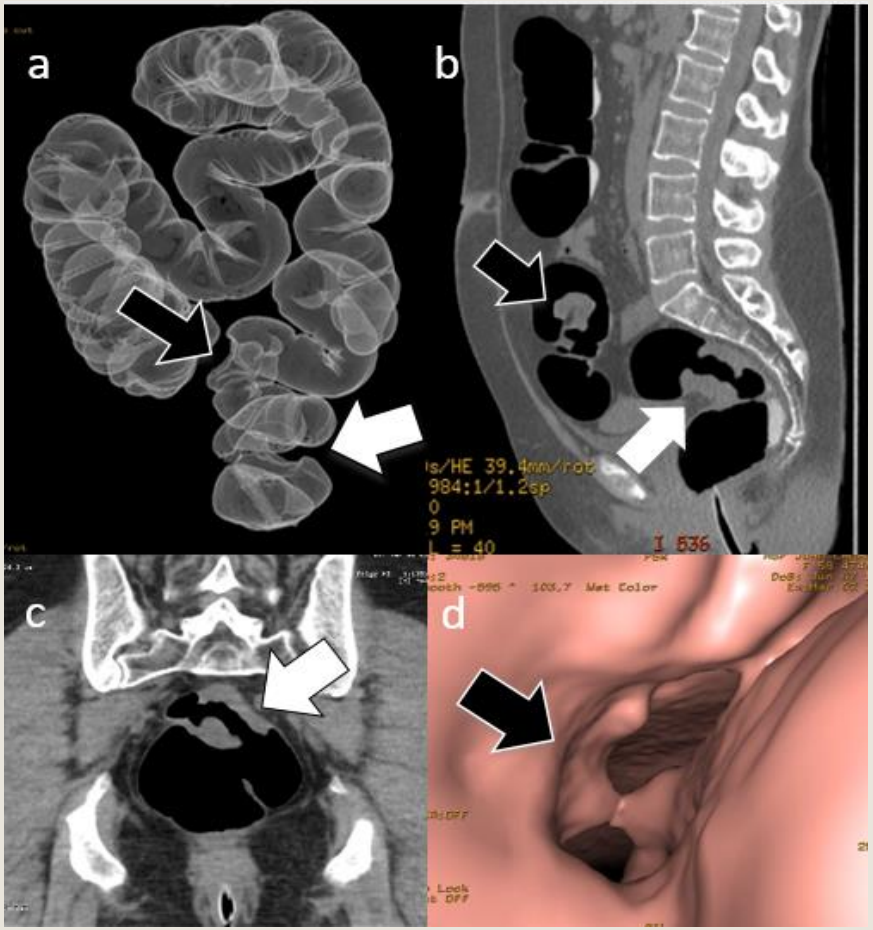

CRC and synchronous cancer. 70 year old patient with stenotic CRC in rectum-sigma, white arrows in a, b and c. In CTC views, a synchronous tumor was seen in the sigma (black arrows in a and b) smaller and non-occlusive, as seen in the 3D endoluminal view (d).

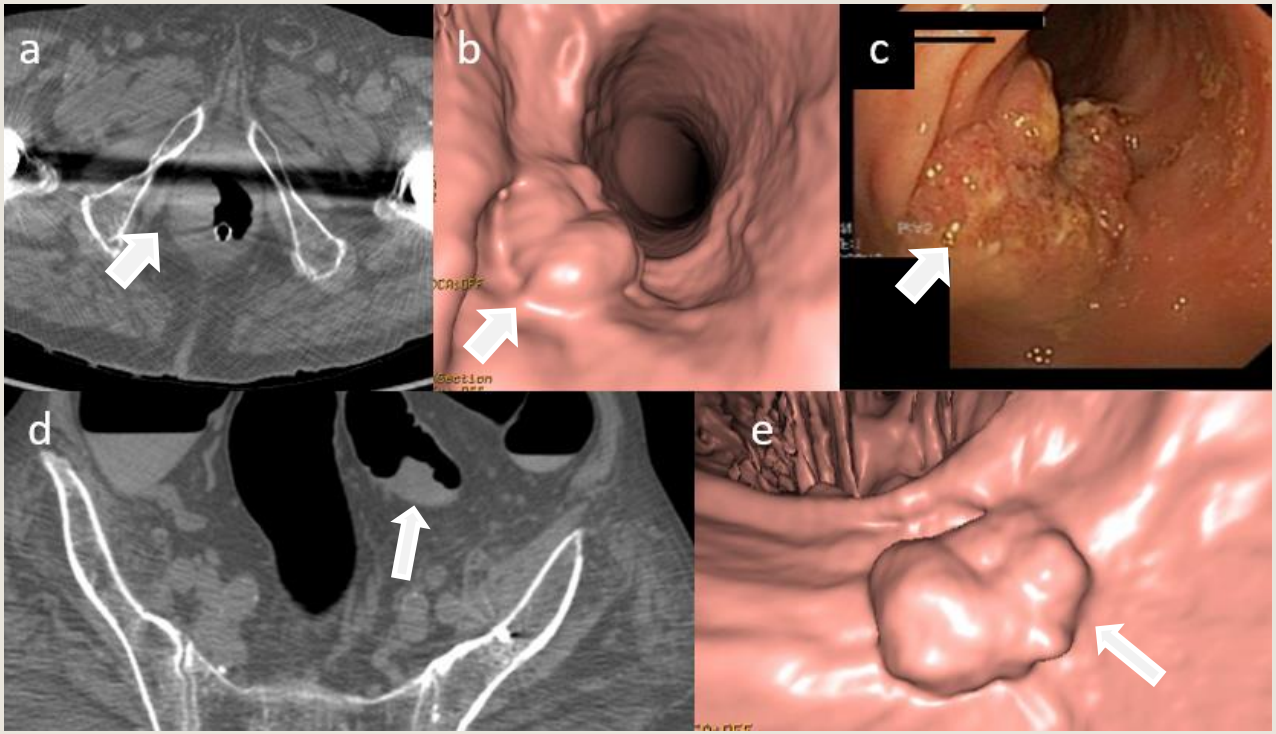

CRC and a single synchronous cancer. Patient with a stenotic cancer in the rectum and incomplete OC. In the axial image (white arrow in a), we can see the rectal lesion and also in the 3D endoluminal view (b). The same image in OC (c). The CTC detected another tumor in the sigma, as can be seen in the axial image (d) and in the 3D endoluminal view (e). The initial surgical plan, with an ultra-low rectal resection, was modified and an ultra-low anterior rectal resection with a sigmoidectomy was performed.

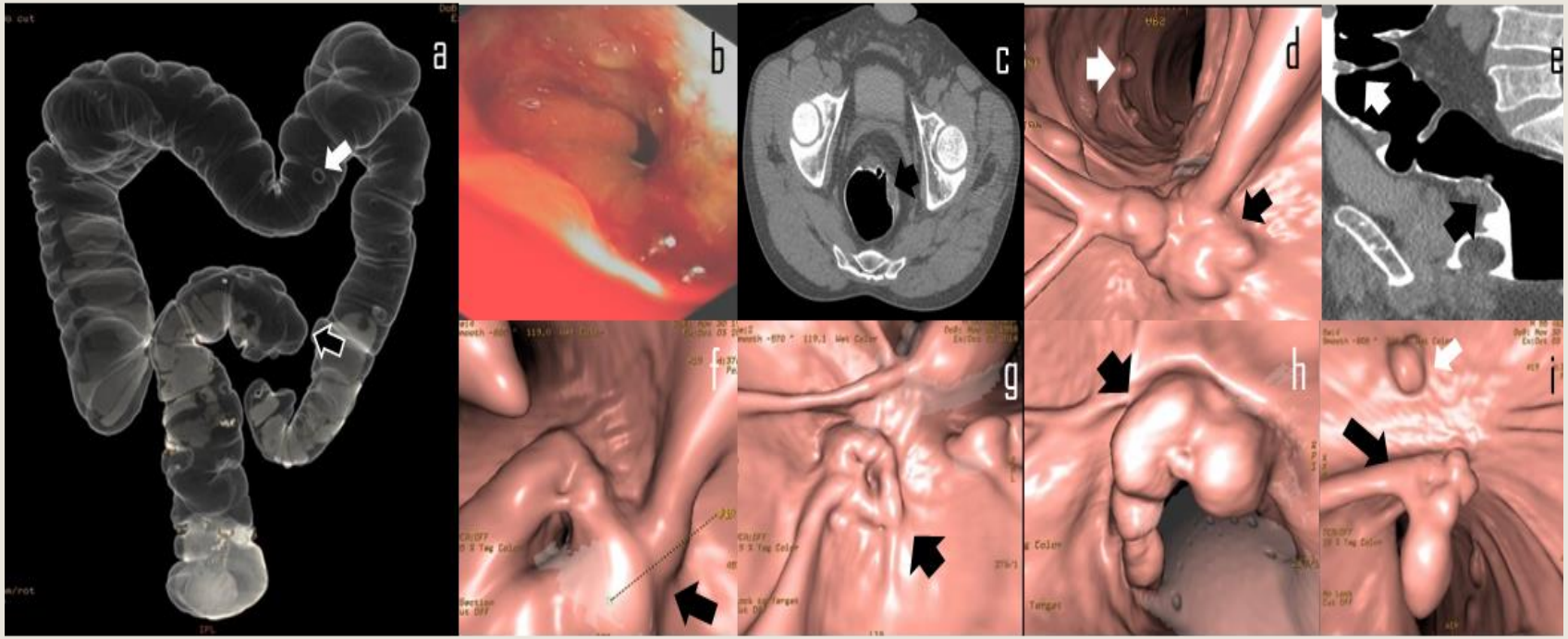

CCR and multiple synchronous cancers and polyps. Patient with colonic polyposis syndrome and incomplete OC due to a rectal neoplasia (b) and multiple polyps. In the axial image (c) and endoluminal 3D view image (d) a rectal neoplasm is seen (black arrow). The 3D luminogram (a) shows multiple polyps throughout the colon (white arrow), which are also seen in 2D (e) and 3D (d, i) reconstruction images (white arrows). Four synchronous carcinomas were detected, one in the cecum, two in the sigma and the fourth tumor in the transverse colon, visible in the sagittal image (e) and endoluminal images f, g, h and i (black arrows). A total Procto-colectomy was performed and all cancers were confirmed.

IMAGING FINDINGS AND PROCEDURE DETAILS

1.- CTC IN THE DIAGNOSIS OF SYNCHRONOUS LESIONS

- In **27 to 55% of patients** with stenotic CRC **adenomatous polyps are found.**
- **The management of polyps** detected in the CTC in patients with stenosing CRC is the same as recommended in the Guidelines of the ESGE-ESGAR 2014.

Management of polyps detected in CTC Guides ESGE and ESGAR, October 2014:

- Polyps ≥6 mm detected in CTC should be informed and Endoscopic Polypectomy should be suggested.
- Patients with one or two polyps of 6-9 mm but with contraindications to OC, surveillance with CTC can be a good alternative.
- Polyps >10 mm: Endoscopic Polypectomy.
- ESGAR suggest reporting all polyps >3mm, when they are clearly detected in the CTC.

IMAGING FINDINGS AND PROCEDURE DETAILS

1.- CTC IN THE DIAGNOSIS OF SYNCHRONOUS LESIONS

- **Polyps can be** sessile, pediculated, plane or carpet lesions, and the presence of multiple polyps in a patient is frequent.

- The treatment of polyps, will depend on their size, number and characteristics : they can be removed with Post-Surgical Early Endoscopic Polypectomy (1-6 months post-surgery) or by Surgical Approach, depending on the size, features and localization.

- **Surgical resection of synchronous polyps in patients with a CRC is preferable if they are close to the tumor or if the endoscopic removal is technically difficult. Another indication for surgical removal was an infavorable histophathologic finding of the endoscopic polipectomized specimen.** Many times, an extended colonic resection is required for the inclusion of polyps within surgical specimen.

In fact, **preoperative identification of synchronous lesions** implied a more **extended colonic resection in 11-44% of cases.**

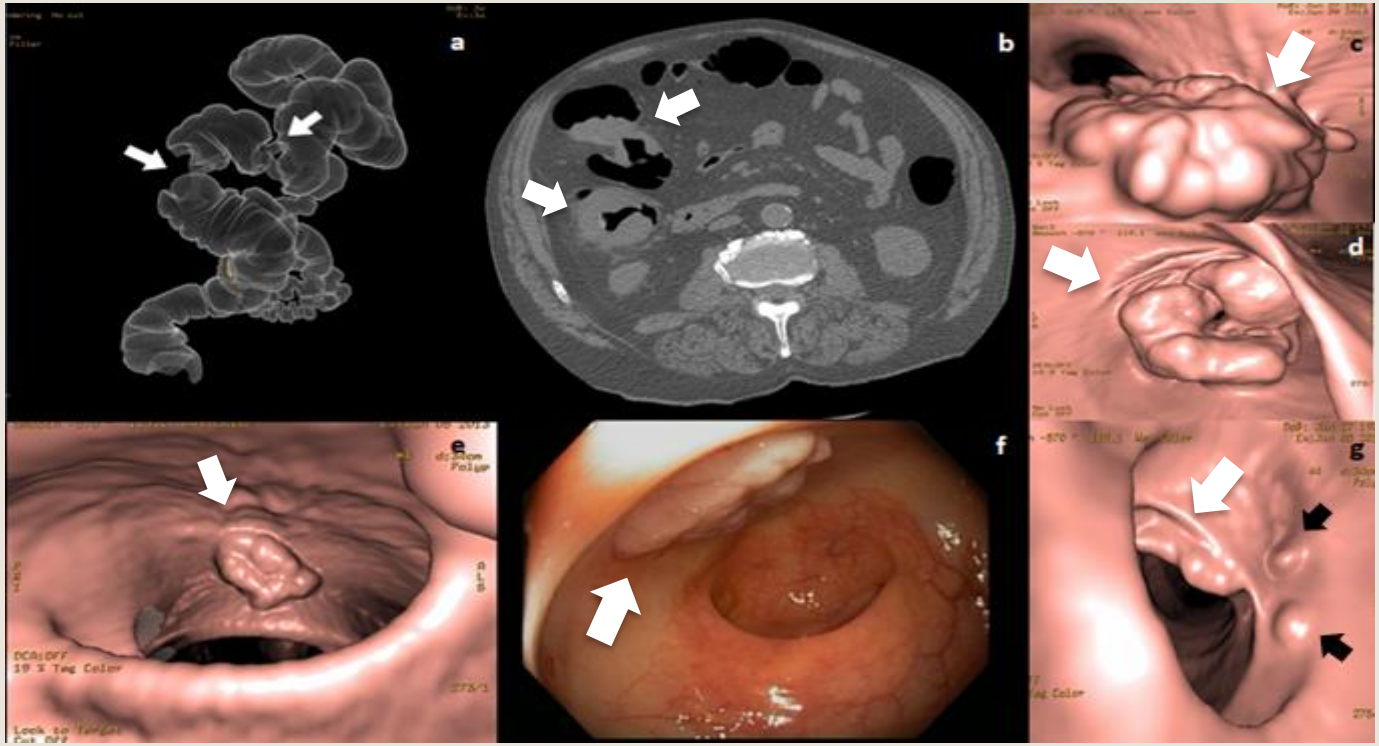

CRC and synchronous cancer and several polyps. In the 3D luminogram (a) and axial (b) and endoluminal images (c, d and g) we can see two cancers in the right colon (white arrows), one known by OC and the other is a synchronous cancer. We can see also two polyps near the second tumor (g) marked with black arrows. The patient also had a known rectal carpet lesion, as show in endoluminal (e) and OC (f) images marked with white arrows. An extended right colectomy was performed and the polyps were included in the surgical specimen. The carpet lesion was resected by Early Postoperative Endoscopic Polypectomy.

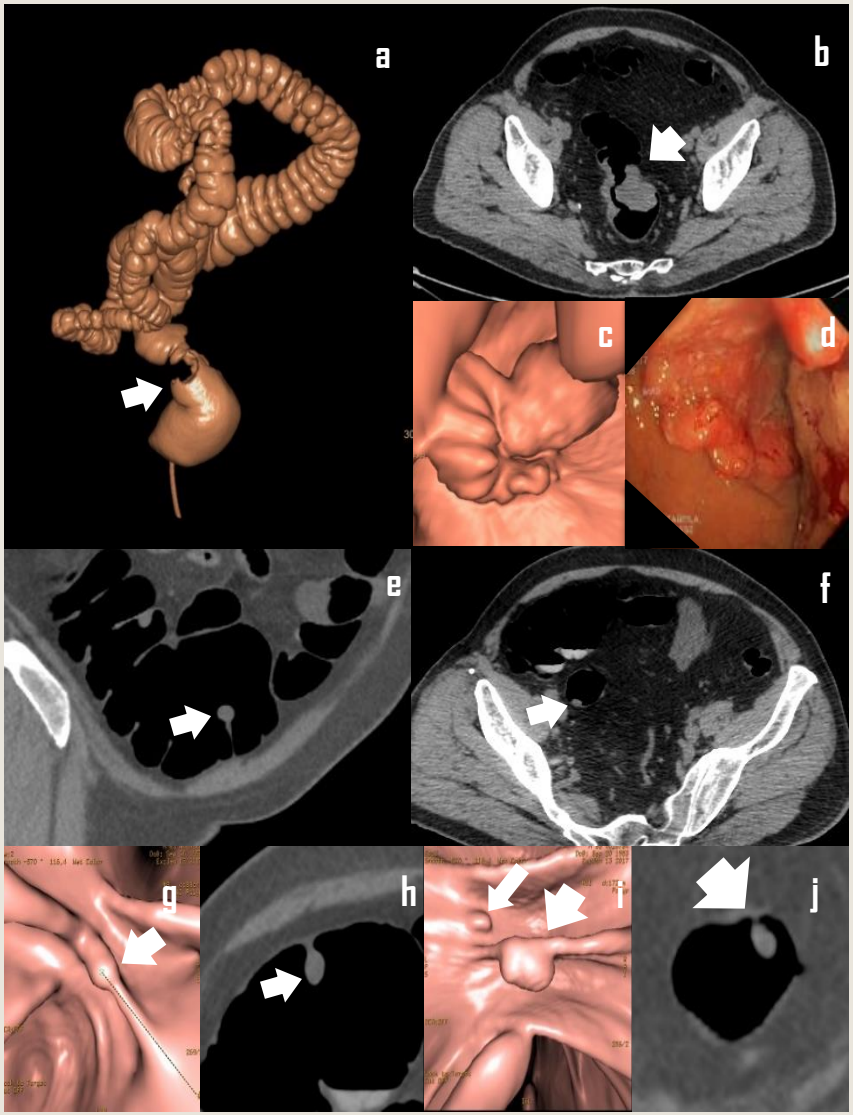

CRC and polyps. Stenotic carcinoma in the rectum with incomplete OC. The stenotic lesion is shown in a 3D luminogram (white arrow in (a), axial (b), endoluminal (c) and corresponding OC (d). We can see also marked with white arrows multiple sessile and pediculated polyps located in the sigma and in the left colon (e, f, g, h, i and j). An extended resection of rectosigmoid area was performed to treat CRC and the polyps were treated with Early Endoscopic Polypectomy after surgery. The anatomo-pathological analysis revealed an intestinal adenocarcinoma in the rectum and tubulo-villous adenomas with low grade dysplasia in the polypoid lesions.

CRC, synchronous cancer and polyps. Male patient with a stenotic CRC in the left side of colon (white arrows in images a, b and c), which presents a synchronous cancer in the transverse colon (white arrows in a, e and f), and several polyps in the entire colon (d) and (g). The patient underwent a subtotal colectomy and two adenocarcinomas and 22 polyps with high and low grade dysplasia were seen.

IMAGING FINDINGS AND PROCEDURE DETAILS

1.- CTC IN THE DIAGNOSIS OF SYNCHRONOUS LESIONS

Preoperative CTC findings in patients with estenosing CRC allow the surgeons to more accurately design the **Surgical Management Plan.**

Studies in the literature, have reported that in patients with stenosing CRC and incomplete OC, the preoperative **information provided by CTC contributed to a change in the surgeon´s initial surgical plan and subsequent management in up to 30% of patients.**

IMAGING FINDINGS AND PROCEDURE DETAILS

2.- CTC IN THE LOCATION OF COLORECTAL CARCINOMA

- **Is another significant issue of preoperative work-up for CRC, specially in the case of laparoscopic approach.**

- At the time of minimally invasive surgery, **the precise segmental location of CRC is critical** for open approach, laparoscopic and computer-assisted surgery.

- **Laparoscopic surgery for CRC is increasing** in clinical practice and in this type of surgery, accurate preoperative localization is essential because the colon cannot be palpated during the procedure and the lesion may not be apparent on the serosal surface adding the risk of removing the wrong colonic segment.

- **Precise Optical Endoscopic localization of the tumor can be challenging** as anatomical landmarks may not be apparent at OC and often the endoscopist only provides the distance from the anal verge and also can be confounded by the presence of a redundant colon or anatomic variants.

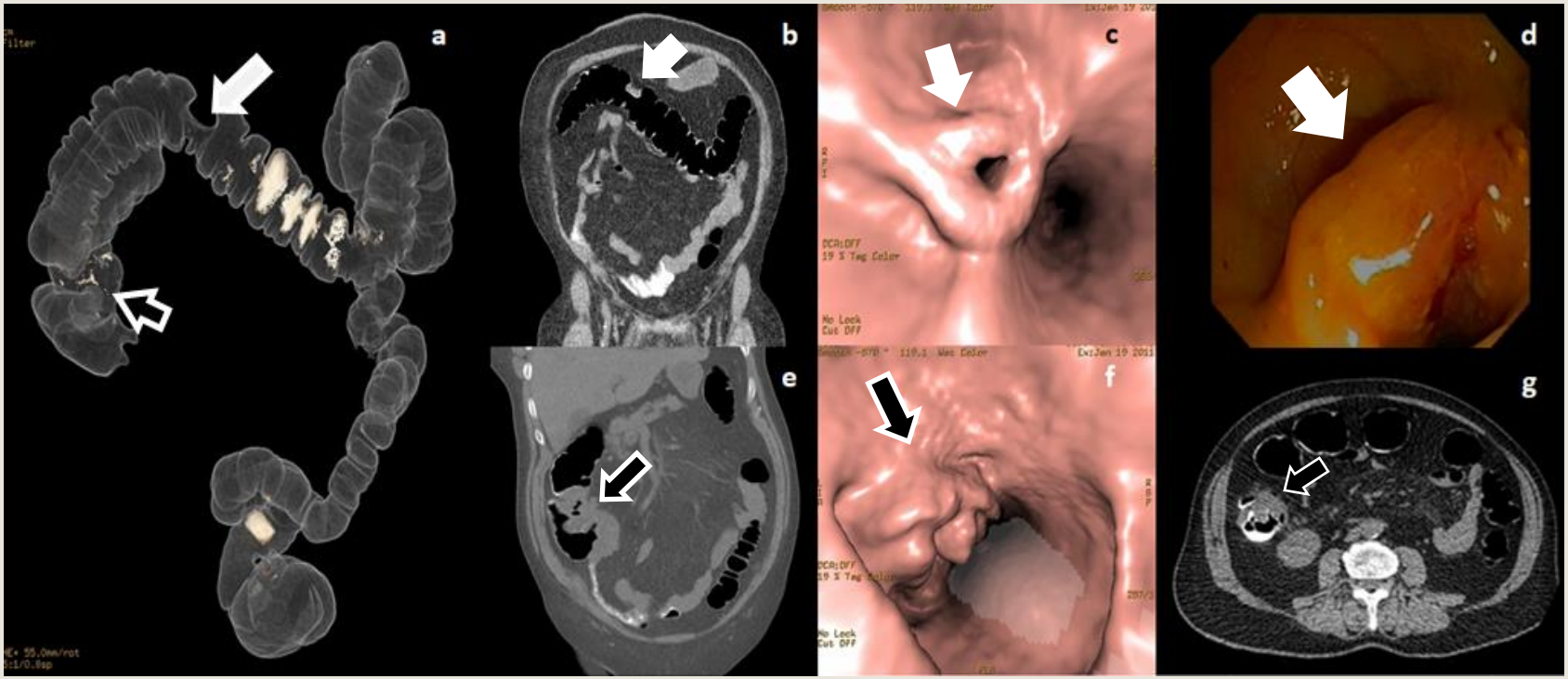

Tumor localization. In the 3D luminogram and coronal slices we can see two neoplasms, one in the transverse colon already known by OC (white arrow in a, b, c y d) and a synchronous tumor in the right colon (black arrow in a, e, f y g). The patient underwent a right colectomy and a transversostomy.

IMAGING FINDINGS AND PROCEDURE DETAILS

2.- CTC IN THE LOCATION OF COLORECTAL CARCINOMA

- Several studies in the literature demonstrated that **Optical Colonoscopy has a suboptimal accuracy in locating the tumor which can be incorrect in 14-21%** of the cases, specially in the rectum-sigma, in the sigmoid and descending colon, since there are no anatomic landmarks that differentiate these segments. It is known that 54 to 73% of these errors are clinically significant since they may modify the surgical plan.
- **The erroneous localization of tumors in the descending colon is clinically relevant** since a left colectomy, a transversotomy or a sigmoidectomy can be performed based on the exact location.
- **CTC clearly demostrates the involved colonic segment,** the **length of tumor extension** and its **relationship with adjacent organs**, vascular structures and peritoneal spaces. Also demonstrate the colon **"quality"**(anatomic characteristics of the colon) with the presence or absence of severe diverticulosis, which can be further resected, or a dolicocolon, data all of them that will influence the type of resection and the time of surgery.
- Previous studies in the literatura have shown that **CTC has a low percentage of location errors (0 to 5,3%)** and have shown that **the surgical plan can be modified based on the location with CTC in 9,2% of the cases.**

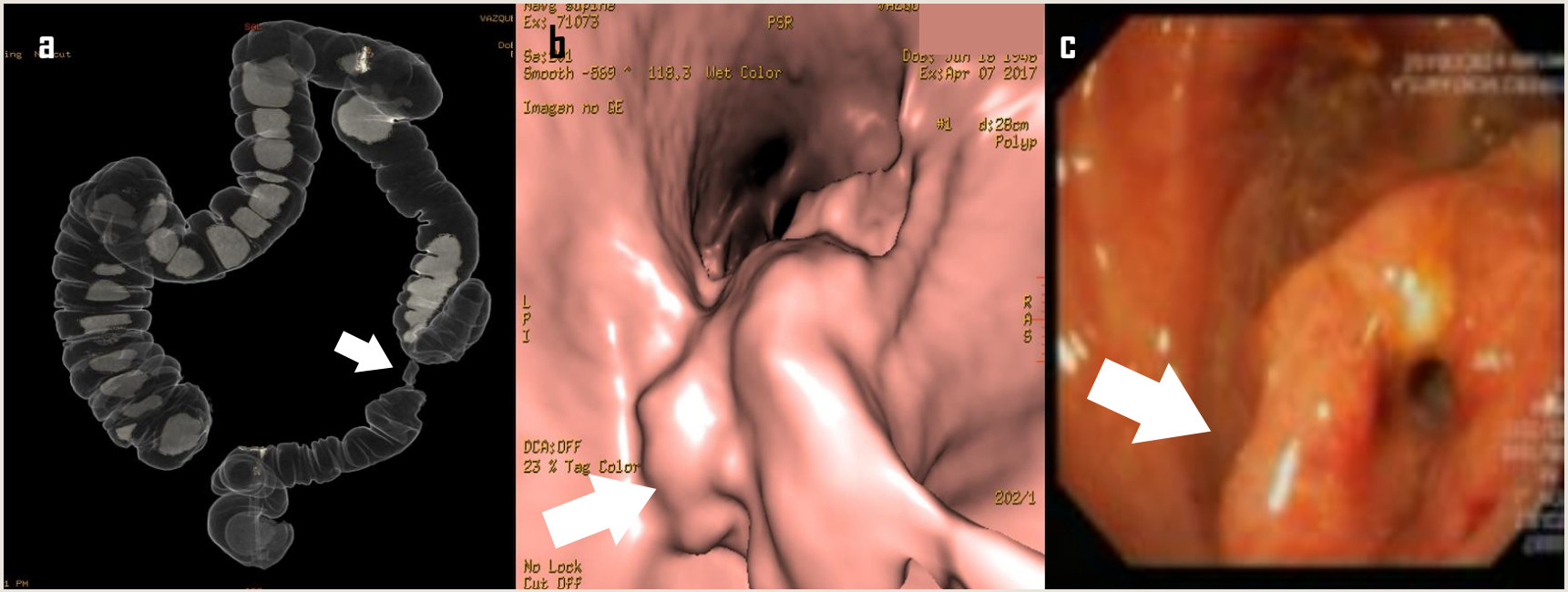

Localization of stenotic CRC. A 69-year-old patient with **a sigmoid cancer diagnosed by OC** (white arrow in c). The **CTC allows to properly locate the lesión in the left colon** (white arrows in a and b), and not in the sigma.

IMAGING FINDINGS AND PROCEDURE DETAILS

2.- CTC IN THE LOCATION OF COLORECTAL CARCINOMA

CTC SHOWS

- The **affected colon segment**
- The **length** of tumor extension
- Its **relationship with adjacent organs**, vascular structures and peritoneal spaces.
- The presence or not of **severe diverticulosis** that can affect the size of the resection
- The presence of a **dolicocolon**

✓ 3D reconstructions allow to determine precise tumor location, show the colon in a similar way to the double contrast barium enema views with rotation in any direction. 2D multiplanar reconstructions (MPR) locate the tumor in relation to surrounding tissues and organs as well as evaluation of tumor features such as size, wall thickening and outer contour.

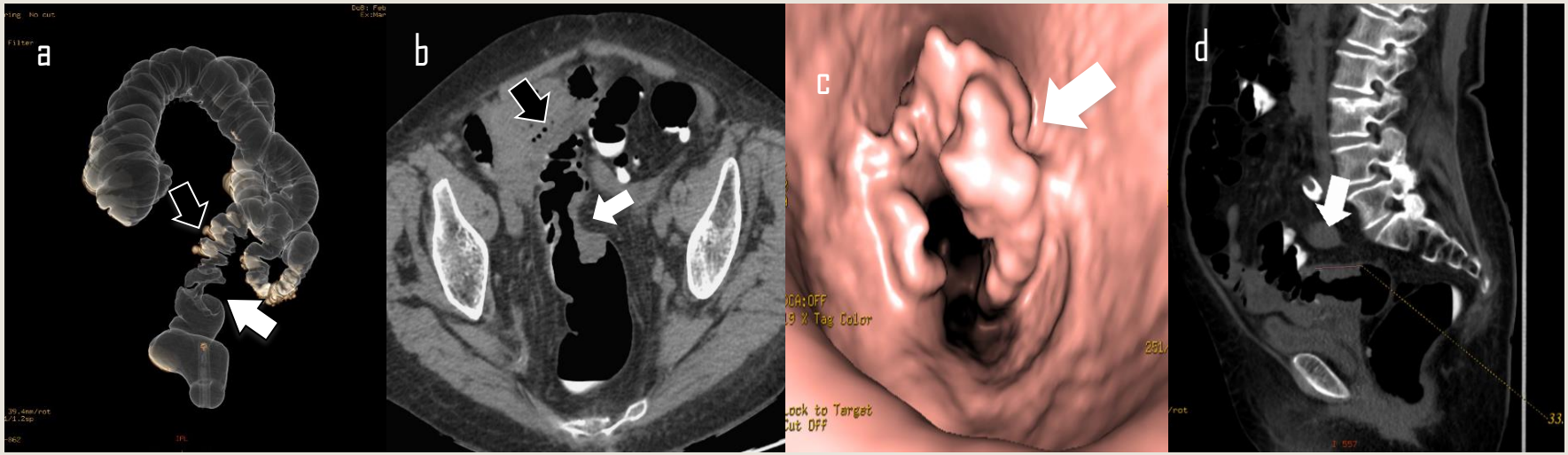

CCR and diverticulosis. CTC performed in a woman diagnosed with rectal cancer by incomplete OC that could not overcome the stenotic area. The endoluminal 3D image reveals the stenotic CRC (arrow in c). CTC allows to locate the neoplasm in the rectosigmoid junction (white arrows in the 3D luminogram, a, and in axial and sagital slices, b and d). The CTC allows to correctly locate the lesion and also evidences a redundant sigma with a severe diverticular involvement (black arrows in a and b). The patient underwent an extended surgery that included the entire diverticular area.

IMAGING FINDINGS AND PROCEDURE DETAILS

2.- CTC IN THE LOCATION OF COLORECTAL CARCINOMA

The safe location of CRC with CTC may influence :

1. Surgical approach: laparotomy or laparoscopic surgery.
2. Location of the incision.
3. Placement of laparoscopic ports.
4. Extent of the resection.
5. Stoma-site planning.

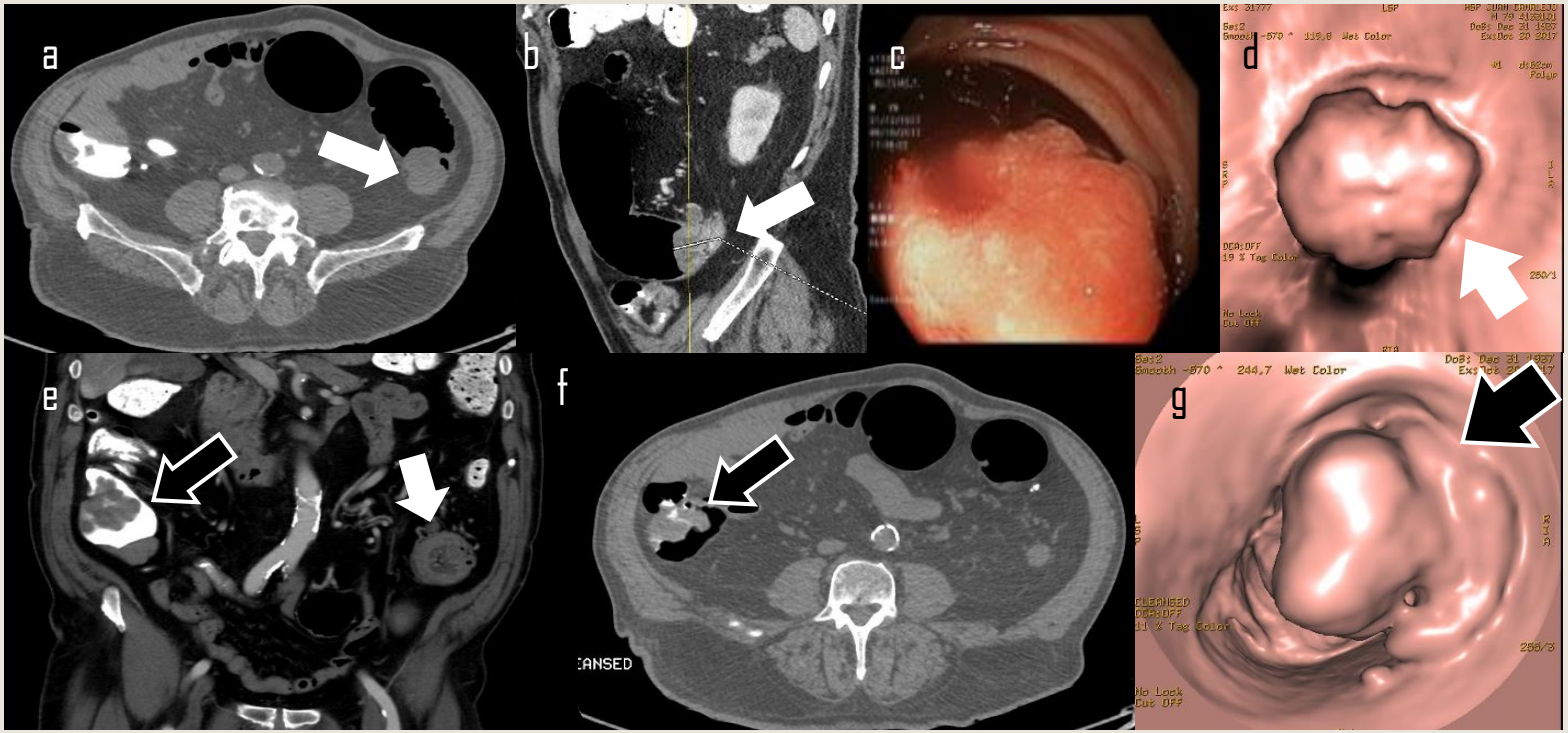

CRC, invagination, synchronous tumor and localization. 80-year-old male with stenotic CRC in sigma by OC (c). CTC locates the CRC in the left colon (white arrows in a, b, d and e) with signs of invagination. We can also see a synchronous tumor in the cecum (black arrow in g) that shows fronds with contrast inside (black arrows in e and f). Based on the CTC-findings, a left and right colectomy by laparoscopic approach was performed. The invaginated tumor was an adenocarcinoma and the cecal tumor was a 4-cm tubulo-villous adenoma with low grade displasia.

IMAGING FINDINGS AND PROCEDURE DETAILS

3.- CTC IN THE STAGING OF COLORECTAL CARCINOMA

- **Treatment of CRC depends on the preoperative assessment of disease extension.**
- **CTC has an importan role in the staging of CRC.** CTC allows to assess **wall thickening, external contours** and **infiltration** of adjacent tissues. **CTC** allows evaluation of the **inner and outer colonic wall** (T stage), **pericolonic lymph nodes** (N) and **distant metastases** (M).
- **2D multiplanar reconstructions (MPR) locate the tumor**, the relationship with adjacent structures, evaluate the size, the wall thickenning and the external contour
- **Most stenosing CRC when diagnosed are in stage T3-T4.**

IMAGING FINDINGS AND PROCEDURE DETAILS

3.- CTC IN THE STAGING OF COLORECTAL CARCINOMA

TNM Staging system proposed for CT-Colonography	
T	**T1-T2**: Lesions confined to the bowel wall.
	T3: Lesions invading subserosal fat[1].
	T4: Lesions invading adjacent organs [2].
	To distinguish T1 / T2 from T3, both colonic wall deformity and lesion outer borders should be considered.

[1] Rounded or nodular margins in perivisceral fat is considered a T3 stage cancer.
[2] Direct invasion or absence of a fat cleavage plane from an adjacent organ is considered T4.
Using these criteria, the overall accuracy of CTC for T staging ranged from 66% to 95%. The CTC, when distending the intestinal loops with air, allows to better evaluate the margins and external walls of the colonic neoplasm. The presence of spiculations within the fat is not universally considered a sign of pericolonic fat invasion, since it may be caused by inflammatory reaction or extramural fibrosis.

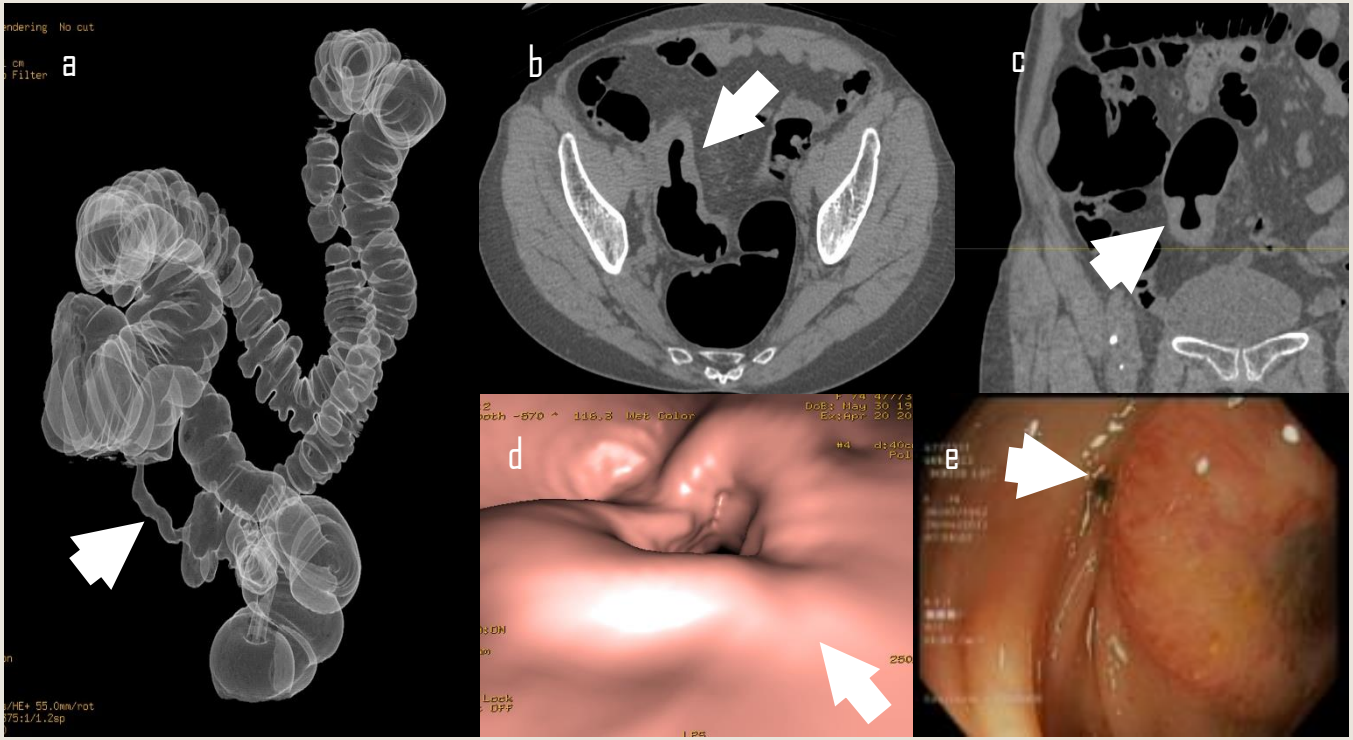

Staging with CTC. CTC in a patient diagnosed with rectum-sigma carcinoma by OC (e), allows to assess the correct location in the sigma (white arrows in a), the lenght of the lesion and the sharp margins, without nodules, with absence of fat infiltration and without loco-regional lymph nodes (a, b, c y d). In CTC it is a T1/T2 and N0. A laparoscopic sigmoidectomy was performed and the staging of the stenotic rectum-sigma adenocarcinoma was T2N0.

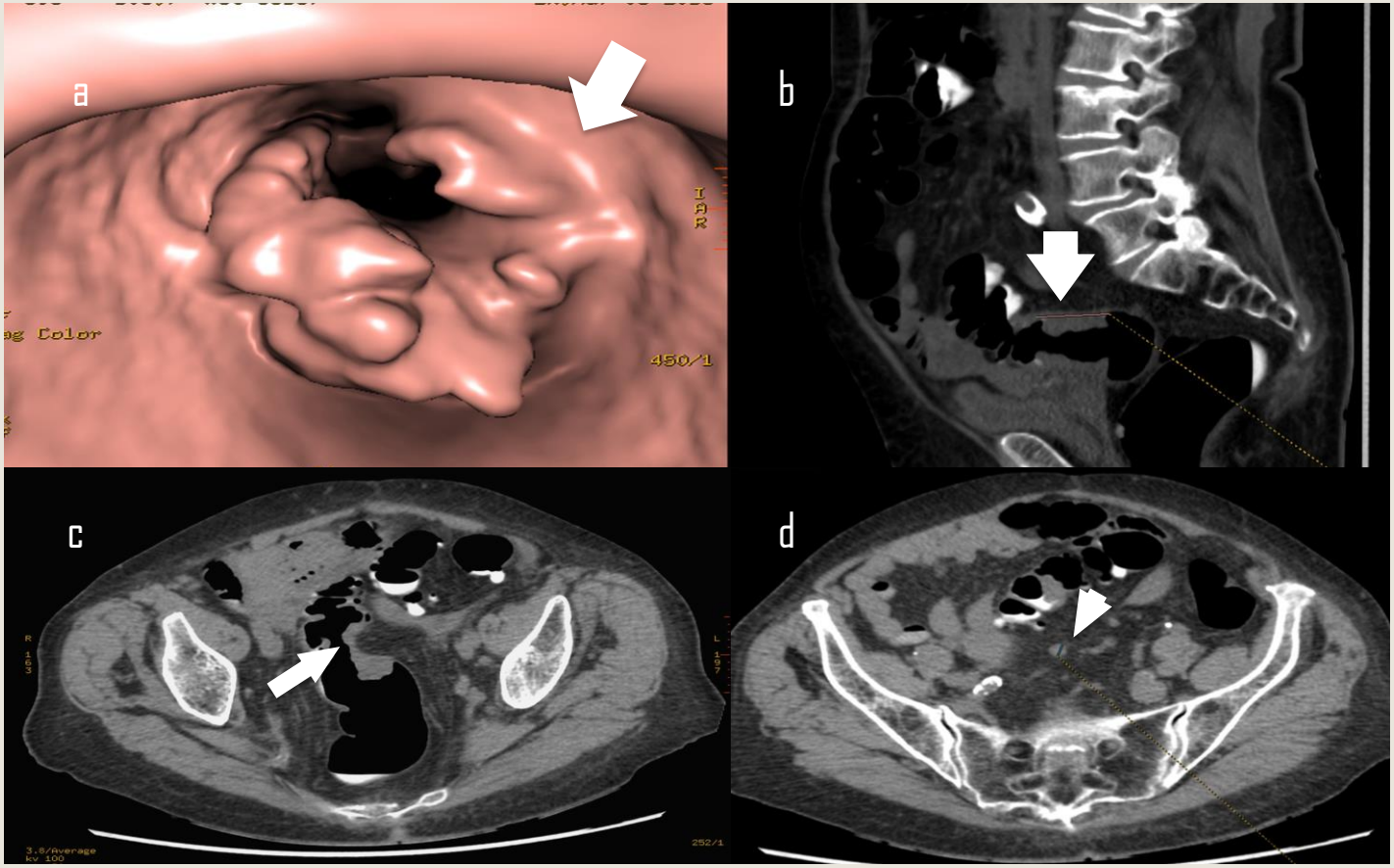

CTC of a rectum-sigma cancer stage T3. The CTC 3D endoluminal image of this woman with a sigmoid cancer diagnosed by OC, shows that the wall involvement is 100% of the luminal circunference (white arrow in a). The CTC 2D sagital and axial reconstructions (b, c y d) shows the lesion with abrupt and infiltrating margins and also we can see some milimetric lymph nodes adjacent to the lesion in number < of 3 (white arrow in d).

IMAGING FINDINGS AND PROCEDURE DETAILS

3.- CTC IN THE STAGING OF COLORECTAL CARCINOMA

TNM Staging system proposed for CT-Colonography	
N	**N1** : "Cluster" of 3 lymph nodes regardless of their size. If there is < of 3 lymph nodes, one of them should measure > 10mm on the long axis[3].
	N2: > 3 lymph nodes, independent of their size[3].

[3] The identification of nodal involvement with CTC is limited. Using these criteria, the overall accuracy of CTC for N staging ranged from 70% to 85%. The accuracy is unsatisfactory, and up to 30% of negative node-negative patients eventually develop distant metastases, possibly as a consequence of lymph-node micrometastases.

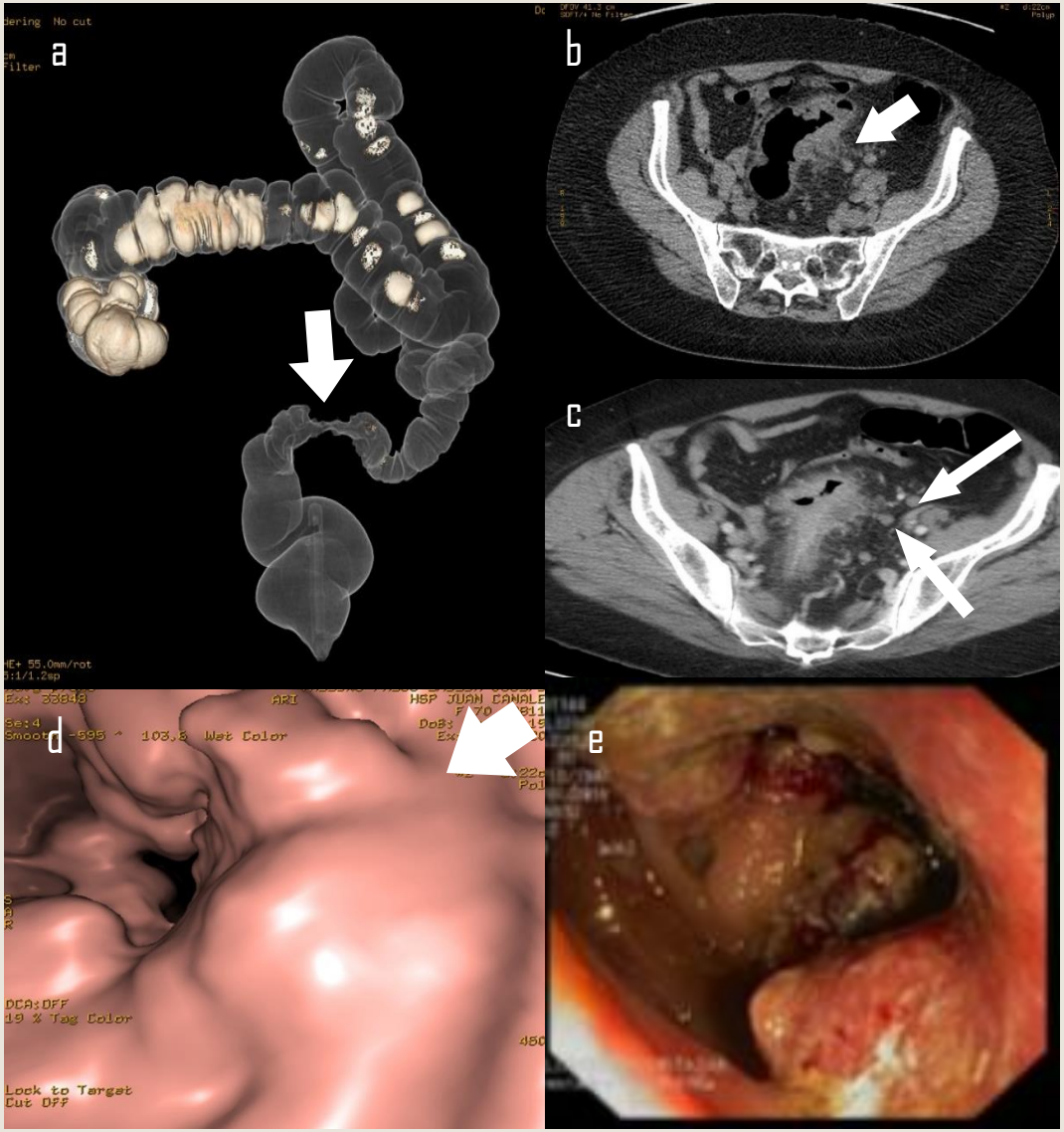

Staging with CTC. Woman with a stenotic tumour in sigma (white arrow in a) diagnosed by OC (e). The 3D endoluminal view allows to see the circumferential involvement of the entire wall and lobulated inner borders (white arrow in d) and in the axial image we can see the nodular margins of the lesion that protrude towards the fat (T3) (white arrow in b). In axial image we can also see (white arrows in c) the presence of a cluster of milimetric lymph nodes in number greater than 3 (N2). T3N2 staging was confirmed by surgery.

IMAGING FINDINGS AND PROCEDURE DETAILS

3.- CTC IN THE STAGING OF COLORECTAL CARCINOMA

TNM Staging system proposed for CT-Colonography	
M	**M0**: No evidence of metastasis
	M1: Liver metastases, retroperitoneal or iliac lymph node enlargement, peritoneal carcinosis.
Distant metastasis: it allows the identification of hepatic, nodal metastasis, the presence of peritoneal carcinomatosis and pulmonary metastasis.	

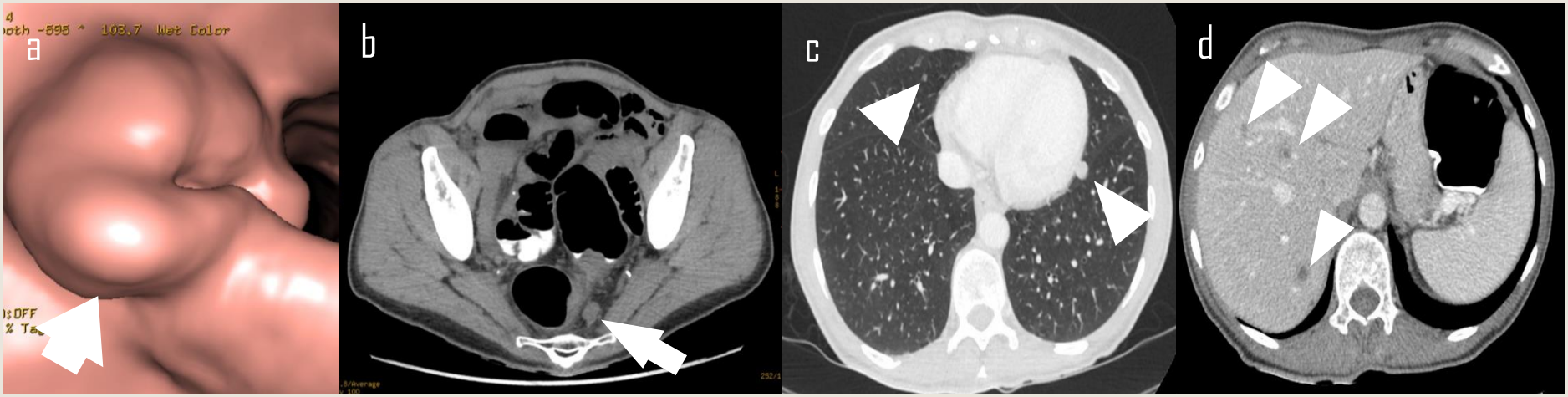

Staging with CTC. Stenotic carcinoma in the sigma. Axial and endoluminal CTC sections allow us to see the circumferential involvement of the lumen (white arrow in a) the nodular margins and the fat infiltration :T3. We can see also more than 3 locoregional lymph nodes, one of them larger than 15mm (white arrow in b) : N2. There are also several hepatic and pulmonary metastases (white arrow points in c y d): M1. Staging with CTC: T3N2M1. The staging was confirmed by surgery.

CONCLUSIONS

- **In patients with CRC, synchronous colorectal cancers and polyps are frequent and** their pre-operative detection is essential for optimal **Surgical Planning and treatment and follow-up.**

- **CT is a safe method for preoperative examination of the proximal colon in patients whith stenotic CRC**, even in those patients with a metallic colonic stent due to an acute obstruction produced by the tumor.

- **CTC in stenotic CRC diagnoses synchronic lesions** in the proximal colon, **accurately locates the tumor** and the synchronic lesions and **stage the carcinoma,** allowing the most adequate **Therapeutical Management.**

- **CTC in stenotic CRC provides the necessary information to perform the best treatment, approach and extension of the resection and facilitates the subsequent management improving the results.**

REFERENCES

1. Lapo Sali,Massimo Falchini, Antonio Taddei, Mario Mascalchi. Role of preoperative CT Colonography in patients with colorectal cancer. World Gastroenterol 2014 April14 2014:3795-3803
2. Natally Horvat, Aradhna Raj, John M. Ward, J.Joshua Smith, Arnold J. Markowitz, Marc J. Gollub. Clinical Value of CT Colonography versus preoperative colonoscopy in the surgical management of occlusive colorectal cancer. AJR2018;210:1-8
3. Cristiano Spada & Jaap Stoker & Onofre Alarcon & Federico Barbaro & Davide Bellini & Michael Bretthauer & Margriet C. De Haan et all. Indications for Computed Tomographic Colonography: European Society of Gastrointestinal Endoscopy (ESGE) and European Society of Gastrointestinal and Abdominal Radiology (ESGAR) Guideline. Eur Radiol (2015) 25:331–345 DOI 10.1007/s00330-014-3435-z
4. Kunwarpal Singh, Aparna Kaur Narula, Chuni Lal Thukral, Neeti Rajan Singhet all. Role of CT Colonography in colonic lesions and its correlation with conventional Colonoscopic finding. Journal of clinical and diagnostic Research 2015, April Vol-9(4):TC14-TC18.
5. Jennifer L. Agnew, Benjamin Abbadessa and Michael Leitman. Strategies to evaluate Synchronous carcinomas of the colon and rectum in patients that present for emergency surgery. International journal of surgical oncology. Vol 2013, Article ID 309439
6. Patel SS, Floyd A, Doorly MG, Ortega AE, Ault GT, Kaiser AM. Current controversies in the management of colon cancer. Curr Probl Surg. 2012 Jul;49(7):398-460
7. Min Sun Kim, Young Jin Park. Detection and treatment of synchronous lesions in colorectal cancer: the clinical implication of perioperative colonoscopy. World J Gastroenterol 2007 Aug 14;13(30):4108-11
8. Marco Cocceta, Carla Migliaccio, Francesco La Mura, Eriberto Farinella et all. Virtual Colonoscopy in stenosing colorectal cancer. Annals of Surgical Innovation and research 2009, 3:11. DOI10.1 186/1750-1164-3-11
9. Alfred King-Yin Lam, Sally Sze-Yan Chan, Melissa Leung. Synchronous colorectal cancer:clinical,pathological and molecular implications. World Journal of Gastroenterology. 2014 June 14;20(22):6815-6820

REFERENCES

10. D.R.McArthur, H.Mehrzad, R.Patel, J.Dadds, A.Pallan et all. CT Colonography for synchronous colorectal lesions in patients with colorectal cancer: initial experience. Eur Radiol (2010) 20 : 621-629.DOI 10.1007/s00330-009-1589-x
11. Jun Yang, Jia-Yuang Peng,Wei Chen. Synchronous colorectal cancers: A review of clinical features, diagnosis, treatment, and prognosis.Dig Surg 2011;28:379-385 DOI: 10.1159/000334073
12. Chien-Chih Yeh,Sheng-Chuan Hsi,Chih-Pin Chuu and Yung-Hsi Kao.Synchronous triple carcinoma of the colon and rectum. World Journal of Surgical Oncology 2013, 11:66
13. Krzysztof Leksowski, Malgorzata Rudzinska, Janusz Rudzinski. Computed tomographic colonography in preoperative evaluation of colorectal tumors: a prospective study.Surg Endosc (2011) 25:2344-2349 DOI 10.1007/s00464-010-1566-0
14. Joo Hee Kim, Won Ho Kim, Tae Il Kim, Nam Kyu Kim,et all. Incomplete Colonoscopy in patients with colorectal cancer : usefulness of CT Colonography according to Tumor location. Yonsei Med J 48 (6):934-941,2007 DOI 10.3349/ymj.2007.48.6.934
15. M.J.Martinez-Sapiña Llanas, S.A.Otero Muinelo, C.Crespo Garcia . Patologia del recto : hallazgos en la colonografia –TC. Radiología 2017.https://doi.org/10.1016/j.rx.2017.10.005
16. Seong Ho Park, Ju Hee Lee, Seung Soo Lee, Jin Cheon Kim, et all. CT Colonography for detection and characterisation of synchronous proximal colonic lesions in patiets with stenosing colorectal cancer.Gut 61 (2012) : 61(12): 1716-1722.
17. JF Huisman, LW Leicher,E de Boer, HL van Wetreenen et all consequences of CT colonography in stenosing colorectal cancer. Int J colorectal Dis Doi : 10.1007/s00384-016-2683-6
18. Alvin C.Silva,MD, Amy K.Hara,MD, Lonathan A.Leighton,MD, Jacques P. Pheppell, MD. CT Colonography with Intravenous Contrast Material: Varied Appearances of Colo- rectal Carcinoma. RadioGraphics 2005; 25:1321–1334