ST. VINCENT'S HEALTHCARE GROUP

Immunotherapy: A Primer for the Abdominal Radiologist

S Clifford, Z Hutchinson & A.C O'Neill

Advancing Healthcare
Since 1834

Learning objectives

ST. VINCENT'S HEALTHCARE GROUP

Teaching points

1. Brief overview of names, subtypes and methods of action of immune-checkpoint inhibitors (ICI)
2. Imaging findings in immune-related responses and immune-related response criteria (irRC)
3. Imaging features of immune-related adverse events (irAEs) with a focus on abdominal findings with some non-abdominal radiologic findings for the general radiologist

Background

ST. VINCENT'S HEALTHCARE GROUP

- The treatment of cancer has dramatically changed in the last few decades with advances in targeted therapies
- Immune-checkpoint inhibitors, since initial approval of ipilimumab in 2011 for malignant melanoma, have demonstrated an increasingly wide spectrum of activity in various malignancies[1, 2]
- Immune-checkpoint inhibitors have a unique method of action using the patient's immune system, producing unusual patterns of response and toxicities, different to conventional chemotherapy[3,4]

Immune-checkpoint inhibitors (ICIs)

ST. VINCENT'S HEALTHCARE GROUP

- Act by inhibiting regulatory steps in the immune system leading to T cell activation and proliferation[5, 6]
- This in turn leads to tumour infiltration and ultimately regression
- Three main types (Summary: Table 1, slide 25)
  - Cytotoxic T-lymphocyte antigen-4 antibodies **(CTLA 4)**
  - Programmed cell death 1 antibody **(PD-1)**
  - Programmed cell death ligand antibody **(PD-L1)**
- *Ipilimumab* (CTLA-4 antibody) was first ICI to be approved in 2011 for melanoma[1, 7]
- Since then several ICIs approved including *nivolumab* (PD-1 inhibitor) and *pembrolizumab* (PD-L1 inhibitor)[8, 9]

Immune-related Response

ST. VINCENT'S HEALTHCARE GROUP

- Different response patterns seen compared to conventional chemotherapy[10, 11]
- Treatment response may be seen long after commencement therapy[3, 4]
- Immune system modulation can be associated with inflammatory reaction causing appearance of new lesions and / or increase in size of pre-existing lesions termed *'pseudoprogression'*
- Proposal for use of a specific response criteria (irRC) instead of RECIST 1.1 to take into account different responses [4] (Table 2, next slide)

RECIST 1.1 versus Immune-related Response Criteria (irRC)

ST. VINCENT'S HEALTHCARE GROUP

	RECIST 1.1	irRC
Measurement	Unidimensional	Bidimensional
New lesion	Progressive disease	Incorporated into tumour burden
Progressive disease	>20% increase in lesion sum	>25% increase in tumour burden from baseline or nadir study in two consecutive studies ≥ 4 week apart
Partial response	>30% decrease in tumour burden	>50% decrease in tumour burden in two consecutive studies ≥ 4 week apart
Complete response	Disappearance of all lesions and no new lesions	Disappearance of all lesions and no new lesions in two consecutive studies ≥ 4 week apart
Stable disease	Neither partial response or progressive disease	Not meeting criteria of partial response or progressive disease

Imaging findings
Immune related response

- **Initial progression followed by response or stability**

74 year old man with metastatic colorectal cancer on nivolumab. Baseline non contrast CT (A) due to renal insufficiency demonstrates a 128 mm hepatic metastasis (straight arrow). Initial follow up CT (B) demonstrates new enlargement of an upper abdominal lymph node from 9 mm to 18 mm (curved arrows). This was followed by gradual response and NCCT two years later shows decrease in hepatic metastasis (straight arrow), which measures 60 mm and is partially calcified (C)

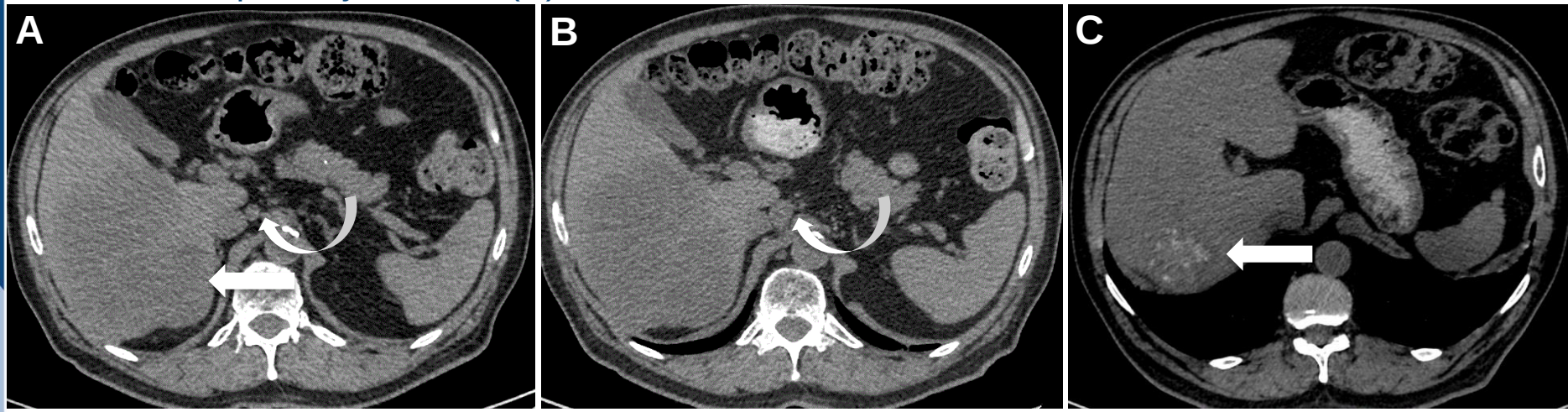

Imaging findings
Immune related response

- **Prolonged stable disease followed by response**

63 year old woman with metastatic colon cancer treated with ipilimumab and nivolumab. Baseline contrast enhanced CT (A, B) demonstrates partially calcified nodal metastases (straight arrows) and a hepatic metastasis (curved arrow) that were stable for 14 months.

Follow up CECT at 18 months (C, D) demonstrates a decrease in size consistent with a partial response of the nodal and hepatic metastases

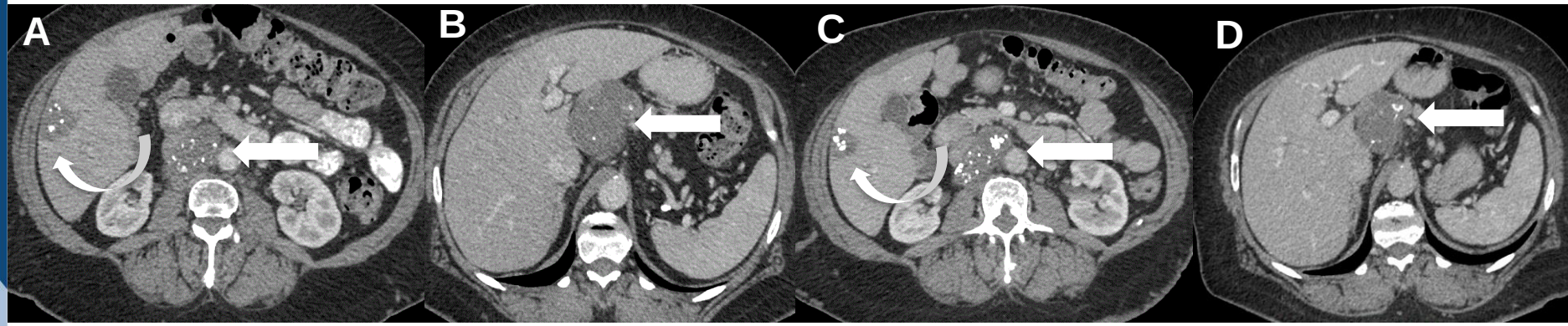

Imaging findings
Immune related response

- **Long period of stability**

51 year old woman with metastatic colon cancer treated with ipilimumab and nivolumab. Contrast enhanced CT at baseline demonstrates a low density aortocaval lymph node (A), which is stable on follow up CT two years later (C).

An anterior abdominal wall metastasis (B) is also stable in size on follow up CT two years later (D)

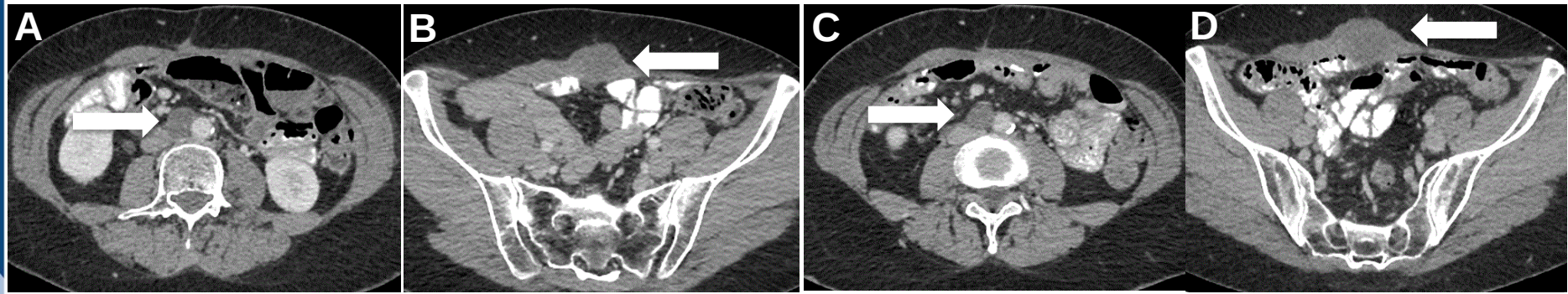

Imaging findings
Immune related response

- **No new lesions and decrease in disease by 12 weeks**

22 year old man with metastatic melanoma treated with ipilimumab and nivolumab with a partial response at 3 months and complete response after that.

Baseline CECT demonstrates splenomegaly and multiple splenic metastases (A) and lytic metastases in the sacrum and left ilium (straight arrows) (B).

Follow up CECT demonstrates resolution of the splenomegaly and splenic metastases (C). There was interval sclerosis of the osseous metastases (straight arrows) (D)

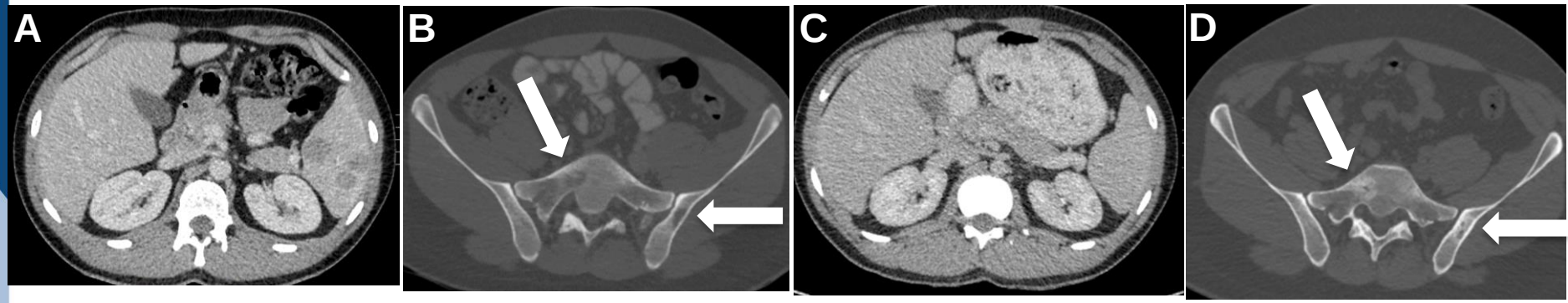

Imaging findings
Immune related adverse events (irAEs)

ST. VINCENT'S HEALTHCARE GROUP

- **Abdominal findings**
  - Colitis – two distinct imaging appearances
  - Hepatitis
  - Pancreatitis
  - Sarcoid-like lymphadenopathy (more commonly thoracic but can be abdominal)
  - Adrenalitis
  - Pneumonitis (may be visible in lung bases)
  - Retroperitoneal stranding
  - Myositis
- Non abdominal findings
  - Pneumonitis
  - Hypophysitis
  - Thyroid disorders

Imaging findings irAE Colitis

- Most commonly reported irAE
- Two different CT appearances described[12-14]
- Type 1
  - Fluid filled colon, mesenteric vessel engorgement, mild diffuse or segmental bowel wall thickening
- Type 2
  - Segmental colitis associated with diverticulosis (SCAD)
  - Segmental wall thickening with pericolonic fat stranding in pre-existing segment of diverticulosis

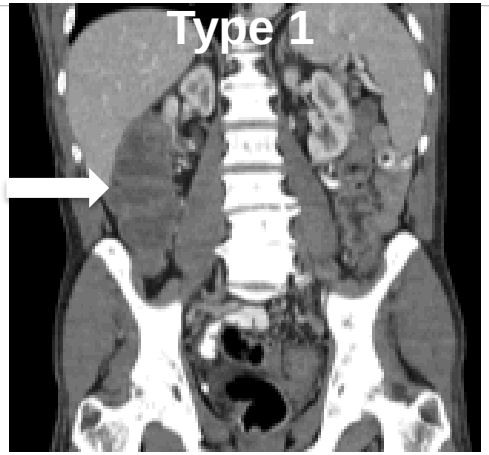

Imaging findings irAE Colitis

ST. VINCENT'S HEALTHCARE GROUP

50 year old man with metastatic melanoma treated with ipilimumab. The patient's first follow up contrast enhanced CT at 12 weeks (coronal image) demonstrates fluid filled colon consistent with type 1 colitis

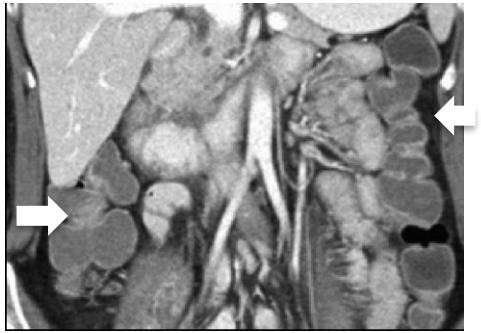

Treatment

Type 1 colitis – high dose steroids

Type 2 colitis / SCAD – steroids and antibiotics

60 year old woman with non small cell lung cancer treated with pembrolizumab. Axial CECT demonstrates pericolonic stranding with bowel wall thickening in a segment of diverticulosis consistent with type 2 colitis (SCAD)

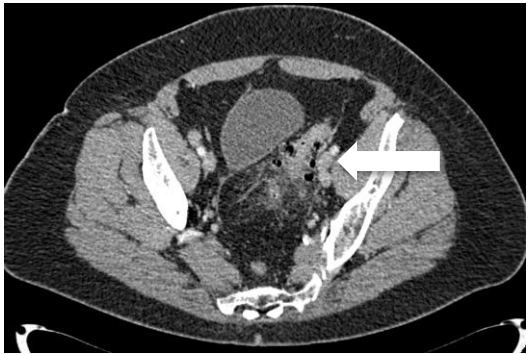

Imaging findings irAE Hepatitis

ST. VINCENT'S HEALTHCARE GROUP

- Usually occurs 6-14 weeks after starting immunotherapy[6,15]
- Histologically hepatocyte injury with acute hepatitis pattern or bile duct injury
- Imaging findings can be subtle and include
  - Mild hepatomegaly
  - Periportal and gallbladder oedema
  - Diffusely hypoattenuating or heterogeneous parenchymal enhancement
  - Periportal lymphadenopathy

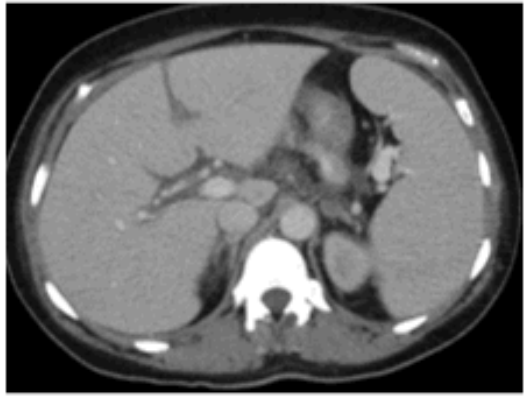

Imaging findings irAE Hepatitis

85 year old man with metastatic melanoma on pembrolizumab. The patient presented after 4 months of treatment with newly deranged liver function tests.

Axial contrast enhanced CT of liver at baseline (A) and segment 5 liver metastasis (B). Follow up CECT after 4 months pembrolizumab of liver (C) and segment 5 liver metastasis (D).

There is new mild hepatomegaly, new heterogeneous appearance of the liver making assessment of the segment 5 metastasis difficult. New small right sided pleural effusion also present

Imaging findings irAE Pancreatitis

ST. VINCENT'S HEALTHCARE GROUP

- Immune related pancreatitis[6,10]
  - Can occur with or without typical symptoms
  - May be elevation of amylase and lipase
  - Imaging findings include an enlarged pancreas with a "sausage" appearance of autoimmune pancreatitis (Figure A)
  - May demonstrate peripancreatic stranding
  - Can demonstrate increased FDG uptake on PET/CT (Figure B)

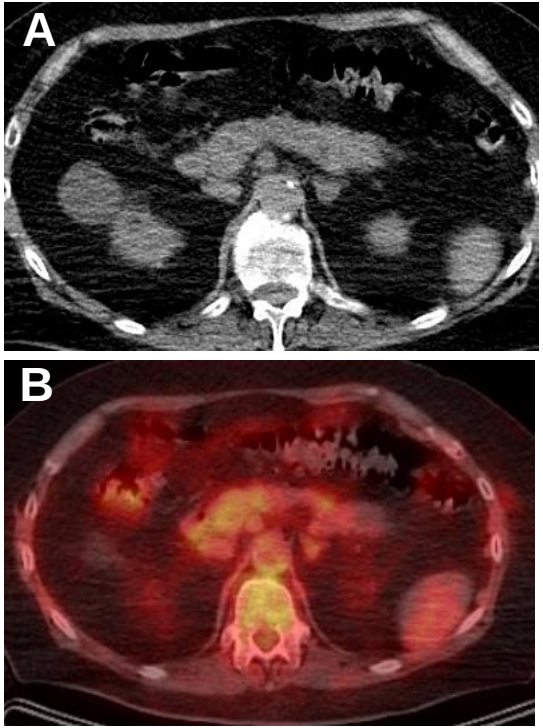

Images courtesy of Dr Sree Harsha Tirumani, DFCI

Imaging findings irAE
Sarcoid like lymphadenopathy

- Bilateral hilar and mediastinal lymphadenopathy has been reported in up to 5% of patients on immune-checkpoint inhibitors [6,12,16]
- Similar changes of new lymphadenopathy can be seen in the abdomen
- These can be difficult to distinguish from new metastatic lymphadenopathy but the absence of concurrent infection and response at other sites of metastatic disease can support the diagnosis[12]

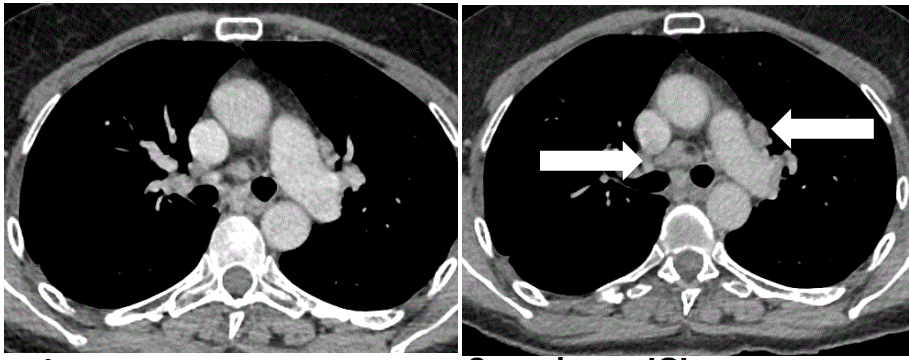

Prior to treatment **8 weeks on ICI**

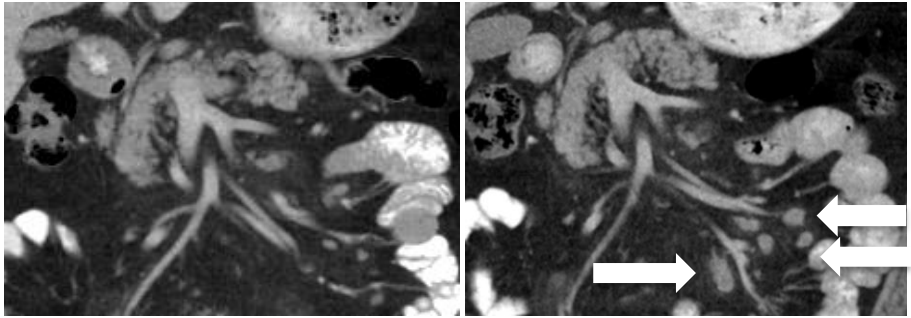

Prior to treatment **12 weeks on ICI**

Imaging findings irAE
Sarcoid reaction

64 year old man with metastatic colon cancer on ipilimumab and nivolumab.

Baseline contrast enhanced CT demonstrate an ill-defined mesenteric mass (A) and no thoracic lymphadenopathy (B).

Follow up CECT after 3 months demonstrates a decrease in the size of the mesenteric mass, which is better defined (C) and interval development of mediastinal lymphadenopathy (D)

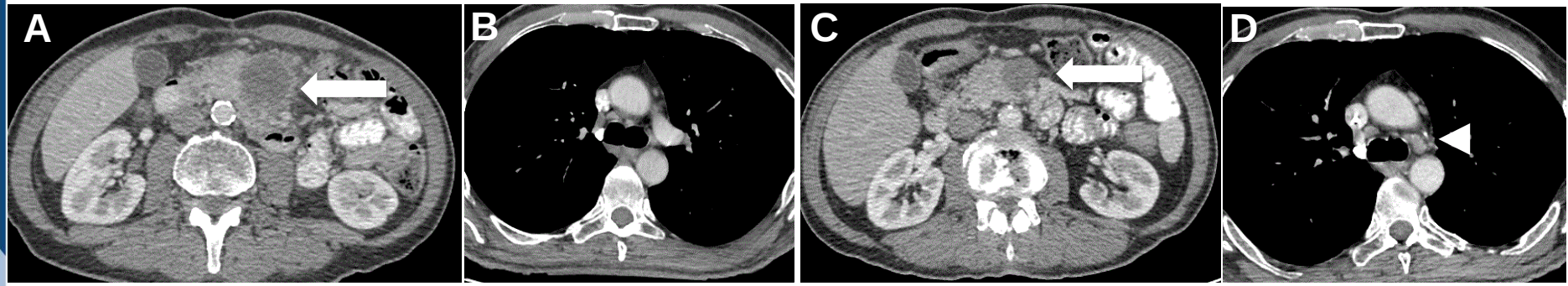

Imaging findings irAE Adrenalitis

ST. VINCENT'S HEALTHCARE GROUP

- Adrenalitis is relatively rare irAE; can be primary or secondary[17-19]
- Imaging appearances
  - New smooth bilateral adrenal enlargement
  - Can demonstrate increased uptake on PET/CT
- More commonly secondary adrenalitis as a consequence of ipilimumab immune-related hypophysitis
  - Imaging appearances of hypophysitis include enlargement of the pituitary and pituitary stalk with homogeneous or heterogeneous contrast enhancement
- Primary adrenalitis reported secondary to ipilimumab + nivolumab
- Primary and secondary both present with hyponatremia
- If secondary to immune related hypophysitis there can be decreased anterior pituitary hormones, most commonly TSH

Imaging findings irAE Adrenalitis

ST. VINCENT'S HEALTHCARE GROUP

70 year old woman with metastatic melanoma on ipilimumab and nivolumab.

Baseline CECT demonstrated normal adrenals (C) and coronal MRI demonstrates normal pituitary prior to treatment (A).

After 8 weeks the patient became unwell and presented with hyponatremia, low TSH, low LH and low FSH

MRI demonstrates new enlargement of the pituitary (B) consistent with immune related hypophysitis and simultaneous smooth bilateral adrenal thickening (D) consistent with secondary adrenalitis

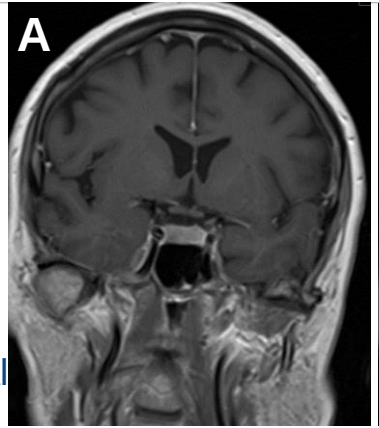

Prior to treatment

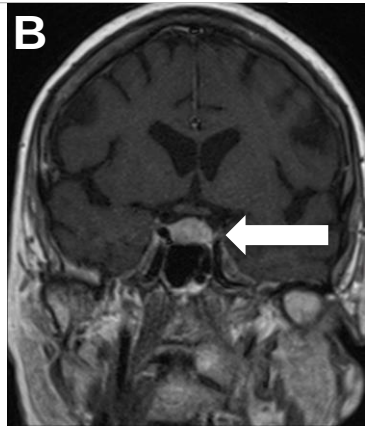

After 8 weeks on ICI

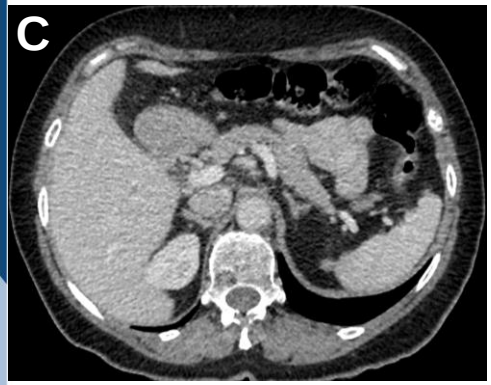

Baseline pre treatment

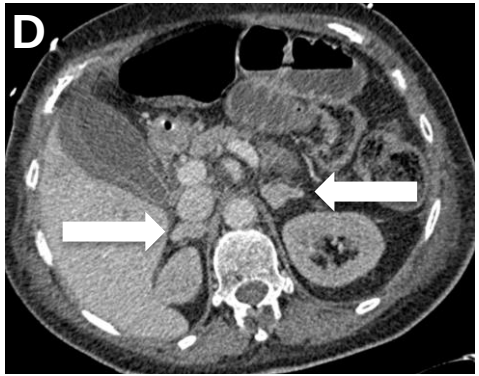

After 8 weeks on ipi/nivo

12 weeks later, off treatment

Imaging findings irAE Pneumonitis

ST. VINCENT'S HEALTHCARE GROUP

- A potentially life threatening complication
- Incidence is approximately 5%
- Several patterns described[20 - 22]
  - Cryptogenic organising pneumonia pattern with new bilateral consolidative or ground glass opacities in a subpleural or peribronchial pattern
  - NSIP pattern with bilateral basal ground glass and reticular opacities with traction bronchiectasis and subpleural sparing
  - ARDS pattern with patchy ground glass opacities and consolidation in the dependent lung
  - Hypersensitivity pneumonia pattern with centrilobular nodules and mosaic attenuation from air trapping with upper lobe predominant distribution

Imaging findings irAE Pneumonitis

ST. VINCENT'S HEALTHCARE GROUP

65 year old man with history of rheumatoid arthritis and metastatic melanoma (MIP PET/CT; D). Metastatic disease is most marked in the right lower limb but he also had hepatic and pulmonary metastases. Urinary catheter in situ (arrowed).

Chest CT show changes of rheumatoid interstitial lung disease - longstanding UIP pattern of fibrosis in the lung bases (A). The patient developed new dyspnoea 7 weeks after starting ipilimumab and nivolumab. Chest CT (B, C) demonstrates new subpleural ground glass opacities consistent with cryptogenic organising pattern of pneumonitis.

Immunotherapy was held and the patient treated with corticosteroids. Nivolumab was restarted but the patient developed toxic epidermal necrosis and died 6 weeks after restarting immunotherapy

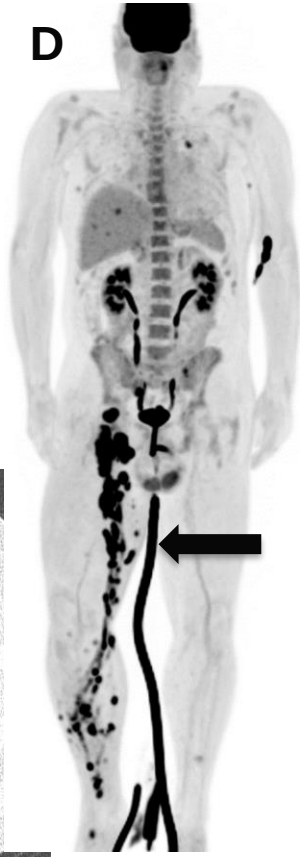

Imaging findings irAE
Thyroid disorders

ST. VINCENT'S HEALTHCARE GROUP

- Thyroid disorders from immune checkpoint inhibitors can present as[23, 24]
  - hypothyroidism
  - painless thyroiditis
  - hyperthyroidism
  - thyroid eye disease
- On imaging thyroiditis can present as diffuse enlargement of the thyroid with diffuse FDG uptake on PET/CT or can appear as in this case described[10]

62 year old man with metastatic colorectal cancer with stable disease on long-term ipilimumab and nivolumab.

Axial CECT show normal hyperdense thyroid on baseline imaging prior to treatment (A) and a small hypodense thyroid on axial CECT 2 years later consistent with immune-related hypothyroidism (B)

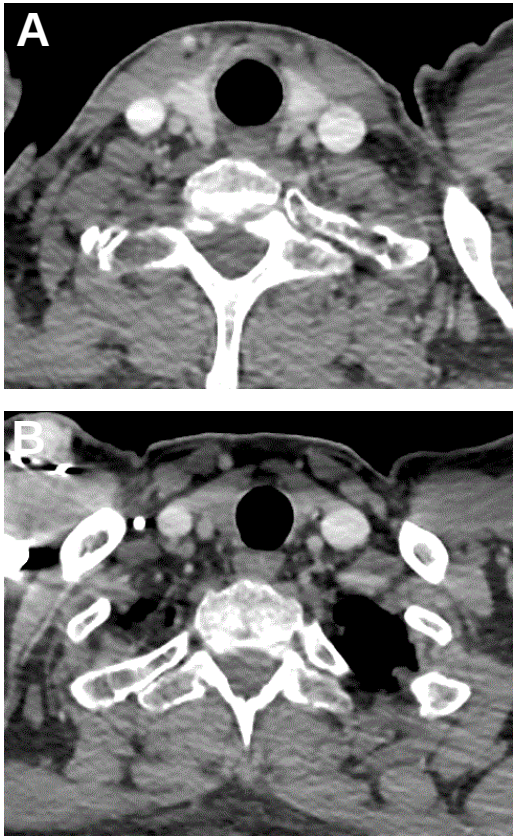

Conclusion

ST. VINCENT'S HEALTHCARE GROUP

- Immune-checkpoint inhibitors (ICIs) are being increasingly used in the treatment of multiple solid and haematologic malignancies
- It is important that the radiologist recognises novel immune-related patterns of response that should not be mistaken progression of disease
- It is also vital that immune-related adverse events are recognised and reported by the radiologist to allow for prompt and appropriate management

Table 1: Immune checkpoint inhibitors

Name	Ipilimumab	Nivolumab	Pembrolizumab	Atezolizumab	Durvalumab
Subtype	CTLA-4 antibody	Anti-PD-1 inhibitor	Anti-PD-L1 inhibitor	Anti-PD-L1 inhibitor	Anti-PD-L1 inhibitor
Malignancies approved (FDA)	Unresectable melanoma Stage III melanoma	Advanced RCC Urothelial cancer* NSCLC Unresectable/ metastatic melanoma Hodgkin's lymphoma Head and neck squamous cell	Urothelial cancer* Met NSCLC Initial treatment unresectable/ metastatic melanoma mCRC Hodgkin's lymphoma Head and neck SCC	Urothelial cancer*	Urothelial cancer*
Administration	IV infusion every 3 weeks with **total of 4 doses**	IV infusion every 2 weeks	IV infusion every 3 weeks	IV infusion every 2 weeks	IV infusion every 2 weeks

*Locally advanced / metastatic urothelial cancer during / after platinum chemotherapy

References:

ST. VINCENT'S HEALTHCARE GROUP

1. Hodi FS, O'Day SJ, McDermott DF, Weber RW, Sosman JA, Haanen JB, et al. Improved survival with ipilimumab in patients with metastatic melanoma. N Engl J Med. 2010;363(8):711-23.
2. Barbee MS, Ogunniyi A, Horvat TZ, Dang TO. Current status and future directions of the immune checkpoint inhibitors ipilimumab, pembrolizumab, and nivolumab in oncology. Ann Pharmacother. 2015;49(8):907-37.
3. Wolchok JD, Hoos A, O'Day S, Weber JS, Hamid O, Lebbe C, et al. Guidelines for the evaluation of immune therapy activity in solid tumors: immune-related response criteria. Clin Cancer Res. 2009;15(23):7412-20.
4. Nishino M, Tirumani SH, Ramaiya NH, Hodi FS. Cancer immunotherapy and immune-related response assessment: The role of radiologists in the new arena of cancer treatment. Eur J Radiol. 2015;84(7):1259-68.
5. Pardoll DM. The blockade of immune checkpoints in cancer immunotherapy. Nature reviews Cancer. 2012;12(4):252-64.
6. Braschi-Amirfarzan M, Tirumani SH, Hodi FS, Jr., Nishino M. Immune-Checkpoint Inhibitors in the Era of Precision Medicine: What Radiologists Should Know. Korean J Radiol. 2017;18(1):42-53.
7. Littman DR. Releasing the Brakes on Cancer Immunotherapy. Cell. 2015;162(6):1186-90.
8. Brahmer J, Reckamp KL, Baas P, Crino L, Eberhardt WE, Poddubskaya E, et al. Nivolumab versus Docetaxel in Advanced Squamous-Cell Non-Small-Cell Lung Cancer. N Engl J Med. 2015;373(2):123-35.
9. Reck M, Rodriguez-Abreu D, Robinson AG, Hui R, Csoszi T, Fulop A, et al. Pembrolizumab versus Chemotherapy for PD-L1-Positive Non-Small-Cell Lung Cancer. N Engl J Med. 2016;375(19):1823-33.
10. Kwak JJ, Tirumani SH, Van den Abbeele AD, Koo PJ, Jacene HA. Cancer immunotherapy: imaging assessment of novel treatment response patterns and immune-related adverse events. Radiographics. 2015;35(2):424-37.

References:

ST. VINCENT'S HEALTHCARE GROUP

11. Wang GX, Kurra V, Gainor JF, Sullivan RJ, Flaherty KT, Lee SI, et al. Immune Checkpoint Inhibitor Cancer Therapy: Spectrum of Imaging Findings. Radiographics. 2017;37(7):2132-44.
12. Tirumani SH, Ramaiya NH, Keraliya A, Bailey ND, Ott PA, Hodi FS, et al. Radiographic Profiling of Immune-Related Adverse Events in Advanced Melanoma Patients Treated with Ipilimumab. Cancer immunology research. 2015;3(10):1185-92.
13. Bronstein Y, Ng CS, Hwu P, Hwu WJ. Radiologic manifestations of immune-related adverse events in patients with metastatic melanoma undergoing anti-CTLA-4 antibody therapy. AJR Am J Roentgenol. 2011;197(6):W992-W1000.
14. Kim KW, Ramaiya NH, Krajewski KM, Shinagare AB, Howard SA, Jagannathan JP, et al. Ipilimumab-associated colitis: CT findings. AJR Am J Roentgenol. 2013;200(5):W468-74.
15. Kim KW, Ramaiya NH, Krajewski KM, Jagannathan JP, Tirumani SH, Srivastava A, et al. Ipilimumab associated hepatitis: imaging and clinicopathologic findings. Investigational new drugs. 2013;31(4):1071-7.
16. Eckert A, Schoeffler A, Dalle S, Phan A, Kiakouama L, Thomas L. Anti-CTLA4 monoclonal antibody induced sarcoidosis in a metastatic melanoma patient. Dermatology. 2009;218(1):69-70.
17. Min L, Ibrahim N. Ipilimumab-induced autoimmune adrenalitis. Lancet Diabetes Endocrinol. 2013;1(3):e15.
18. Trainer H, Hulse P, Higham CE, Trainer P, Lorigan P. Hyponatraemia secondary to nivolumab-induced primary adrenal failure. Endocrinol Diabetes Metab Case Rep. 2016;2016.

References

ST. VINCENT'S HEALTHCARE GROUP

19. Bacanovic S, Burger IA, Stolzmann P, Hafner J, Huellner MW. Ipilimumab-Induced Adrenalitis: A Possible Pitfall in 18F-FDG-PET/CT. Clin Nucl Med. 2015;40(11):e518-9.
20. Nishino M, Giobbie-Hurder A, Hatabu H, Ramaiya NH, Hodi FS. Incidence of Programmed Cell Death 1 Inhibitor-Related Pneumonitis in Patients With Advanced Cancer: A Systematic Review and Meta-analysis. JAMA Oncol. 2016;2(12):1607-16.
21. Nishino M, Ramaiya NH, Hatabu H, Hodi FS, Armand PF. PD-1 inhibitor-related pneumonitis in lymphoma patients treated with single-agent pembrolizumab therapy. Br J Haematol. 2018;180(5):752-5.
22. Nishino M, Sholl LM, Hodi FS, Hatabu H, Ramaiya NH. Anti-PD-1-Related Pneumonitis during Cancer Immunotherapy. N Engl J Med. 2015;373(3):288-90.
23. Byun DJ, Wolchok JD, Rosenberg LM, Girotra M. Cancer immunotherapy - immune checkpoint blockade and associated endocrinopathies. Nat Rev Endocrinol. 2017;13(4):195-207.
24. Ntali G, Kassi E, Alevizaki M. Endocrine sequelae of immune checkpoint inhibitors. Hormones (Athens). 2017;16(4):341-50.

Author information

Dr Simon Clifford, Dr Zoe Hutchinson, Dr Ailbhe C. O'Neill

Department of Radiology,
St Vincent's Healthcare Group, Elm Park,
Dublin 4, Ireland

If you have questions or comments email a.o'neill@st-vincents.ie