Technical Tips for Percutaneous Ablation of Challenging Abdominal Tumors

ESGAR 2018
Dublin, Ireland.

Derek K. Hill, MD; Thomas Atwell, MD; Grant Schmit, MD; Patrick Eiken, MD; John Schmitz, MD;
Nick Kurup, MD, Michael Moynagh, FFRRCSI.
Mayo Clinic, Rochester, USA.

MAYO CLINIC

Disclosure Statement

The authors have no financial/commercial disclosures or conflicts of interest to report

MAYO CLINIC

Learning Objectives/Aims

- Summarize key adjunctive imaging and procedural techniques available to assist radiologists when performing percutaneous ablations involving challenging gastrointestinal and genitourinary tumors.

- After reviewing this exhibit the participant should have increased confidence to utilize various adjunctive techniques to aid in performing percutaneous ablations.

Background

- Percutaneous tumor ablation gaining acceptance as a minimally invasive treatment for the management of liver, kidney, prostate and adrenal tumors.
- As the popularity of these procedures increases, so have the recognized challenges of treatment and complications.
- Over recent years, several techniques have been described to improve patient safety and outcomes.
- Tumor locations that were previously considered high-risk, in close proximity to vital structures, are now more accessible and amenable to ablation with satisfactory clinical outcomes.

MAYO CLINIC

Displacement - Fluid

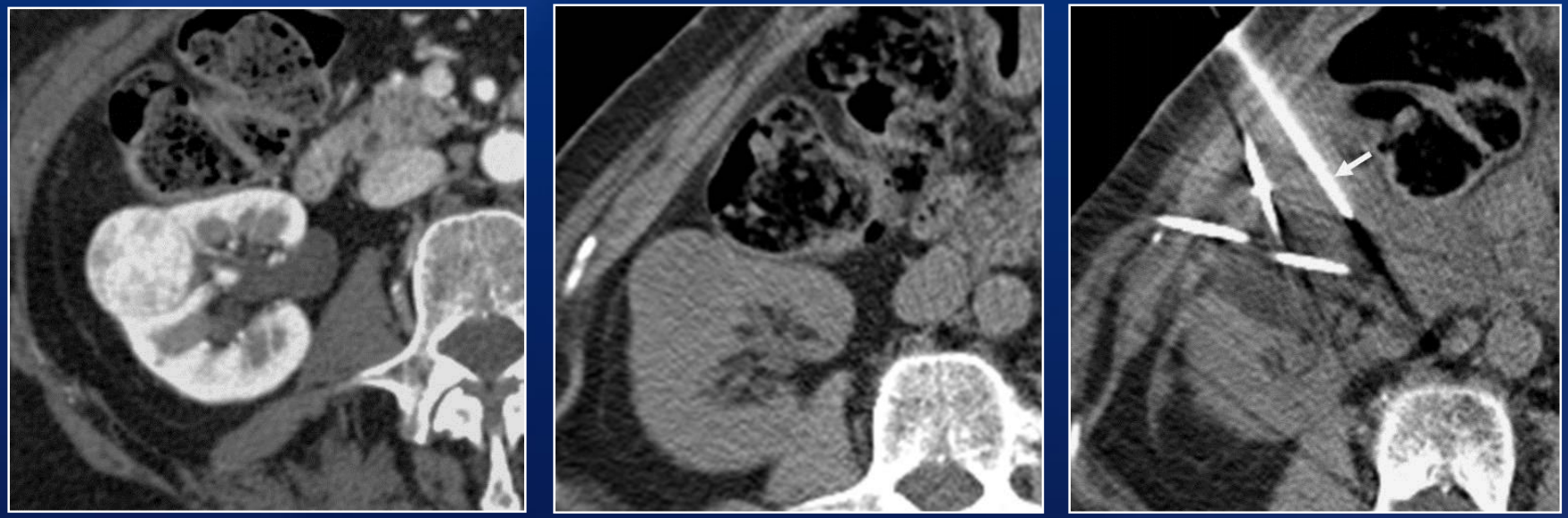

Key adjunctive technique in percutaneous ablation.

Hydro displacement is the single most important technique which can expand the number of tumors that can be safely treated.

Infusion of sterile fluid (saline or D5W) via needle or catheter in order to displace adjacent critical structure and prevent ablation of non target structures. In the case shown, sterile saline has been instilled to displace colon away from target renal tumor allowing safe growth of ice ball during freeze cycles.

MAYO CLINIC

Bodily KR, et al. Hydrodisplacement in the percutaneous cryoablation of 50 renal tumors. AJR 2010;194(3):779-83.

Displacement - Fluid

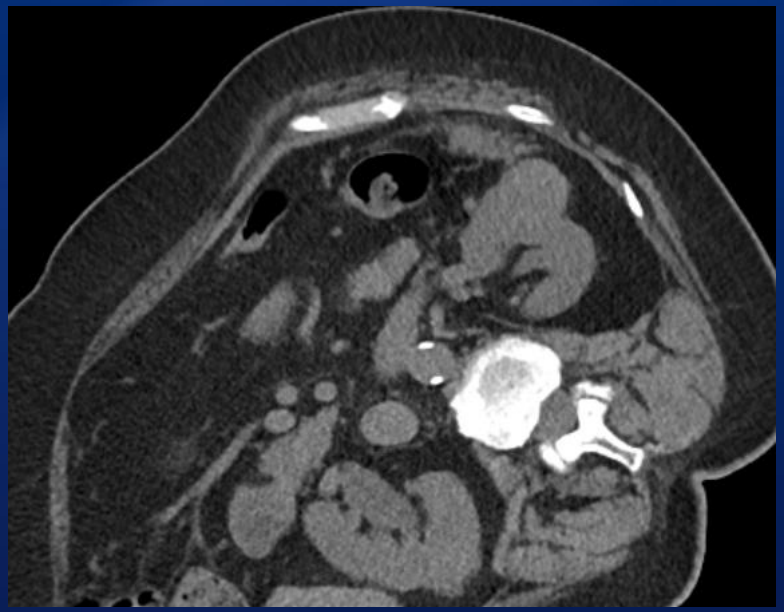

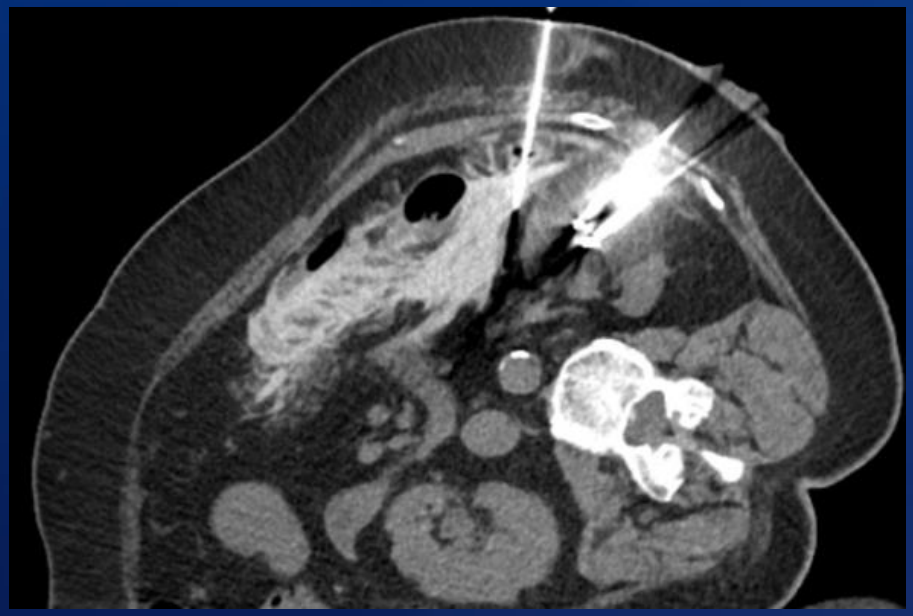

Key adjunctive technique in percutaneous ablation.

Contrast doped hydrodisplacement fluid :
Non-ionic or ionic contrast media can be added to the sterile infusion fluid prior to injection with suggested optimal ratio of 1:50 / 2 %. This can provided added visualization of adjacent bowel or solid organs.

Campbell c, et al. Contrast media-doped hydrodissection during thermal ablation: optimizing contrast media concentration for improved visibility on CT images. AJR 2012;199:677-82.

MAYO CLINIC

Displacement - Fluid

Key adjunctive technique in percutaneous ablation.

Hydrodisplacement fluid is also well visualized during MRI guided ablation procedures. In the case shown, after probe placement into right prostatic tumor (white arrows) , a catheter was placed in the right perirectal space (red arrow) and sterile saline instilled to displace rectum (green arrow) prior to commencing freeze cycles.

MAYO CLINIC

Pre ablation tumor embolization

Baseline

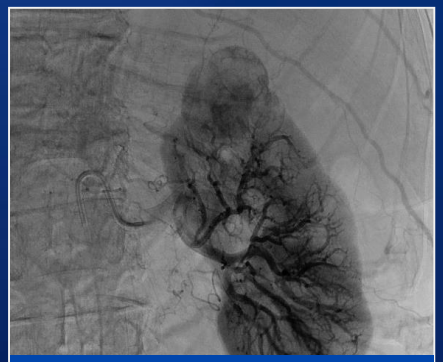

Pre-embolization

Post-embolization

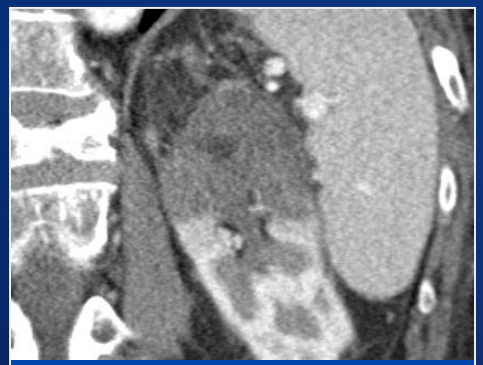

Post-ablation

Decrease post ablation bleeding

- Performance of prophylactic trans-arterial embolization prior to cryoablation of large renal cell carcinomas (>5cm) decreases bleeding complications without a discernible effect on renal function or recurrence rate.
- Balance with underlying renal function, coronary artery disease, need for anticoagulation cessation / bridging.
- Typically performed 24 hours prior to ablation
- Coils preferred over particles, although combination of both is reasonable.

MAYO CLINIC

Miller JM, et al., The role of embolization in reducing the complications of cryoablation in renal cell carcinoma, Clinical Radiology 2014;69(10):1045-9.
Woodrum DA, et al. Role of intraarterial embolization before cryoablation of large renal tumors: a pilot study. JVIR 2010;21(6):930-6.

Retrograde pyeloperfusion

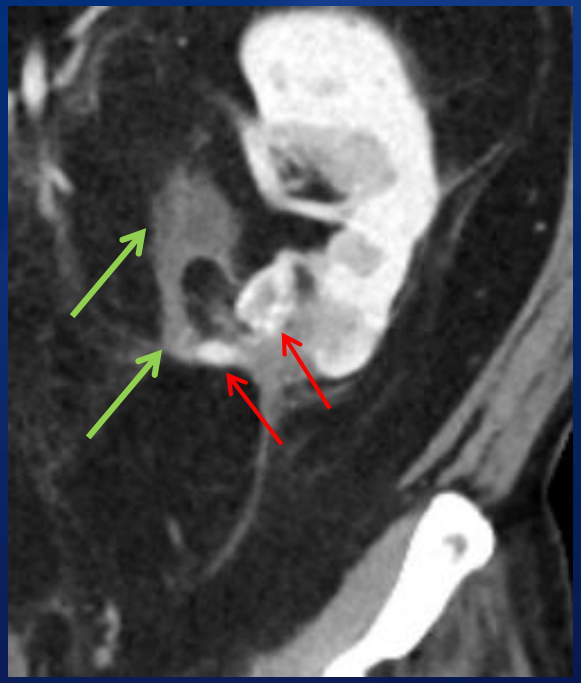

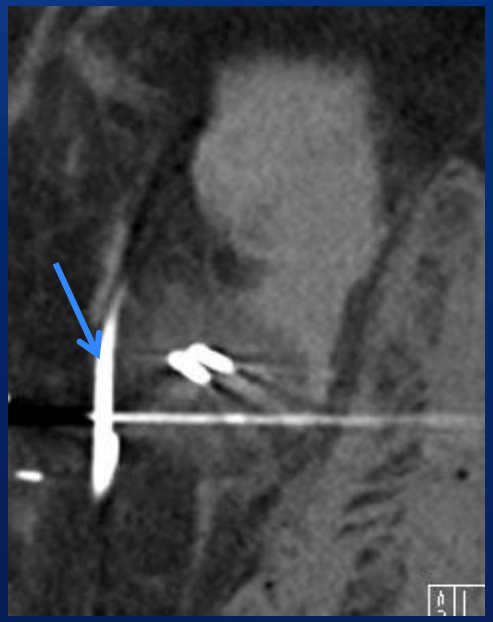

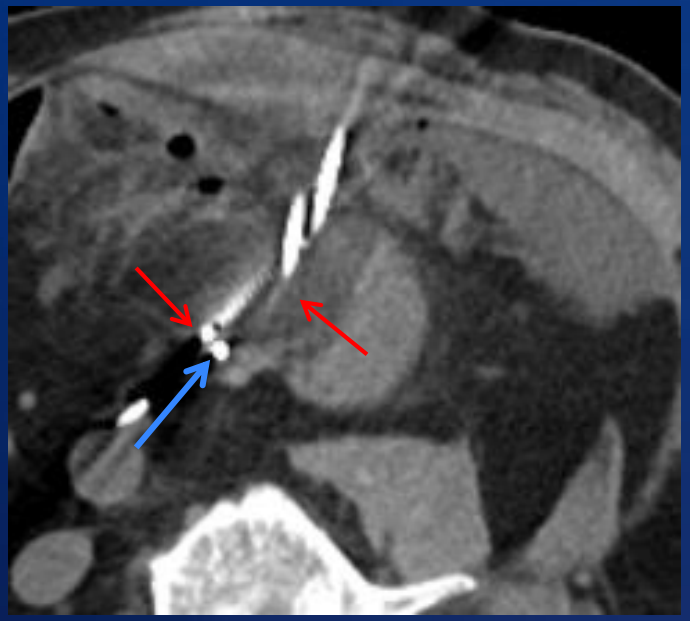

Case example: Localised RCC recurrence post partial nephrectomy, with two RCC nodules (red arrows) adjacent to PUJ and ureter (green arrows). Externalized ureteral stent (blue arrow).

Ureteric / PUJ protection

- Ablation performed close to the ureter may result in ureteral injury and subsequent stricture formation
- Intraprocedural ureteric /PUJ protection - Infuse sterile fluid retrogradely via an externalized ureteral stent.
- Stent internalization for 6 weeks if ice ball encases the ureter.
- Now >900 renal ablations with no ureteral strictures with this technique.

MAYO CLINIC

Cantwell, et al. Protecting the ureter during radiofrequency ablation of renal cancer: a pilot study of retrograde pyeloperfusion with cooled dextrose 5% in water. JVIR 2008;19:1034-40.

Protective urethral warming catheter

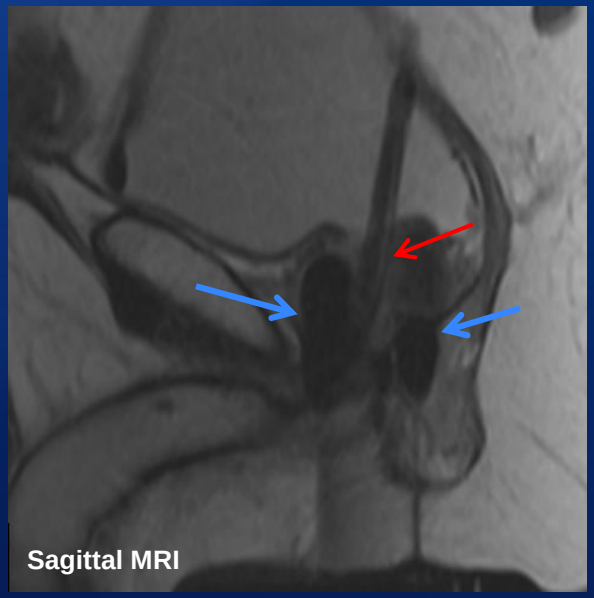

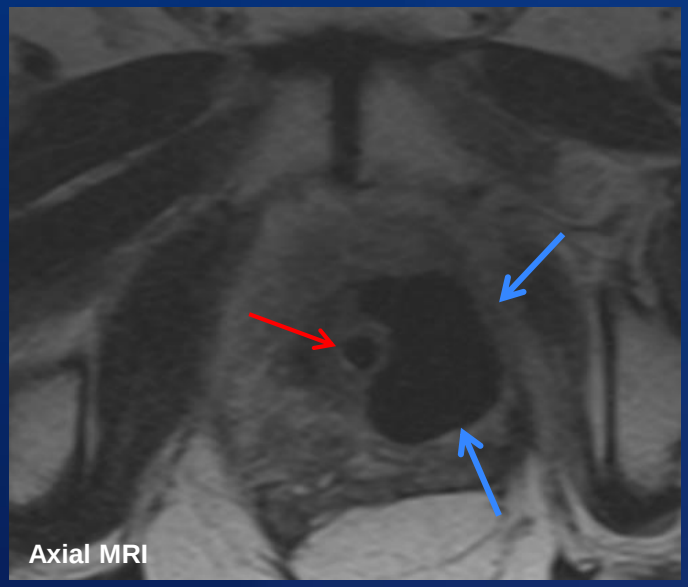

Urethral protection

- During prostate cryoablation a protective warming catheter (red arrows) is placed via the urethra into the bladder prior to commencing freeze cycles.
- Continuous warmed fluid circulates via the closed-loop continuous-flow temperature-controlled urethral catheter during cryoablation to minimize injury of urethral tissue from adjacent ice ball (blue arrows)
- Significantly decreases risk of secondary urethral injury related to epithelial sloughing.

MAYO CLINIC

Favazza CP, et al . An investigation of the effects from a urethral warming system on temperature distributions during cryoablation treatment of the prostate: A phantom study. *Cryobiology*. 2014;69(1):128-133.

Cohen JK, Miller RJ, Shuman BA. Urethral warming catheter for use during cryoablation of the prostate. *Urology*. 1995;45(5):861-864.

Adrenal - Adrenergic blockade

- Ablation of tumors involving the adrenal gland has been associated with profound blood pressure fluctuations including hypertensive crisis.
- Pre-ablation α-blockade can decrease the severity of the hypertensive episode, at the expense of higher need for vasopressors periprocedurally.
- Premedication with alpha-blockade should be considered in most patients.
- Phenoxybenzamine can be titrated 10 days prior to treatment. Doxazosin is an alternative medication that can be used with potential cost savings.

MAYO CLINIC

Fintelmann, et al. Catecholamine Surge during Image-Guided Ablation of Adrenal Gland Metastases: Predictors, Consequences, and Recommendations for Management. JVIR 2016.27:395-402.
Welch BT, et al. A single-institution experience in image-guided thermal ablation of adrenal gland metastases. JVIR 2014.25(4):593-8.

Adrenal – Blood pressure

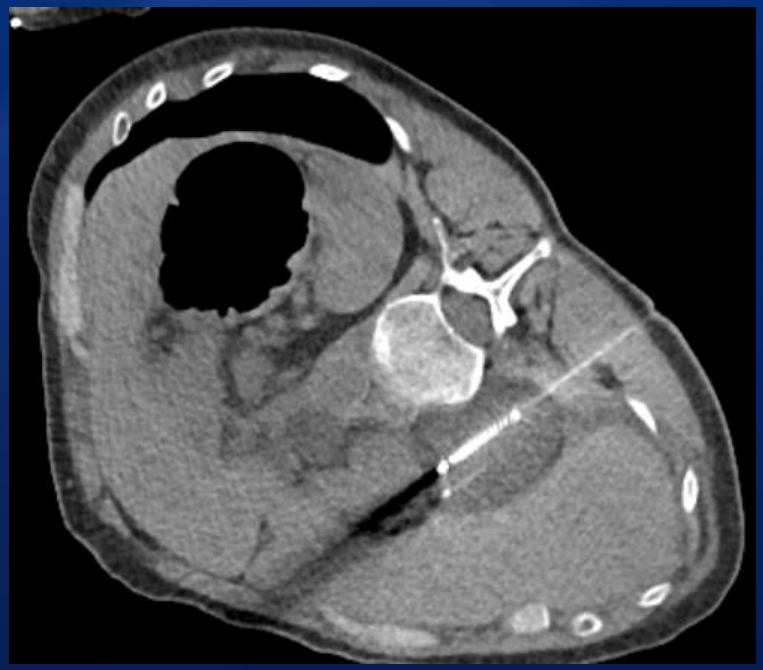

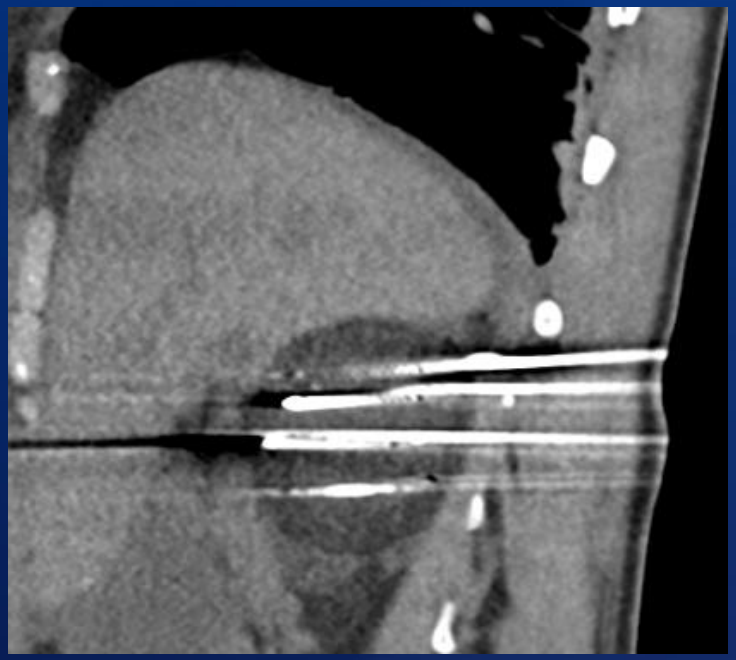

- Intra procedural hemodynamic changes can occur either from direct or indirect ablation of the adrenal gland, particularly during the thawing phase of any freeze cycle.
- Arterial lines are used to preemptively manage any severe hypertensive episode by aggressively monitoring the arterial blood pressure during ablation
- Close interaction with anesthesia colleagues during procedure is essential, as is rapid availability of relevant IV antihypertensive / pressor agents

MAYO CLINIC

Atwell TD, et al Vasc Interv Radiol. 2006 Mar;17(3):573-5..Malignant hypertension during cryoablation of an adrenal gland tumor.
Welch BT, et al. A single-institution experience in image-guided thermal ablation of adrenal gland metastases. JVIR 2014.25(4):593-8.

Displacement – Lever Technique

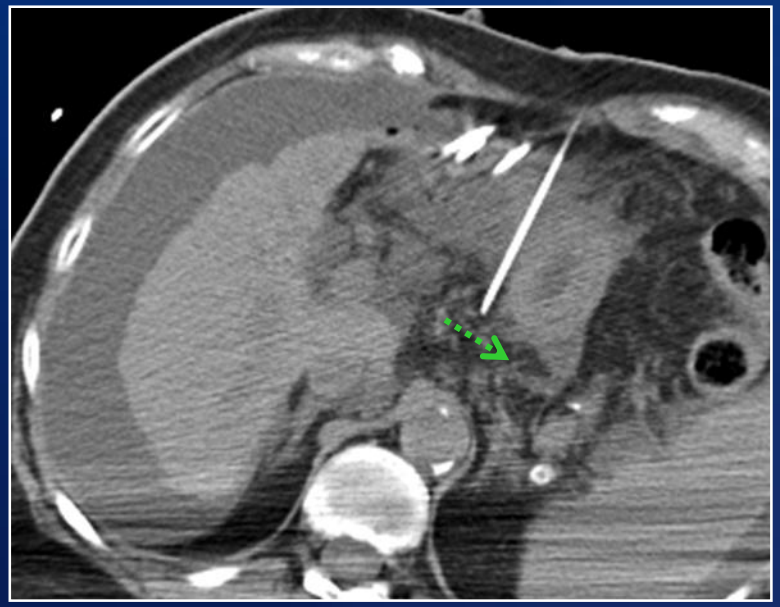

- Stomach can be difficult to displace using standard fluid hydro displacement
- Ablation probe can be used as a lever to displace stomach from liver tumor using site of skin entry as a fulcrum. After gently torqueing the handle medially, the stomach moves laterally, increasing distance from the ablation zone.

MAYO CLINIC

Schmit et al. The “Leverage Technique”: Using Needles to Displace the Stomach during Liver Ablation. JVIR 2016;27(6):1765-1766.

US Fusion

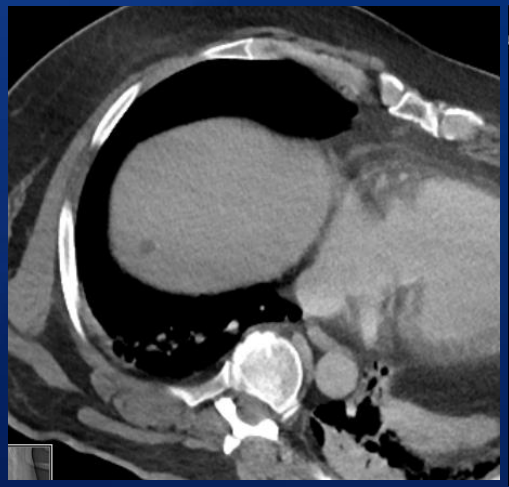

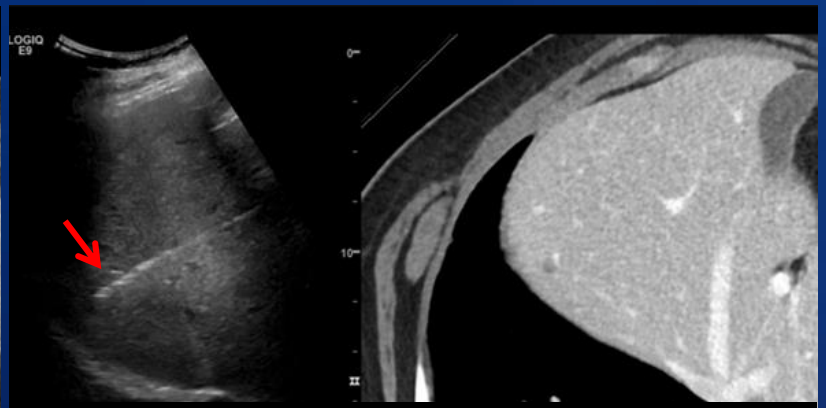

US/CT fused image – showing placement of MW antenna (red arrow) into small CRC liver metastasis

Advantages of Fusion Imaging

- Expansion of ablation cases
- Target tumors with poor US or CT visualization
- Real time imaging and probe placement
- Out of axial plane probe placement
- Treat tumors in difficult locations
- Improved operator confidence
- Improved accuracy of device placement

MAYO CLINIC

Hakime A et al. Percutaneous Thermal Ablation with Ultrasound Guidance. Fusion Imaging Guidance to Improve Conspicuity of Liver Metastasis.. Cardiovasc Intervent Radiol. 2017 May;40(5):721-727

US Fusion Techniques

Treatment of tumors in difficult locations

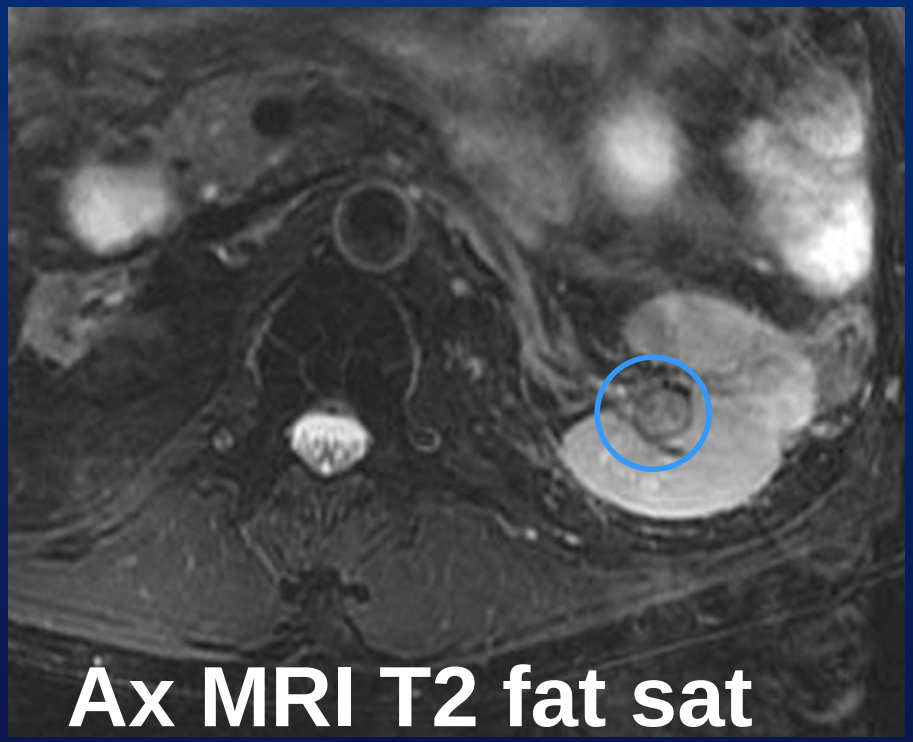

Case example :

Central renal mass ablation—solitary kidney

Preablation Creatinine = 2.9 mg/dL

MAYO CLINIC

US Fusion techniques

Central renal mass ablation—solitary kidney

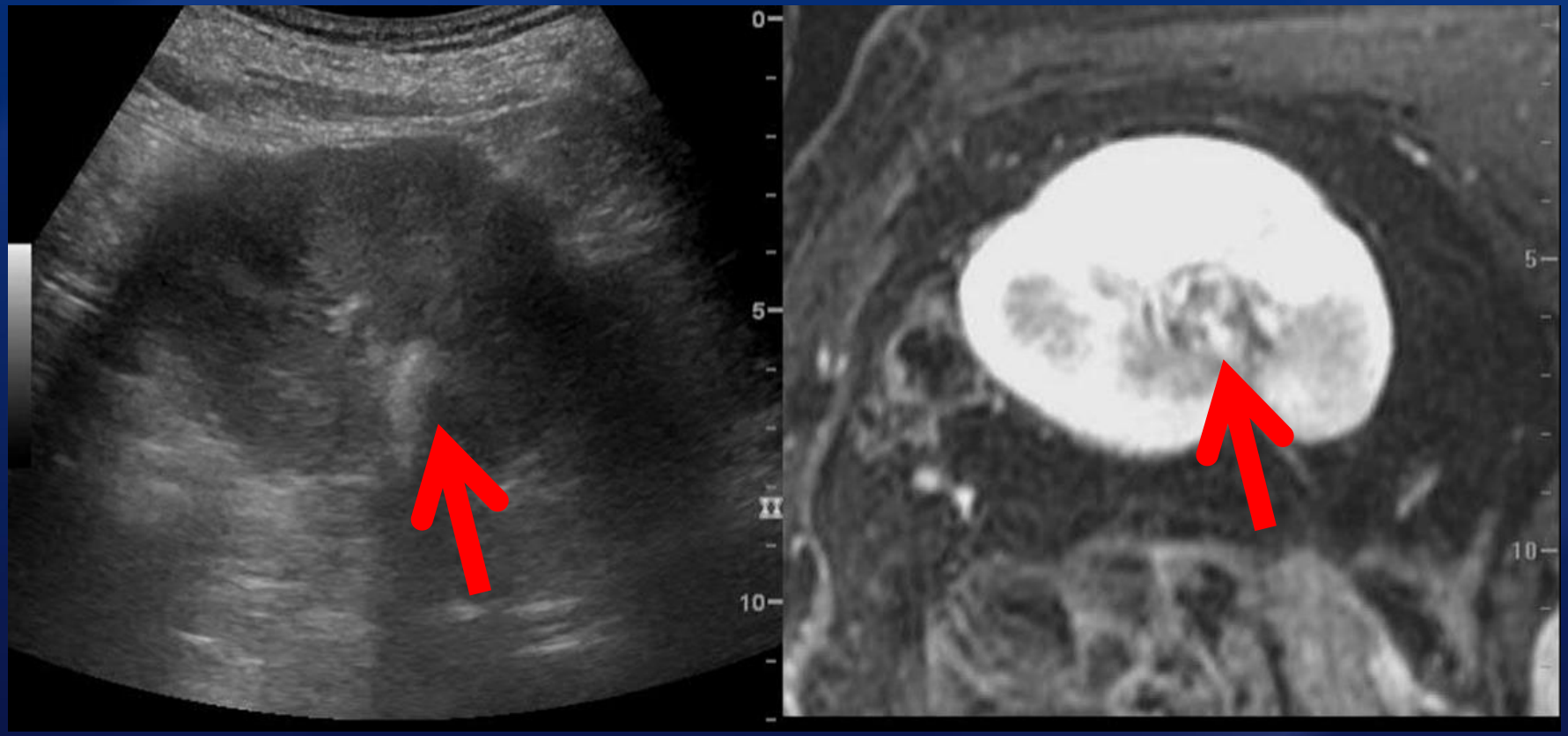

- Confidence increased with US-MRI fusion
- Safe probe placement into mass under US fusion guidance

MAYO CLINIC

US Fusion Techniques

Central renal mass ablation—solitary kidney

Pre ablation CT

Post probe placement

MAYO CLINIC

US Fusion Techniques

Central renal mass ablation—solitary kidney

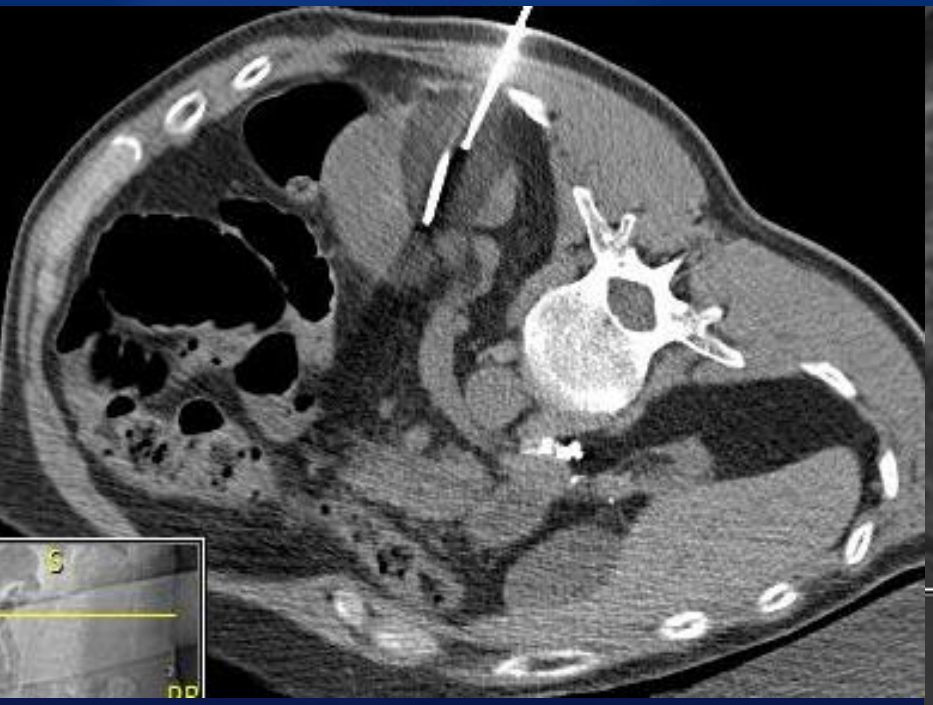

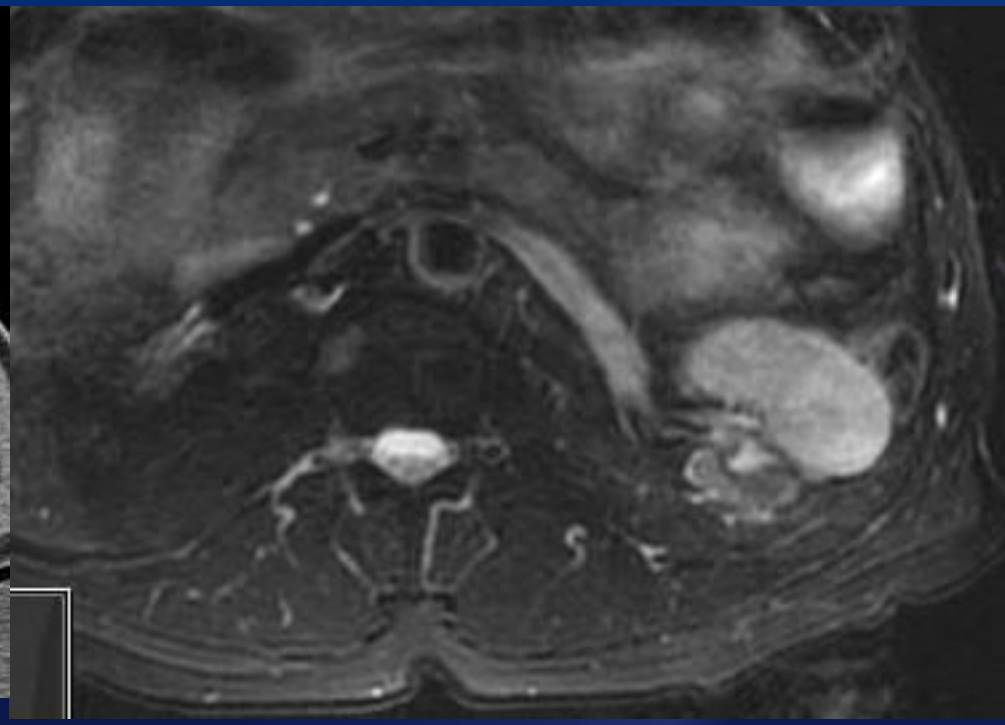

Cryoablation **T2 MRI : local tumor control**

Creatinine = 2.9 → 3.1 mg/dL post ablation

MAYO CLINIC

Contrast-enhanced ultrasound

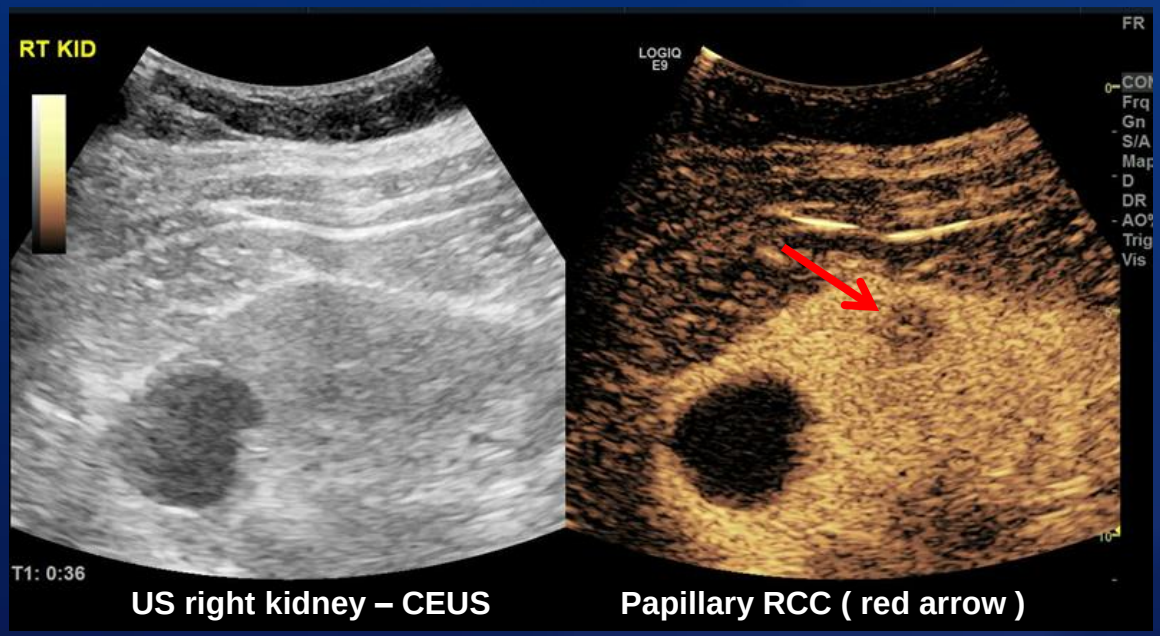

Technique can be performed for lesions that are poorly visualized on conventional US in order to guide ablation probe placement.
Contrast-enhanced ultrasound (CEUS) involves the administration of intravenous contrast agents containing microbubbles of perfluorocarbon or nitrogen gas. The bubbles affect ultrasound backscatter and increase vascular contrast in a similar manner to intravenous contrast agents used in CT and MRI.

MAYO CLINIC

Wilson, et al. Contrast-enhanced ultrasound: what is the evidence and what are the obstacles?. AJR Am J Roentgenol 2009;193 (1): 55-60.

CT – Tube current modulation

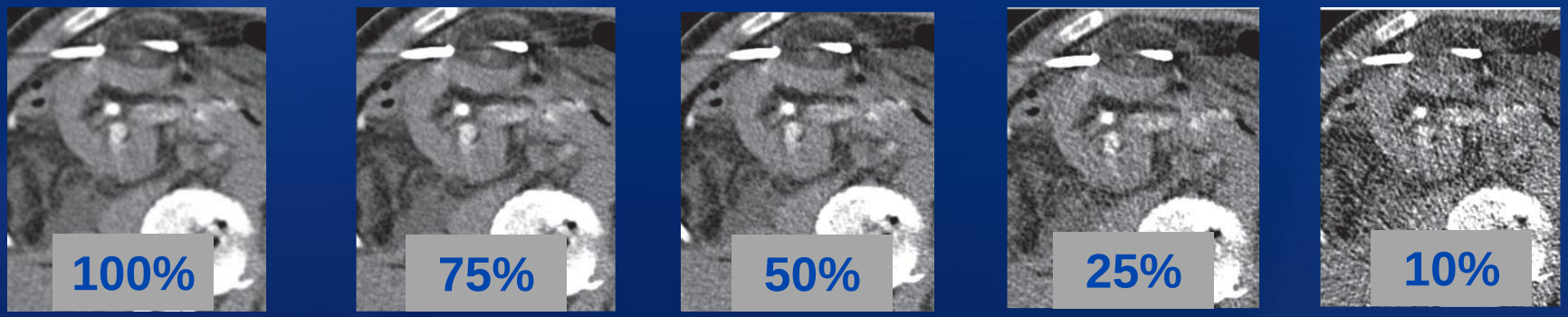

% Dose

- Cryoablation has been associated with considerable radiation exposure during treatment. This needs to be considered as the technique is incorporated into mainstream oncologic treatment algorithms.
- Without compromising the clinical outcome, the smallest radiation dose should be used to guide and monitor ablation.
- It has been shown that reduction of mAs by 25-50% results in image quality sufficient to effectively monitor cryoablation.

MAYO CLINIC

Leng, S. et al. Radiation Dose Reduction for CT-Guided Renal Tumor Cryoablation. AJR. (2011). 196:586-591.

Summary

After reviewing this exhibit, the participant should be able to appreciate important adjunctive techniques related to tumor ablation:

Procedural techniques:

- hydrodisplacement and other mechanical displacement maneuvers
- ureteral stents to protect collecting system
- Urethral warming catheter to minimize urethral injury
- selective embolization to minimize bleeding
- alpha blockade for adrenal ablation

Imaging techniques:

- ultrasound-fusion imaging for lesion localization
- contrast-enhanced ultrasound to identify index lesion(s)
- manual dose reduction during CT monitoring

Selected References

Allaf, et al. Bowel Separation Before Percutaneous Renal Cryoablation. Journal of Urology. August 2008. 180:721.

Atwell, et al. Malignant Hypertension during Cryoablation of an Adrenal Gland Tumor. JVIR 2006. 17:573-575.

Atwell, et al. Complications following 573 Percutaneous RenalRadiofrequency and Cryoablation Procedures. JVIR 2012. 23:48-54.

Bodily, et al. Hydrodisplacement in the percutaneous cryoablation of 50 renal tumors. AJR 2010;194(3):779-83.

Campbell, et al. Contrast media-doped hydrodissection during thermal ablation: optimizing contrast media concentration for improved visibility on CT images. AJR 2012;199:677-82.

Cantwell, et al. Protecting the ureter during radiofrequency ablation of renal cell cancer: a pilot study of retrograde pyeloperfusion with Cooled Detrose 5% in water. JVIR 2008; 19:1034-1040.

Chini, et al. Hypertensive Crisis in a Patient Undergoing Percutaneous Radiofrequency Ablation of an Adrenal Mass Under General Anesthesia. Anesthesia & Analgesia. June 2004. 99:1867-1869.

Fintelmann, et al. Catecholamine Surge during Image-Guided Ablation of Adrenal Gland Metastases: Predictors, Consequences, and Recommendations for Management. JVIR 2016. 27:395-402.

Ginat, et al. Transcatheter Renal Artery Embolization for Management of Renal and Adrenal Tumors. JVIR 2010. 13:75-88.

Ginat, et al. Bowel Displacement for CT-Guided Tumor Radiofrequency Ablation: Techniques and Anatomic Considerations. J of Endourology. August 2009. 23:1259-1264.

Glamore, et al. Mathematical and Ex Vivo Thermal Modeling for Renal Tumor Radiofrequency Ablation with Pyeloperfusion. J of Endourology. June 2015. 29:707-713.

Landman, et al. Renal Hypothermia Achieved by Retrograde Intracavitary Saline Perfusion. J of Endourology. September 2002. 16:445-449.

Leng, et al. Radiation Dose Reduction for CT-Guided Renal Tumor Cryoablation. AJR. (2011). 196:586-591.

Miller, et al. The role of embolization in reducing the complications of cryoablation in renal cell carcinoma, Clinical Radiology (2014).

Park, et al. Using an electrode as a lever to increase the distance between renal cell carcinoma and bowel during CT-guided radiofrequency ablation. Eur Radiology 2008. 18:743-746.

Schmit et al. The “Leverage Technique”: Using Needles to Displace the Stomach during Liver Ablation. JVIR 2016; Vol 27. No 11. 1765-1766.

Schmitz, et al. Renal Microwave Ablation Resulting in Ureteropelvic Junction Stricture Remote from the Ablation Site. JVIR 2017. 1278-1280.

Uppot R, et al. Imaging-guided percutaneous ablation of renal cell carcinoma: a primer of how we do it. AJR. 192 (2009). 1558-1570

Vincent M, et al. Radiation dose during CT-guided percutaneous cryoablation of renal tumors: Effect of a dose reduction protocol. EJR 2015; Vol 84, No 11. 2218-2221.

Welch, et al. A Single-Institution Experience in Image-Guided Thermal Ablation of Adrenal Gland Metastases. JVIR 2014. 25:593-598.

Welch, et al. Percutaneous Image-guided Adrenal Cryoablation: Procedural Considerations and Technical Success. Radiology. January 2011. 258:301-307.

Wilson, et al. Contrast-enhanced ultrasound: what is the evidence and what are the obstacles?. AJR Am J Roentgenol. 2009;193 (1): 55-60.

Winokur, et al. Role of Combined Embolization and Ablation in Management of Renal Masses. Semin Intervent Radiol 2014. 31:82-85.

Woodrum, et al. Role of Intraarterial Embolization before Cryoablation of Large Renal Tumors: A Pilot Study. JVIR 2010. 21:930-936.

Yamakado, et al. Adrenal Radiofrequency Ablation in Swine: Change in Blood Pressure and Histopathologic Analysis. Cardiovasc Intervent Radiol. November 2010.

MAYO CLINIC

Author correspondence

Dr. Michael R. Moynagh, MRCSI, FFRRCSI.
Mayo Clinic
Rochester, MN, USA.
Moynagh.michael@mayo.edu

MAYO CLINIC